



DOI: 10.32768/abc.2024113307-312



Lymphocytic Variant of Triple-Negative Breast Cancer Carcinoma Erysipeloides: A Rare Case of Carcinoma Erysipeloides Following TNBC Mastectomy

Amr Ahmed^a , Maher Monir Akl^{*b} ^aThe Public Health Department, Riyadh First Health Cluster, Ministry of Health, Saudi Arabia^bDepartment of Chemistry, Faculty of Science, Mansoura University, Mansoura, Egypt

ARTICLE INFO

ABSTRACT

Received:

13 April 2024

Revised:

15 June 2024

Accepted:

16 June 2024

Keywords:

Carcinoma erysipeloides, Triple-negative breast cancer (TNBC), Metastatic, Cutaneous, metastases

Background: Carcinoma erysipeloides (CE) is a rare but significant cutaneous manifestation of metastatic breast cancer, often misdiagnosed due to its rarity and nonspecific presentation. This is particularly true in patients with triple-negative breast cancer (TNBC), where the disease may progress undetected by conventional imaging modalities. This paper aims to elucidate the challenges and implications of diagnosing CE in breast cancer survivors, emphasizing the insufficiency of PET scans in detecting such cutaneous metastases and the potential for mismanagement due to diagnostic oversight.

Case Presentation: We present a detailed case study of a 43-year-old female with a history of metastatic TNBC, who developed suspicious skin lesions post-treatment. Despite initial negative PET scan results, further investigations revealed CE through histopathological examination of skin biopsies. The case highlights the critical need for biopsy in the presence of new skin lesions in breast cancer survivors, irrespective of imaging results. It also underscores the possibility of lymphatic spread of CE, which could lead to life-threatening complications if not properly managed.

Conclusion: The diagnosis of carcinoma erysipeloides must be considered in patients with breast cancer presenting with unusual skin lesions. Increased vigilance and dermatological assessment should be integral to the post-cancer follow-up regimen. The findings provide support for revising current treatment protocols and guidelines to better manage and potentially prevent the complications associated with this diagnosis. Enhanced surveillance for dermatological changes and a more aggressive approach to the biopsy of new skin lesions in cancer patients are recommended to improve outcomes and prevent the misdiagnosis of CE.

Copyright © 2024. This is an open-access article distributed under the terms of the [Creative Commons Attribution-Non-Commercial 4.0](https://creativecommons.org/licenses/by-nc/4.0/) International License, which permits copy and redistribution of the material in any medium or format or adapt, remix, transform, and build upon the material for any purpose, except for commercial purposes.

INTRODUCTION

Carcinoma erysipeloides (CE) is an uncommon form of cutaneous metastasis primarily noted in patients previously diagnosed with malignancies, especially breast cancer. This condition, often

misinterpreted as erysipelas due to its similar dermatological presentation, arises predominantly following the diagnosis and surgical treatment of triple-negative breast cancer (TNBC).¹ TNBC, marked by the absence of estrogen receptors, progesterone receptors, and minimal HER2 expression, is notorious for its aggressive clinical course and high metastatic potential, including a propensity for lymphatic dissemination.² The pathophysiology of CE involves the migration of

***Address for correspondence:**Maher Monir Akl,
Department of Chemistry, Faculty of Science, Mansoura
University, 35516, Mansoura, Egypt.
Phone: +201020432031
E-mail: maherakl555@gmail.com



malignant cells into the lymphatic system following surgical interventions such as mastectomy and axillary lymph node dissection. These procedures can disrupt lymphatic pathways, facilitating the spread of cancer cells that subsequently lodge in the skin. The resultant dermatological manifestation includes erythematous, warm, and tender plaques, which can easily be mistaken for bacterial infections or inflammatory dermatoses.³ The similarity in appearance to benign conditions makes CE particularly challenging to diagnose, especially in patients who are considered clinically free of the primary disease based on imaging studies, including positron emission tomography (PET) scans. PET scans, commonly utilized for oncological surveillance, detect areas of high metabolic activity typical of cancerous growths.⁴ However, the metabolic signature of CE might not be sufficiently distinct, especially in its early stages or when the metastatic nodules are small. Thus, CE can remain undetected in PET scans, which rely on glucose metabolism. Cancer cells in CE might not exhibit the same level of metabolic activity as the primary tumor or other metastatic sites, leading to false negatives.^{5,6} The lack of detection by PET underscores the importance of clinical vigilance and the potential need for skin biopsies in patients presenting with unexplained skin lesions post-cancer treatment.⁷ This diagnostic challenge highlights the critical gap between clinical and radiological assessments in oncology, particularly in post-treatment surveillance of aggressive cancers such as TNBC. It necessitates a multidisciplinary approach to postoperative care, integrating clinical examination with radiologic imaging and, when indicated, dermatological assessment to ensure early detection and management of metastatic complications such as Carcinoma erysipeloides.⁸ In this study, we address a critical case of a 44-year-old female patient who suffered from triple-negative breast cancer and underwent total mastectomy followed by complete remission. Despite regular follow-ups using PET scans to monitor any signs of metastatic spread, the patient developed cutaneous lesions that were initially misdiagnosed due to their clinical resemblance to bacterial and fungal infections. The lesions were later identified as Carcinoma erysipeloides (CE), a form of cutaneous metastasis that can mimic less severe dermatological conditions.

CASE PRESENTATION

The patient was a 43-year-old premenopausal woman of white race and Arab ethnicity, diagnosed with metastatic right breast cancer (invasive mammary carcinoma) that had metastasized to her lymph nodes and bones. She initially presented with

a 3 cm palpable mass in the upper outer quadrant of her right breast, accompanied by pain, fatigue, and weight loss. Mammography revealed spiculated and irregular borders of the mass, while her lymph nodes in the right axillary region were firm and rubbery. Despite having no prior medical history, she had a positive family history of hormonal breast cancer. The treatment regimen included chemotherapy, radiation therapy, which she successfully underwent.

Clinical Timeline

Initial Diagnosis and Treatment

August 30, 2022: The patient was diagnosed with triple-negative breast cancer (TNBC) in the right breast. A mammogram and ultrasound on the same day revealed a right upper quadrant asymmetry and a retro-areolar thickening mass classified as BIRADS 5, with ultrasound showing infiltration of the surrounding parenchyma and metastatic lymph nodes.

September 5, 2022: Core biopsy confirmed invasive ductal carcinoma grade II, with positive vascular invasion, negative estrogen receptor (ER), negative progesterone receptor (PR), and HER2/neu (score 1+).

September 6, 2022: A metastatic workup, including a PET/CT scan, revealed an ill-defined infiltrative lesion in the right breast and axillary lymph node metastasis, with no clinical evidence of metastasis in the brain, neck, chest, abdomen, or pelvis.

Progression and Treatment

March 12, 2023: Combined digital tomosynthesis, mammography, and breast sonography identified a spiculated mass with suspicious segmental calcifications.

April 1, 2023: Despite receiving four cycles of Adriamycin and cyclophosphamide, followed by 12 short courses of paclitaxel and carboplatin, the tumor size returned to its original dimensions, indicating aggressive recurrence.

April 30, 2023: The patient underwent a modified radical mastectomy with axillary clearance. Histopathological examination showed grade 3 invasive ductal carcinoma, ER-negative, PR-negative, and HER2-negative (score 0).

Development of Skin Lesion

In January 2024, the patient developed a skin lesion initially misdiagnosed as a type of eczema (Figure 1), as it did not show metabolic activity on the PET scan and was thus overlooked as a potential carcinoma erysipeloides. An F-18 FDG PET/CT scan conducted before and during the development of skin lesions revealed metabolically active lymph nodes in



axillary, pectoral, mediastinal, external iliac, and inguinal regions. No hypermetabolic lesions indicating tumoral residue or recurrence were detected, and no significant abnormalities were found elsewhere (Figure 2). This lesion was biopsied on February 15, 2024, confirming metastatic deposits.

Diagnostic Biopsy Examination Histopathology and Immunohistochemistry (IHC) Analysis

The specimen, a 1.5 cm skin nodule excised from the abdominal area, appeared firm and erythematous upon gross examination, with no other abnormalities noted (Figure 3).

Microscopic analysis revealed clusters of atypical epithelial cells infiltrating the dermal layer, indicative of metastatic carcinoma. These cells were characterized by irregular nuclei and scant cytoplasm, with evident surrounding dermal lymphatic invasion suggesting potential lymphatic spread. Immunohistochemical staining confirmed negative statuses for Estrogen Receptor (ER), Progesterone Receptor (PgR), and HER2, with scores respectively noted as negative on-slide while positive control cells stained as expected, confirming the accuracy and specificity of the procedure. The diagnosis was metastatic carcinomatous deposits in an abdominal skin nodule with ER, PgR, and HER2 all showing negative results. Recommendations underscored the inclusion of positive and negative controls in the immunohistochemistry run for each antibody, and

both cold ischemia and fixation times met the ASCO/CAP guidelines requirements.

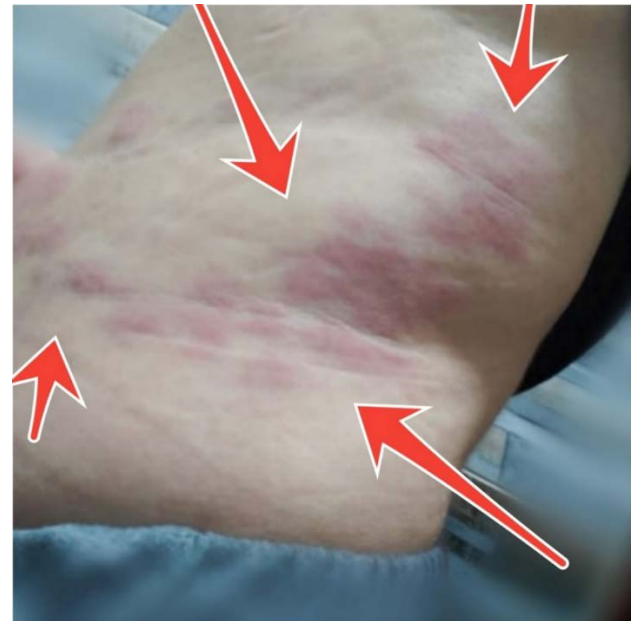

Figure 1. The initial presentation of Carcinoma erysipeloides, characterized by subtle skin changes that were initially mismanaged due to the rarity of this condition. The image illustrates the early stage of this skin cancer type, where the lesions appear deceptively benign, leading to an underestimation of the severity and necessary medical intervention.

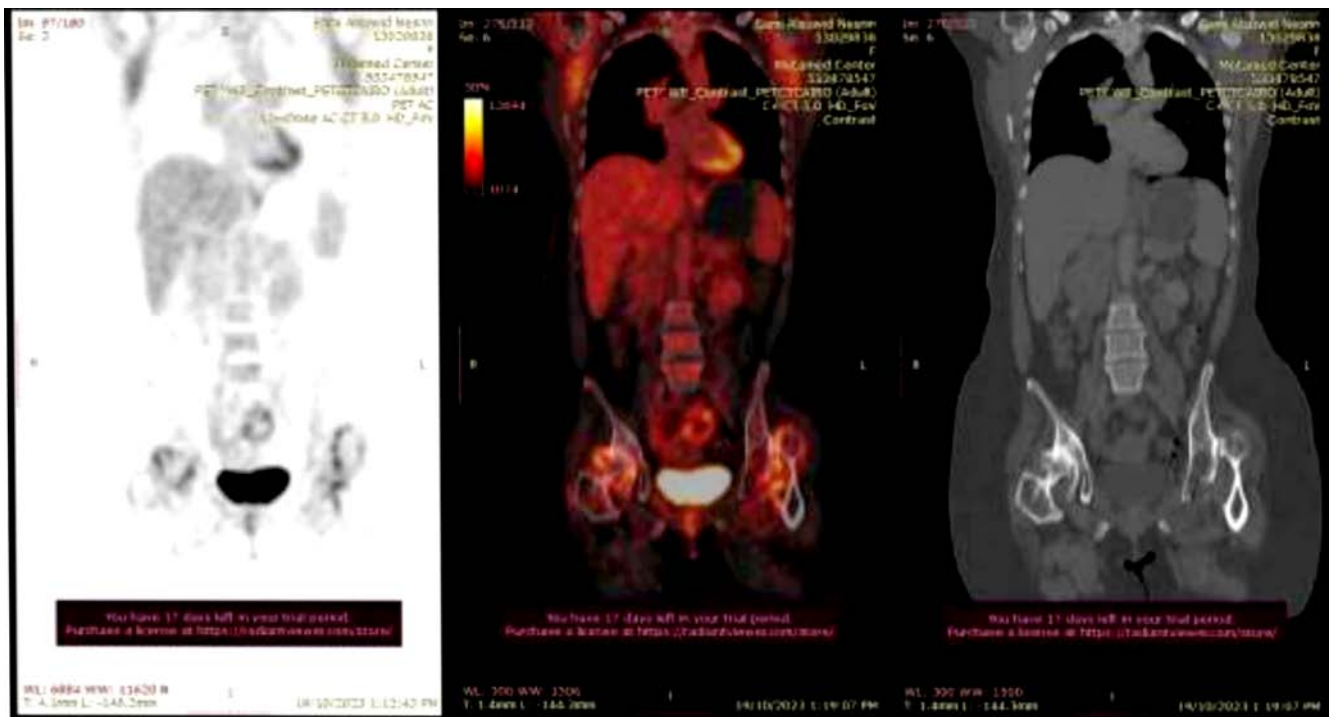

Figure 2. An F-18 FDG PET/CT scan on a right breast cancer patient revealed metabolically active lymph nodes, including axillary, pectoral, mediastinal, external iliac, and inguinal nodes. The scan also suggested an old case of right femoral avascular necrosis and left hip dislocation. No hypermetabolic lesions indicating tumoral residue/recurrence were found, and the rest of the body showed no significant abnormalities in the PET/CT images.

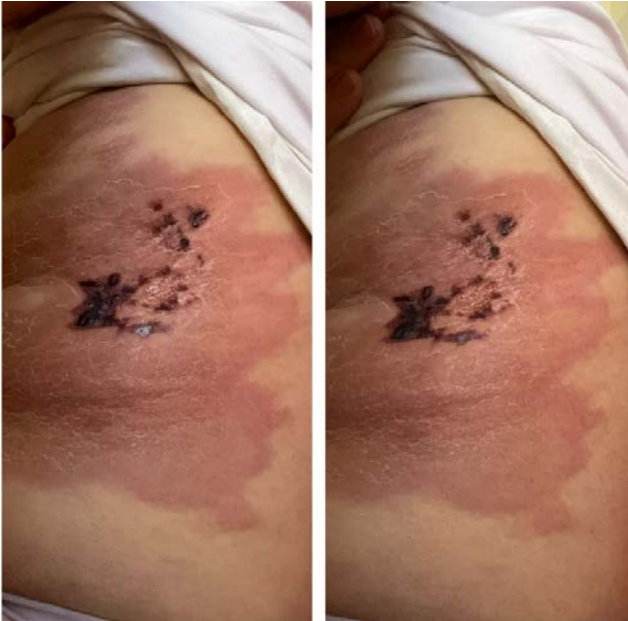

Figure 3. The progression of Carcinoma erysipeloides following an initial diagnostic error. The image captures the exacerbated condition of the skin tumor, displaying extensive erythematous lesions with raised borders that indicate a severe advancement of the disease due to delayed recognition and appropriate treatment of this cancer type.

The IHC analysis yielded the following results

Estrogen Receptor (ER) Status: Negative (positive control cells stained as expected)

Progesterone Receptor (PgR) Status: Negative (positive control cells stained as expected)

HER2 (by immunohistochemistry): Negative (score 0) (positive control cells stained as expected)

Diagnosis and Treatment

The final diagnosis was carcinoma erysipeloides, metastasizing likely through the lymphatic pathway, as the lesion did not appear on the PET scan, which would have indicated hematogenous spread. The patient is currently managed according to carcinoma erysipeloides treatment protocols, ensuring accurate and targeted care. The comparison of these pathological findings with characteristics typical of Carcinoma erysipeloides highlights the risk of misdiagnosis, which could dangerously mislead treatment directions and endanger the patient's life due to the tumor's potential to metastasize through hematogenous or lymphatic routes to vital organs, leading to possible organ failure.

DISCUSSION

The case presented here of Carcinoma erysipeloides (CE) underscores critical distinctions from conventional manifestations, particularly within the context of triple-negative breast cancer (TNBC). CE, a rare cutaneous metastasis of breast cancer,

poses formidable diagnostic challenges due to its atypical presentation and resemblance to benign dermatological conditions.

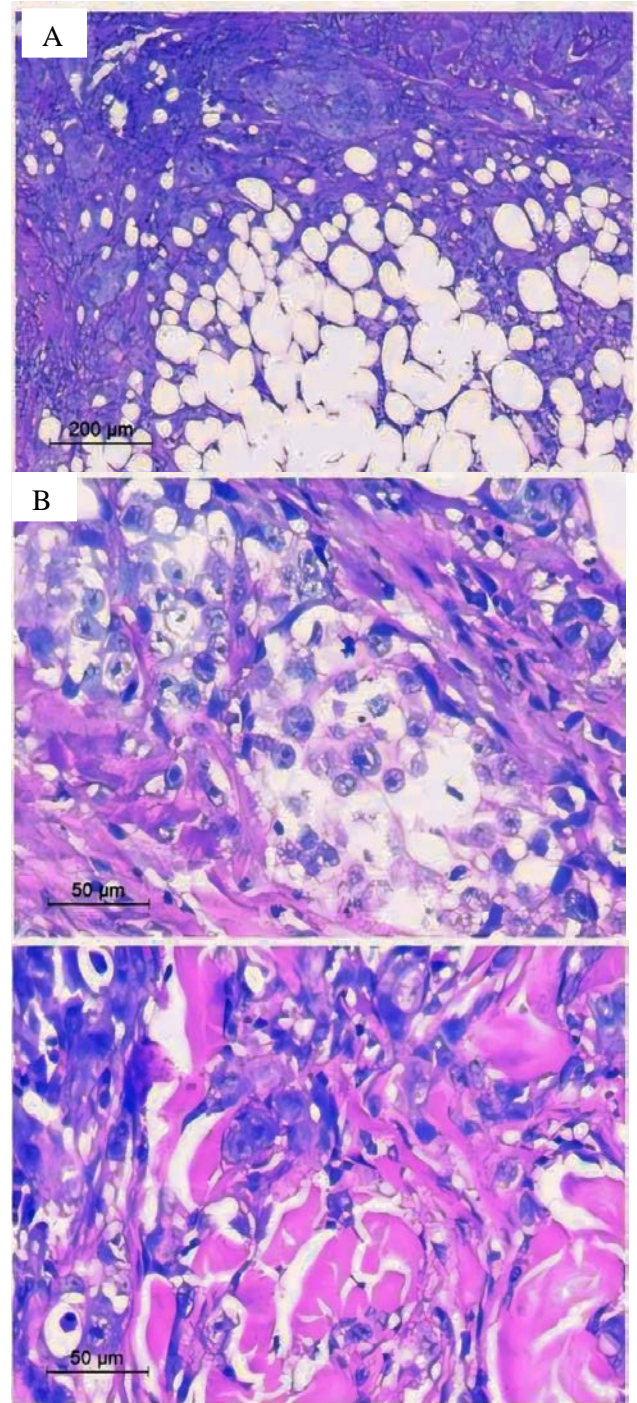


Figure 4. Histopathologic changes in carcinoma erysipeloides; (A) Histopathological examination of skin tissue revealing metastatic carcinomatous deposits. Hematoxylin and eosin (H&E) staining at low magnification (scale bar: 200 µm). The image demonstrates widespread infiltration of tumor cells within the dermis, forming irregular clusters and nests, indicative of metastatic carcinoma. (B) Higher magnification of metastatic carcinoma deposits in skin tissue. H&E staining (scale bar: 50 µm). Tumor cells exhibit pleomorphic nuclei, prominent nucleoli, and abundant eosinophilic cytoplasm.



There is significant stromal desmoplasia and lymphovascular invasion, highlighting the aggressive nature of the metastasis. (C) Detailed view of metastatic carcinoma within the skin. H&E staining (scale bar: 50 μ m). The image shows clusters of tumor cells surrounded by dense fibrotic stroma. The absence of estrogen receptor (ER), progesterone receptor (PR), and HER2 expression is implied, consistent with triple-negative breast cancer (TNBC) metastasis.

Traditional CE cases typically exhibit infiltrative tumor cells in the dermis, forming irregular clusters and nests indicative of metastatic carcinoma. These tumors often display pleomorphic nuclei, prominent nucleoli, and eosinophilic cytoplasm, reflecting their aggressive nature. Stromal desmoplasia and lymphovascular invasion may also be present, suggesting potential systemic dissemination and indicating an advanced disease stage.

In contrast, the novel presentation observed in this case involves extensive infiltration of metastatic carcinomatous deposits within the dermis, characterized by similar irregular clusters and nests of tumor cells but with distinctive morphological features. Importantly, the absence of estrogen receptor (ER), progesterone receptor (PR), and HER2 expression denotes a triple-negative breast cancer (TNBC) metastatic profile, complicating therapeutic strategies.

This discussion highlights the profound implications of misdiagnosing CE, particularly in TNBC cases, where rapid progression via hematogenous and lymphatic routes is feasible. Unlike primary tumors or more metabolically active metastatic sites, cutaneous metastases like CE often exhibit subdued metabolic activity, posing challenges for detection through conventional imaging modalities such as PET scans. This diagnostic complexity underscores the necessity of histopathological confirmation, as reliance solely on imaging findings may lead to suboptimal treatment decisions.

Furthermore, the potential for CE to disseminate systemically via lymphatic and hematogenous routes underscores the importance of vigilant surveillance and prompt intervention upon identifying suspicious skin lesions in breast cancer survivors. Integrating dermatological assessments into routine follow-ups and advocating for biopsy when clinical suspicion arises are essential to ensure accurate diagnosis and appropriate management of CE. These measures are pivotal in tailoring therapeutic approaches that address the unique challenges posed by this metastatic manifestation, thereby improving patient outcomes and minimizing systemic complications.

The Lymphocytic Variant of Triple-Negative Breast Cancer Carcinoma Erysipeloides (L-TNBC-

CE) classification underscores the pioneering nature of this subtype, highlighting advanced lymphatic spread and a distinctive pathological profile. This designation not only advances the field of dermatological oncology but also emphasizes the importance of comprehensive evaluation in managing metastatic breast cancer, particularly in cases presenting with unconventional cutaneous manifestations like CE. Continued research endeavors are warranted to further characterize and classify this distinct subtype within the spectrum of Carcinoma erysipeloides, potentially facilitating more precise therapeutic strategies in the future.

CONCLUSION

In this case, we have presented and documented the first unique case of a secondary pathological tumor arising from Carcinoma Erysipeloides following triple-negative breast cancer, which we have designated as "L-TNBC-CE". This novel presentation involves extensive infiltration of metastatic carcinomatous deposits within the dermis, characterized by irregular clusters and nests of tumor cells with distinctive morphological features. The absence of estrogen receptor (ER), progesterone receptor (PR), and HER2 expression confirms the triple-negative breast cancer (TNBC) subtype. Given the diagnostic challenges associated with Carcinoma Erysipeloides, it is imperative to consider this condition in patients with breast cancer presenting with unusual skin lesions. Increased vigilance and dermatological assessment should be integral to the post-cancer follow-up regimen. The findings from our study advocate for revising current treatment protocols and guidelines to better manage and potentially prevent complications associated with this diagnosis. Enhanced surveillance for dermatological changes and a more aggressive approach to biopsy new skin lesions in cancer patients are recommended to improve outcomes and prevent the misdiagnosis of CE. These unique features suggest that "L-TNBC-CE" represents the evolution of a new subtype of Erysipeloid carcinoma derived from triple-negative breast cancer.

ETHICAL CONSIDERATIONS

The patient provided written informed consent to

publish the information and images contained in the case report.

CONFLICT OF INTERESTS

The authors declare that there are no conflicts of interest.



FUNDING

The authors received no financial support for the research and publication of this article.

ACKNOWLEDGEMENTS

None.

REFERENCES

1. Al Ameer A, Imran M, Kaliyadan F, Chopra R. Carcinoma erysipeloides as a presenting feature of breast carcinoma: A case report and brief review of literature. *Indian dermatology online journal*, 2015: 6(6), 396–398. doi:10.4103/2229-5178.169724.
2. Yao H, He G, Yan S, Chen C, Song L, Rosol TJ, et al. Triple-negative breast cancer: is there a treatment on the horizon? *Oncotarget*, 2017: 8(1), 1913–1924. doi:10.18632/oncotarget.12284.
3. Natale G, Stouthandel MEJ, Van Hoof T, Bocci G. The Lymphatic System in Breast Cancer: Anatomical and Molecular Approaches. *Medicina (Kaunas, Lithuania)*, 2021: 57(11), 1272. doi:10.3390/medicina57111272.
4. Akay S, Pollard JH, Saad Eddin A, Alatoum A, Kandemirli S, Gholamrezanezhad A, et al. PET/CT Imaging in Treatment Planning and Surveillance of Sinonasal Neoplasms. *Cancers*. 2023;15(15), 3759. doi:10.3390/cancers15153759.
5. Alexis F, Leggett, LR, Agarwal N, Bakhtin Z, Farabi B. Carcinoma Erysipeloides With Clinical and Dermatoscopic Features: An Overlooked Clinical Manifestation of Breast Cancer. *Cureus*, 2022;14(3), e23445. doi:10.7759/cureus.23445.
6. Bergers G, Fendt SM. The metabolism of cancer cells during metastasis. *Nature reviews. Cancer*, 2021: 21(3), 162–180. doi:10.1038/s41568-020-00320-2.
7. Bailleux S, Collins P, Nikkels AF. The Relevance of Skin Biopsies in General Internal Medicine: Facts and Myths. *Dermatology and therapy*, 2022;12(5), 1103–1119. doi:10.1007/s13555-022-00717-x.
8. Berardi R, Morgese F, Rinaldi S, Torniai M, Mentrasti G, et al. Benefits and Limitations of a Multidisciplinary Approach in Cancer Patient Management. *Cancer management and research*, 12, 9363–9374. doi:10.2147/CMAR.S220976..

How to Cite This Article

Amer A, Akl M. Lymphocytic Variant of Triple-Negative Breast Cancer Carcinoma Erysipeloides (L-TNBC-CE): A Novel Rare Case of Carcinoma Erysipeloides Following TNBC Mastectomy. *Arch Breast Cancer*. 2024; 11(3):307-12.

Available from: <https://www.archbreastcancer.com/index.php/abc/article/view/927>