









DOI: 10.32768/abc.2023103301-305



Disease Control of Inoperable HER2-Positive Breast Cancer by Targeted Molecular Drugs and Radiotherapy: A Case Report

Mai Kitazawa^{*a}, Yoshihiro Kawaguchi^a, Shigeyuki Sugie^b, Chiyoko Makita^c, Takuya Taniguchi^d, Shuto Nakaya^d

^aDepartment of Breast Surgery, Asahi University Hospital, Hashimoto-cho, Gifu, Japan

^bDepartment of Pathology, Asahi University Hospital, Hashimoto-cho, Gifu, Japan

^cDepartment of Radiology, Gifu University Hospital, Yanagido, Gifu, Japan

^dDepartment of Radiation Oncology, Asahi University Hospital, Hashimoto-cho, Gifu, Japan

ARTICLE INFO

ABSTRACT

Received:

17 February 2023

Revised:

12 April 2023

Accepted:

23 April 2023

Keywords:

Breast cancer, Elderly patient, chemotherapy, HER2/neu, radiotherapy

Background: The number of elderly patients with breast cancer has increased in recent years, many of whom reside alone. This makes choosing their treatment difficult because of domestic considerations and declining physical and cognitive functions. Chemotherapy is often omitted owing to age, and treatment can subsequently be inadequate.

Case presentation: Our patient was an 82-year-old woman presenting with the chief complaint of an enlarged left breast mass. The mass had undergone self-destruction with hemorrhage and enlarged left axillary and supraclavicular lymph nodes. She lived alone; therefore, initial chemotherapy of trastuzumab (HER)+pertuzumab (PER)+weekly paclitaxel (wPTX) two-step dose reduction was performed in the hospital. A subcutaneous mass appeared, which disappeared after irradiation. Subsequently, tri-weekly HER+PER administration was continued.

Conclusion: A multidisciplinary approach to therapy may offer elderly patients living alone with inoperable breast cancer patients the ability to continue treatment and control their disease following careful consideration of their comorbidities and decline in physical and cognitive functions. Such multidisciplinary treatment options minimize the occurrence of side effects, allowing for long-term continuation of therapy, helping to maintain quality of life and potentially prolonging overall survival.

Copyright © 2022. This is an open-access article distributed under the terms of the [Creative Commons Attribution-Non-Commercial 4.0 International License](https://creativecommons.org/licenses/by-nc/4.0/), which permits copy and redistribution of the material in any medium or format or adapt, remix, transform, and build upon the material for any purpose, except for commercial purposes.

INTRODUCTION

Human epidermal growth factor receptor 2 (HER2) positive breast cancer accounts for about 20% of all breast cancers, with many studies reporting poor prognosis due to the highly malignant biological nature of this cancer type, quick disease progression and the likelihood of metastases.¹⁻³ Since the first anti-

HER2 agent, trastuzumab, was introduced into clinical trials, followed by several other anti-HER2 agents, the prognoses for patients with HER2-positive breast cancer have significantly improved.⁴

As the elderly population has grown, breast cancer in this population has also increased with many patients over the age of 80 years, and frequently living alone. The best treatment options for HER2-positive breast cancer among patients in this elderly age bracket, are currently difficult to determine. This is due to a lack of evidence and the need to consider the family environment in addition to physical and

***Address for correspondence:**

Mai Kitazawa, MD,
Department of Breast Surgery, Asahi University Hospital,
3-23 Hashimoto-cho, Gifu 500-8523, Japan.
Tel:+81582538001
Email: kitapi0604@gmail.com



cognitive decline. Notably, chemotherapy is often omitted for age-related reasons alone, and treatment options are often inadequate.

Here, we report a case of an elderly patient living alone with inoperable HER2-positive breast cancer, who received chemotherapy at a reduced dose (to minimize side effects) in addition to molecular-targeted drugs, followed by radiation therapy, and continued treatment with molecular-targeted drugs.

We believe against curtailing treatment due to the age of the patient; rather, treatment selection should consider the health and family environment of each elderly patient. Meticulous consideration is needed for such patients, and the combination of pharmacotherapy and radiotherapy (RT) with minimal side effects can also maintain a good quality of life (QoL) and prolong overall survival (OS).

CASE PRESENTATION

An 82-year-old woman visited our hospital alone in July of X year. She had noticed masses in her left breast for 3 years but had been self-prescribing alternative treatment and had not visited a hospital. In the past few months, the mass had suddenly increased in size, and begun to bleed and exudate. There was a 10×10cm large mass with ulceration centered in the left C area and a 3×2cm mass in the left B area (Figure 1A and 1B). The mass was hemorrhagic with exudate and foul odor. Erythema was observed in the entire anterior chest area. Swollen left axillary and left cervical lymph nodes were palpated.

Mammography (MMG) and ultrasound (US) could not be performed because of the large-sized, hemorrhagic, and pus exudating tumor. Contrast-enhanced computed tomography revealed a 10cm tumor with ulcers and internal necrosis. Swelling of both the axillary and left supraclavicular lymph nodes, and skin thickening of the anterior thoracic region were observed (Figure 2A and 2B).

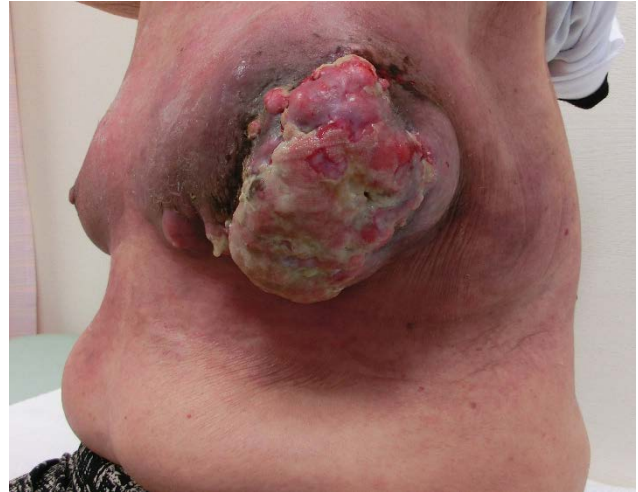
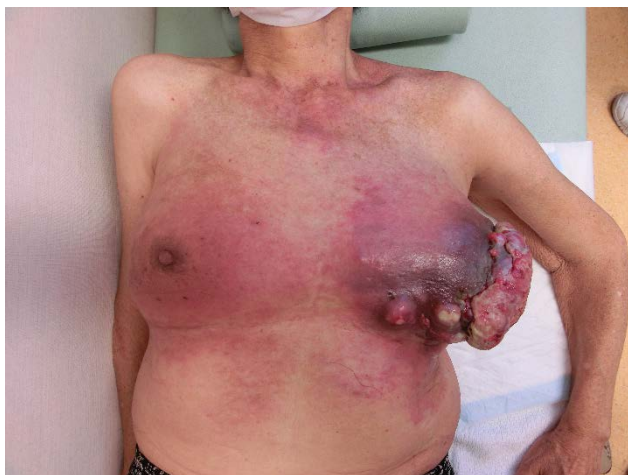
Figure 1. A and B. There is a large mass of 10 × 10 cm in the left C region and 3 × 2 cm in the left B region, which was hemorrhagic with exudate and foul odor. The entire anterior thoracic region was erythematous, with palpable left axillary and cervical lymphadenopathy.

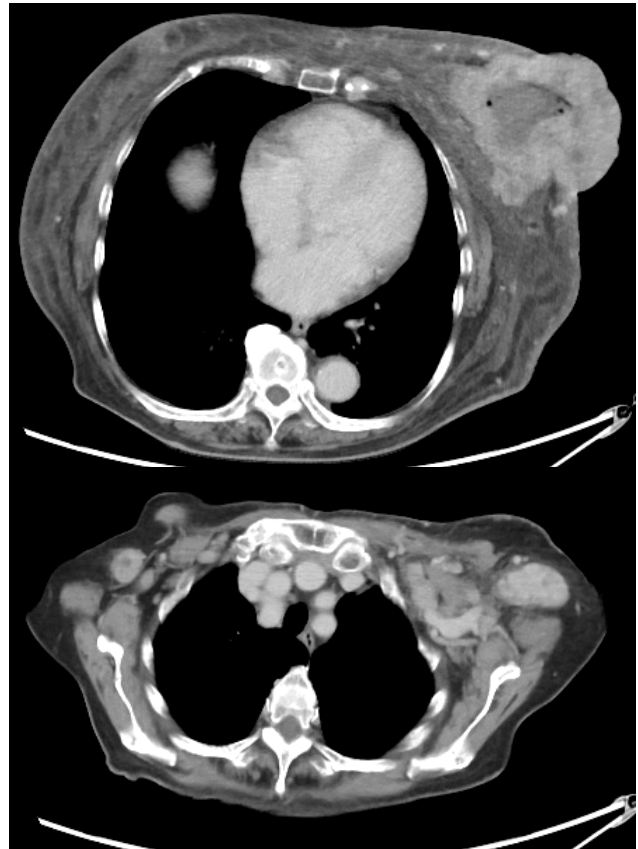


Figure 2. A and B. A 10cm large tumor was observed, with internal necrosis. Both axillary and left supraclavicular lymph nodes were swollen and the skin of the anterior chest was thickened. No distant metastases were observed.

There was no evidence of distant metastasis. Blood samples showed elevated levels of C-reactive protein (CRP), Carcinoembryonic antigen (CEA), CA15-3, and P53ad. There was a minor decrease in the Alb and Hb levels. There were no abnormalities in the renal or hepatic function. The clinical stage was



cT4c (10 cm), N3c M0 stage IIIc ER (\pm), PgR (-), HER2 (3+), and Ki67 50%.

As the patient resided alone, she was hospitalized and administered initial chemotherapy with HER+PER+wPTX with a two-step dose reduction (i.e., her dosage was twice reduced with no change in dosing interval). During hospitalization, we provided educational programs for wound care and improving malnutrition, together with nurses and dietitians. The patient was transferred to outpatient chemotherapy from the second course. A total of nine courses were administered.

Six months after the initial chemotherapy, the tumors had shrunk significantly, and the ulcer effusion had disappeared. Chemotherapy was reduced to HER+PER and continued every 3 weeks.

Seven months after the initial chemotherapy, a dermal mass appeared in the left C area, tending to increase in size (Figure 3A and 3B).

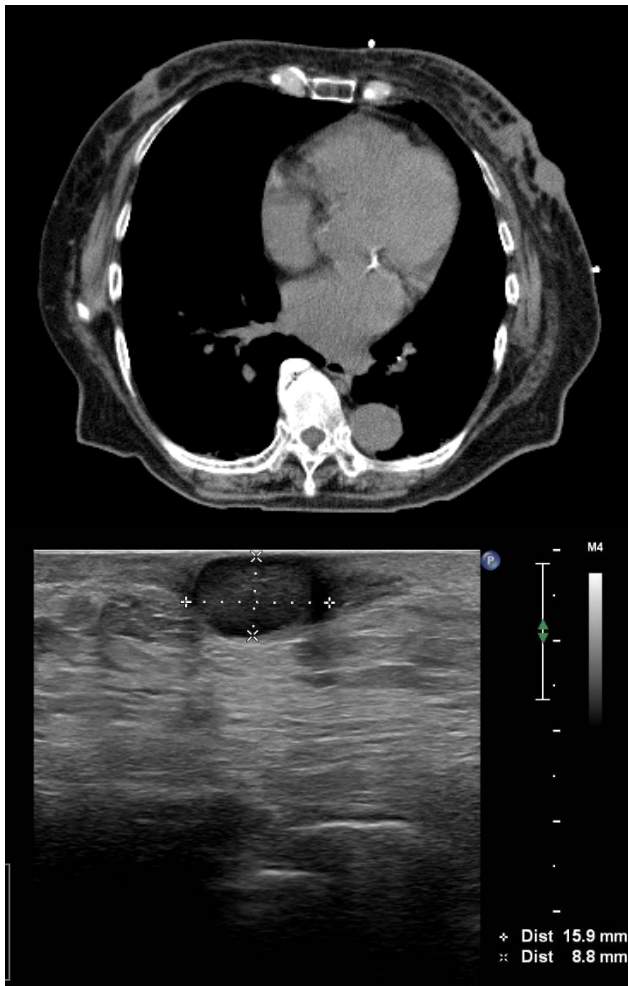

Figure 3. A and B. Seven months after initial chemotherapy, a skin mass appeared in the left C area and appeared to increase.

To treat this subcutaneous mass, standard hypofractionated radiotherapy (42.5Gy/16fr) was given with additional X-X-ray irradiation (10.64Gy/4fr) and electron beam radiotherapy

(6Gy/3fr) was also given to high-risk areas, after which the mass disappeared (**Figure 4A and 4B**). Radiation-induced skin damage occurred, but the treatment was continued in the outpatient departments of breast surgery and radiology. Subsequently, no regrowth was observed.

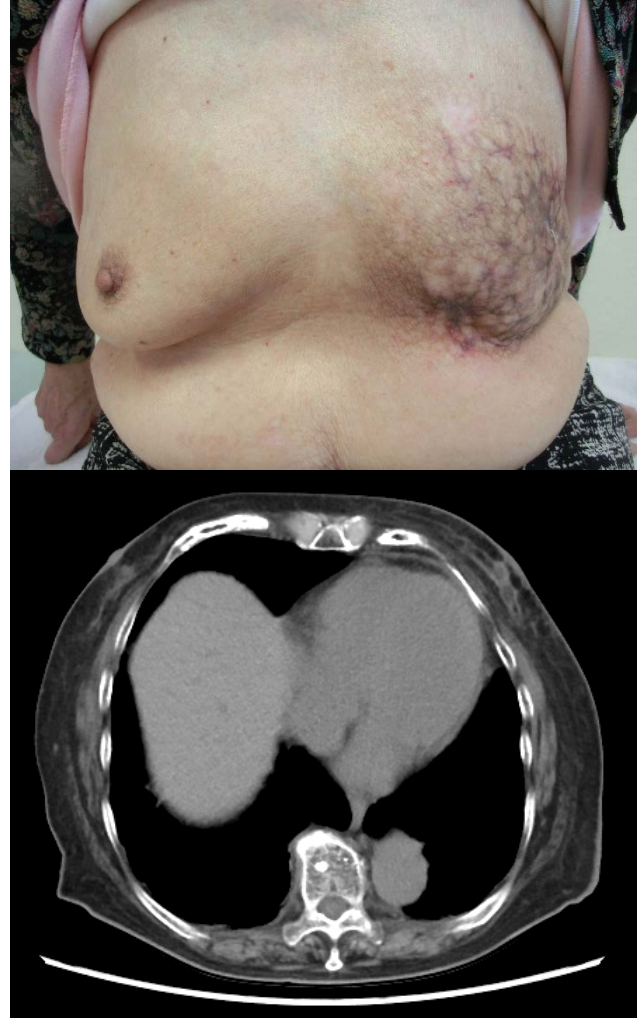

Figure 4. A and B. While radiation-induced skin damage occurred, it was deemed acceptable, and subsequent regeneration of the mass has not been observed to date.

Currently, only HER+PER has been administered once every 3 weeks, with no evidence of regrowth of the left breast mass or metastasis to multiple organs. The patient has resumed living alone and engaging in social activities without any side effects, such as decreased cardiac function.

DISCUSSION

According to The Japanese Breast Cancer Society Clinical Practice Guidelines for Breast Cancer 2022, although the combination of chemotherapy and anti-HER2 therapy is recommended for the postoperative treatment of HER2-positive breast cancer in the elderly⁽⁵⁾, the treatment should be neither excessive nor insufficient, and the treatment plan should be decided after thorough consultation with the patient's



family, nursing facility, and other parties, considering not only the patient's requests but also their comorbidities.⁶

Local control was previously considered to be the main goal of breast cancer treatment in the elderly, and tumor enucleation or total mastectomy to be the main treatment in Japan.⁷ However, the average life expectancy of 80-year-old women is 12.3 years, and that of 85- and 90-year-old very elderly women is 8.8 and 5.9 years, respectively.⁸ Therefore, we believe that systemic treatment is necessary to address the possibility of distant metastasis. However, the proportion of elderly patients with breast cancer receiving chemotherapy is significantly low, and chemotherapy is often omitted because of age alone, which can lead to inadequate treatment.⁹ Although comorbidities such as heart diseases can make the use of anthracyclines and taxanes difficult, a randomized controlled trial of trastuzumab with or without chemotherapy in the postoperative adjuvant treatment of elderly HER2-positive early stage breast cancer demonstrated the absence of non-inferiority of trastuzumab alone and the OS difference to be of 1 month at 3 years, reducing side effects and preserving healthy QoL.¹⁰ We believe that HER- and PER-based therapies can be a viable option for elderly HER2-positive breast cancer patients with comorbidities, showing physical and cognitive decline.

A study comparing preoperative chemotherapy and RT with only preoperative RT in locally advanced breast cancer showed a significant difference of 81.0% in 5-year disease-free survival for the former versus 71.6% for the latter ($P=0.04$), but no difference in OS.¹¹ RT is an option for patients with comorbidities and physical or cognitive decline. The use of definitive hypofractionated radiotherapy can lead to good local disease control, with acceptable side effects, and therefore offers a viable alternative to surgery for elderly patients¹² with inoperable breast cancer, with additional irradiation expected to further improve local disease control.¹³

In this case, local control via surgery was not possible because of the extensive spread of the tumor.

REFERENCES

1. Slamon DJ, Clark GM, Wong SG, Levin WJ, Ullrich A, McGuire WL. Human breast cancer: correlation of relapse and survival with amplification of the HER-2/neu oncogene. *Science*. 1987;235(4785):177–182. doi: 10.1126/science.3798106.
2. Clark GM, McGuire WL. Follow-up study of HER-2/neu amplification in primary breast cancer. *Cancer Res*. 1991;51(3):944–948.
3. Seshadri R, Firgaira FA, Horsfall DJ, McCaul K, Setlur V, Kitchen P. Clinical significance of HER-2/neu oncogene amplification in primary breast

However, treatment was continued without major side effects through inpatient chemotherapy, drug selection, dose reduction, and administration intervals. The patient did not show distant metastasis. Radiotherapy maintained good local control. We believe against curtailing treatment because of the patient's age; rather, treatment selection should consider the health status and family environment of each elderly patient. Meticulous consideration is needed for elderly patients living alone, but the combination of pharmacotherapy and RT with minimal side effects can also maintain a good quality of life and prolong OS.

CONCLUSION

In this case report, we determined that surgery was not curative for such locally advanced HER2-positive breast cancer, and so we provided systemic therapy to the patient. Even elderly patients living alone with inoperable breast cancer may be able to continue treatment and control their disease following careful consideration of their comorbidities and decline in physical and cognitive functions. Such multidisciplinary treatment options minimize the occurrence of intolerable side effects, allowing for long-term continuation of therapy, helping to maintain quality of life and potentially prolonging OS.

ETHICAL CONSIDERATIONS

The patient provided written informed consent to publish the information and the images contained in this case report.

ACKNOWLEDGEMENTS

None.

CONFLICT OF INTEREST

We have no conflict of interest to declare.

FUNDING

We received no funding for this case report.

4. cancer. The South Australian Breast Cancer Study Group. *J Clin Oncol*. 1993;11(10):1936–1942. doi: 10.1200/JCO.1993.11.10.1936.
5. Dawood S, Broglio K, Buzdar AU, Hortobagyi GN, Giordano SH. Prognosis of women with metastatic breast cancer by HER2 status and trastuzumab treatment: an institutional-based review. *J Clin Oncol*. 2010;28(1):92–98. doi: 10.1200/JCO.2008.19.9844.
5. The Japanese Breast Cancer Society Clinical Practice Guidelines for Breast Cancer 2022, KANEHARA Syuppan. Tokyo; 2022, p.141-144.



6. Yoshioka S, Hojo S, Toyoda Y, Ito Y, Fukata T, Miyagaki M, et al. A case of an elderly with locoregional recurrence of ER-negative HER2-positive breast cancer successfully treated with local therapy. *Jpn J Cancer Chemother.* 2018;45(13):2232–2234.
7. Okishiro S, Egawa C, Kusama H, Matsushita K, Hashimoto T, Mukai Y, et al. Analysis of elderly breast cancer patients aged 90 years and older. *Jpn J Cancer Chemother.* 2013;40(12):2402–2404.
8. Ministry of Health, Labour and Welfare: Abridged Life Tables for Japan 2020. Available from: <https://www.mhlw.go.jp/english/database/db-hw/lifetb20/dl/lifetb20-06.pdf>.
9. Naito Y, Mukai H, Nagai S. Elderly breast cancer therapy: A Japanese experience. *Jpn J Clin Oncol.* 2010;40(8):717–721. doi: 10.1093/jjco/hyq061.
10. Sawaki M, Taira N, Uemura Y, Saito T, Baba S, Kobayashi K, et al. Randomized controlled trial of trastuzumab with or without chemotherapy for HER2-positive early breast cancer in older patients. *J Clin Oncol.* 2020;38(32):3743–3752. doi: 10.1200/JCO.20.00184.
11. Semiglazov VF, Topuzov EE, Bavli JL, Moiseyenko VM, Ivanova OA, Selezneve IK, et al. Primary (neoadjuvant) chemotherapy and radiotherapy compared with primary radiotherapy alone in stage IIb-IIIa breast cancer. *Ann Oncol.* 1994;5:591–595. doi: 10.1093/oxfordjournals.annonc.a058929.
12. Courdi A, Ortholan C, Hannoun-Lévi JM, Ferrero JM, Largillier R, Balu-Maestro C, et al. Long-term results of hypofractionated radiotherapy and hormonal therapy without surgery for breast cancer in elderly patients. *Radiother Oncol.* 2006;79(2):156–161. doi: 10.1016/j.radonc.2006.04.005.
13. Bartelink H, Horiot JC, Poortmans PM, Struikmans H, Van den Bogaert W, Fourquet A, et al. Impact of a higher radiation dose on local control and survival in breast-conserving therapy of early breast cancer: 10-year results of the randomized boost versus no boost EORTC 22881-10882 trial. *J Clin Oncol.* 2007;25(22):3259–3265. doi: 10.1200/JCO.2007.11.4991.

How to Cite This Article

Kitazawa M, Kawaguchi Y, Sugie S, Makita C, Taniguchi T, Nakaya S. Disease Control of Inoperable HER2-Positive Breast Cancer by Targeted Molecular Drugs and Radiotherapy: A Case Report. Arch Breast Cancer. 2023; 10(3): 301-5.

Available from: <https://www.archbreastcancer.com/index.php/abc/article/view/679>