



DOI: 10.32768/abc.2023102124-130



## The Value of Dynamic Contrast-Enhanced MRI in Predicting the Response of Idiopathic Granulomatous Mastitis to Steroid Therapy and Comparison of Clinical and Radiological Outcomes

Günay Rona<sup>\*a</sup>, Meral Arifoğlu<sup>a</sup>, Kenan Çetin<sup>b</sup>, Muhammet Fikri Kündeş<sup>b</sup><sup>a</sup>Department of Radiology, Kartal Doktor Lütfi Kırdar Training and Research Hospital, University of Health Sciences, Istanbul, Turkey<sup>b</sup>Department Of General Surgery, Kartal Doktor Lütfi Kırdar Training and Research Hospital, University of Health Sciences, Istanbul, Turkey

### ARTICLE INFO

**Received:**

28 December 2022

**Revised:**

30 January 2023

**Accepted:**

1 February 2023

**Keywords:**Granulomatous Mastitis,  
Magnetic Resonance  
Imaging,  
Treatment, Outcome,  
Steroids.

### ABSTRACT

**Background:** The aim of this study was to investigate the value of pre-treatment dynamic contrast-enhanced MRI (DCE-MRI) findings in predicting clinical and radiological response to treatment in patients with idiopathic granulomatous mastitis (IGM) receiving steroid therapy and to compare clinical and DCE-MRI results after treatment.

**Methods:** Pre- and post-treatment MRI examinations of 86 patients (with a mean age of 33.8 years; range, 20–57 years) diagnosed with IGM between January 2014 and September 2022 were retrospectively evaluated. Lesion characteristics and longest diameter, number of involved quadrants, retroareolar involvement, and presence of fistula or lymphadenopathy were noted. Patients were categorized into clinical complete response (CCR), clinical non-response (CNR) groups based on clinical response and into radiological complete response (RCR) and radiological non-response (RNR) groups based on radiological response.

**Results:** The analyses revealed no relationship between the lesion type (abscess, NME, abscess, and NME), presence of lymphadenopathy or fistula, number of involved quadrants, retroareolar involvement, and treatment response on pre-treatment MRI ( $P > 0.05$ ). The longest lesion diameter was smaller in the CCR group than in the CNR group ( $P = 0.02$ ). After treatment, 40.7% (35/86) of the patients achieved RCR + CCR, while 16.3% (14/86) achieved RNR + CNR. On the other hand, 43% (37/86) of the patients achieved CCR + RNR.

**Conclusion:** CCR is more common in patients with smaller lesions. Other pre-treatment MRI findings were not correlated with radiological or clinical response. A significant proportion of patients with CCR had residual lesions radiologically.

Copyright © 2023. This is an open-access article distributed under the terms of the [Creative Commons Attribution-Non-Commercial 4.0](https://creativecommons.org/licenses/by-nc/4.0/) International License, which permits copy and redistribution of the material in any medium or format or adapt, remix, transform, and build upon the material for any purpose, except for commercial purposes.

### INTRODUCTION

Idiopathic granulomatous mastitis (IGM) is a rare, chronic, and benign inflammatory disease of

unknown etiology that usually affects women of childbearing age who are typically in the first several postpartum years.<sup>1</sup> The etiology of IGM remains unknown and numerous theories have been proposed in this respect. The most accepted theory to explain the etiology is that the ductal contents are transferred to the lobular mammary stroma secondary to damage to the ductal epithelium, resulting in a local

**\*Address for correspondence:**Günay Rona, MD  
Cevizli Neighbourhood, Semsî Denizer Road. E-5 Highway  
District, 34890 Kartal, Istanbul/Turkey  
Tel: +902164583000  
Email: gunayrona@gmail.com



inflammatory response.<sup>2</sup> Taylor *et al.* suggested that granulomatous mastitis may be associated with infections caused by *Corynebacterium* species.<sup>3</sup> The disease has been more commonly reported in Asian, Hispanic, and Middle Eastern women. However, it affects individuals of all races and ethnicities.<sup>5</sup>

Clinically, IGM typically presents with features of abscess and malignancy. Physical examination often reveals a tender firm breast mass. In addition, clinical manifestations may include skin lesions, inflammation, galactorrhea, abscess, fistulas, and nipple retraction.<sup>1</sup> Since IGM cannot be definitively differentiated from malignancy and other types of mastitis radiologically, histopathological examination with core-needle biopsy is usually required to establish the diagnosis. Pathological examination shows noncaseating lobulocentric granulomas. Usually, major ducts and surrounding adipose tissue are preserved, while fibrosis is infrequent.<sup>5</sup>

The treatment of IGM is controversial and challenging. Corticosteroids are successful in the management of IGM and can be used before surgery.<sup>1,6-16</sup>

The aim of this study was to investigate the value of pre-treatment dynamic contrast MRI (DCE-MRI) findings in predicting clinical and radiological response to treatment in patients with idiopathic granulomatous mastitis (IGM) receiving steroid therapy and to compare DCE-MRI and clinical results.

#### *Key Messages*

- MRI findings are helpful in determining the response of idiopathic granulomatous mastitis (IGM) to steroid therapy.
- Lesion characteristics and the presence of lymphadenopathy or fistula on pre-treatment MRI are not successful in predicting the complete response of IGM to steroid therapy.

#### **METHODS**

This retrospective study was approved by our institutional review board (approval no: 202251422424). The requirement to obtain informed consent from the patients was waived.

#### *Patients*

A total of 204 patients with IGM diagnosed by core-needle biopsy between January 2014 and October 2022 in a large center in Turkey were evaluated. Microbiological testing (Gram, periodic acid-Schiff, and Ziehl-Neelsen staining; mycobacterial cultures; fungal analysis with Grocott-Gomori methenamine silver staining) was performed to exclude other types of mastitis. Purified protein

derivative (PPD) skin test and QuantiFERON test were also used to rule out tuberculous mastitis.

#### *Inclusion and Exclusion Criteria*

Patients who did not comply with treatment or were lost to follow-up and those who had never undergone MRI were excluded. The study included patients with pre- and post-treatment MRI, while those with a single MRI were not included in the study. Patients with any MRI not suitable for evaluation due to artifacts were also excluded.

#### *Treatment and Follow-up Procedure*

Patients were treated with 0.4 mg/kg methylprednisolone once daily and 0.125 % prednisolone ointment on weekdays. During the treatment, patients were followed up at 2-week intervals. The treatment of patients who achieved complete clinical response (CCR), developed side effects of steroids, or did not respond to steroids was discontinued. Due to the potential side effects, treatment was administered for a maximum of 6 months. Patients with no response to medical therapy underwent surgical treatment. Patients in the CCR group were followed up every 3 months with ultrasound (US) and clinical examination.

#### *MRI Technique*

MRI examinations were preferred to visualize the extent of the disease in the breast in more detail or in cases where clinical evaluation and US results were inconsistent. Pre-treatment MRIs were performed 5-10 days before or after the initiation of treatment, depending on patient density in the radiology department. Post-treatment MRIs were performed within 5-10 days of discontinuation of steroid therapy. Pre- and post-treatment MRI examinations of all patients were performed on a 1.5 T device (Philips Ingenia, Philips Healthcare, Best, The Netherlands). The three-dimensional fat-saturated ultrafast spoiled gradient echo DCE sequences were acquired. DCE sequences consisted of a total of six series, one of which was pre-contrast, followed by 90, 142, 194, 246, and 298 seconds after the injection of contrast agent. MRI examinations were performed in the prone position using a dedicated 16-channel phased-array breast coil (MammoTrak, Philips Healthcare, Amsterdam, The Netherlands), with the administration of 0.1 mmol per kilogram of body weight gadolinium chelate (Dotarem 0.5 mmol/mL, Guerbet, [Villepinte, France](#)) by an automated injector.

#### *MRI Analysis*

MRI evaluations were performed by two radiologists with 7 and 10 years of experience in breast imaging. All MRI images were reviewed in the



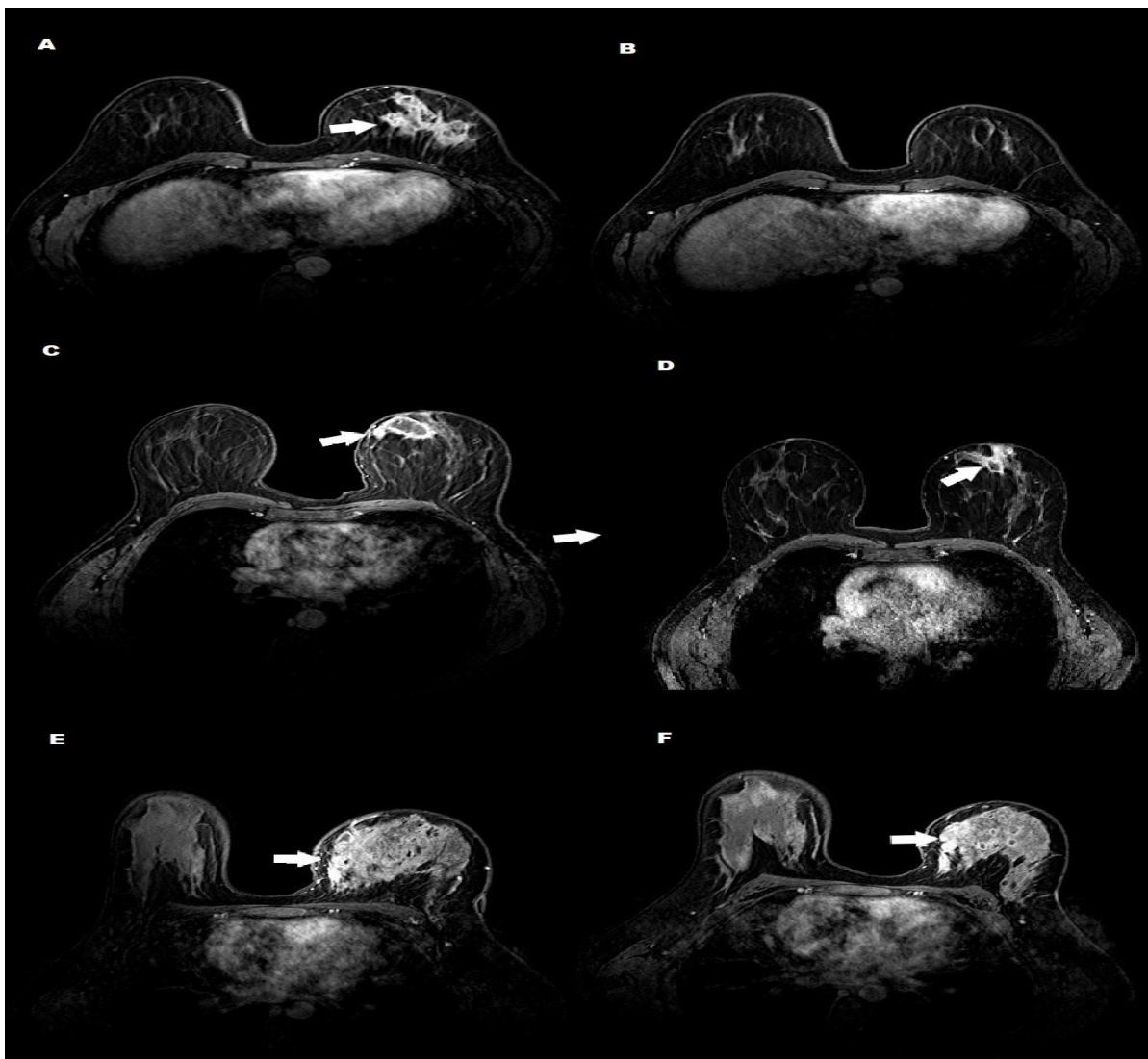
picture archiving and communication system (Infiniti Healthcare 3.0.11.4, Seoul, Republic of Korea) of the EIZO GS520 workstation (EIZO, [Hakusan, Ishikawa, Japan](#)). Pre- and post-treatment MRI examinations were evaluated.

Rim-enhancing lesions and mass lesions were considered masses. Masses and areas of non-mass enhancement (NME) were noted. The characteristic features of the lesions, longest diameter, number of involved quadrants, retroareolar involvement, enhancing fistulas, and lymphadenopathy with a cortical thickness greater than 3 mm were noted in both pre- and post-treatment DCE-MRIs. The maximal lesion size was measured on the first DCE image, which was acquired at 90 seconds.

### *Treatment Response*

The clinical evaluation was performed by two general surgeons with 9 and 28 years of experience in breast surgery. Healing of fistulas and ulcerations, resolution of palpable lesions, and regression of inflammatory findings were defined as a complete clinical response (CCR). Persistence or increase in findings was considered clinical non-response (CNR).

Patients were divided into two groups based on their post-treatment DCE-MRI findings: The disappearance of all lesions on MRI was considered radiological complete response (RCR), while the presence of still enhancing lesions was considered radiological non-response (RNR). (Figure 1).



**Figure 1.** The pre- and post-treatment MRI examinations of patients with IGM. The pre-treatment MRI (A) of a 30-year-old female patient shows a heterogeneous contrast-enhancing mass in the upper outer quadrant of the left breast (arrow), which completely resolved after treatment (B) and was considered a clinical and radiological complete response. The pre-treatment MRI (C) of a 44-year-old female patient shows a rim-enhancing abscess (arrow) in the upper inner quadrant of the left breast with a significant reduction in its size after treatment (D) (arrow), which was consistent with CCR and RNR. The pre-treatment MRI (E) of a 38-year-old female patient shows diffuse non-mass enhancement and abscess formations in the left breast (arrow). Since there was no significant regression in the findings after treatment (F) (arrow), it was classified as clinically and radiologically unresponsive.



*Statistical Analysis*

The study data were analyzed using the Statistical Package for Social Sciences (SPSS) version 25.0.0.0 software (IBM Corp., Armonk, N.Y., USA). Percentage, mean, and standard deviation were used to summarize descriptive results. The one-sample Kolmogorov–Smirnov test was performed to check whether the groups followed a normal distribution. Continuous variables with normal distribution were presented as mean ( $\pm$  standard deviation [SD]), while non-normally distributed variables were reported as median (interquartile range [IQR]). Categorical variables were expressed as numbers and proportions and compared using the chi-square test. Mann-Whitney U test was used to compare numerical data between independent two groups. Wilcoxon signed-rank test was used to compare dependent numerical data. A P-value <0.05 was considered statistically significant.

**RESULTS**

Out of a total of 204 patients, 18 patients who did not comply with treatment or were lost to follow-up, 34 patients without MRI, 59 patients with only one MRI, and 7 patients whose MRI could not be evaluated due to artifacts were excluded from the study. The remaining 86 patients with a mean age of 33.8 (20–57) years were included in the study. The median duration of treatment was 12 (8-20) weeks. Surgical treatment was administered to 85.7% (12/14) of the patients in the CNR group. The remaining 14.3% (2/14) of the patients were followed up without any treatment after abscess drainage.

Post-treatment MRI examinations of these patients were performed at a median of 148 days (104-197) after their pre-treatment MRI. The median maximal lesion size was 70mm (50-102) before treatment and 32mm (10-35) after treatment. The pre- and post-treatment MRI findings of the patients are given in detail in Table 1.

**Table 1.** Pre- and post-treatment MRI findings of the patients with idiopathic granulomatous mastitis treated with steroids

Findings	Pre-treatment (n, %)	Post-treatment (n, %)
<b>Lesion characteristics</b>		
Abscess	23 (26.7%)	24 (27.9%)
NME	19 (22.1%)	7 (8.1%)
Abscess and NME	44 (51.2%)	20 (23.3%)
No lesion	0	35 (40.7%)
Lymphadenopathy	78 (90.7%)	34 (39.5%)
Fistula	50 (58.5%)	0

NME; non-mass enhancement, CCR; complete clinical response, CNR; clinical non-response, RCR; radiological complete response, RNR; radiological non-response.

After treatment, 40.7% (35/86) of the patients achieved RCR + CCR, while 16.3% (14/86) achieved RNR + CNR. Although 43% (37/86) of the patients achieved CCR, they were in the RNR group. Table 2 illustrates treatment response groups in detail. Pre-treatment MRI findings by treatment response groups are presented in detail in Table 3.

**Table 2.** Clinical and radiological response groups of idiopathic granulomatous mastitis patients after steroid therapy

Groups	CCR n (%) (n=72)	CNR n (%) (n=14)
RCR (N:35)	35 (48.6%)	0
RNR (N:51)	37 (51.4%)	14 (100%)

CCR; complete clinical response, CNR; clinical non-response, RCR; radiological complete response, RNR; radiological non-response.

There was no relationship between the type of lesion (abscess, NME, abscess, and NME), presence of lymphadenopathy or fistula, number of involved quadrants, retroareolar involvement, and treatment response on pre-treatment MRI (P>0.05). There was no relation between lesion type, presence of lymphadenopathy or fistula, number of quadrants involved, retroareolar involvement and radiological response in pre-treatment MRI (P>0.05) (Table 3).

**Table 3.** Lesion characteristics on pre- and post-treatment MRIs by treatment response group

Parameters	CCR n (%) n=72	CNR n (%) n=14	p-value	RCR n (%) n=35	RNR n (%) n=51	p-value
<b>Lesion characteristics</b>						
Abscess	22 (30.5%)	1 (7.1%)	0.25	9 (25.7%)	14 (27.4%)	0.95
NME	15 (20.8%)	4 (28.5%)		8 (22.9%)	11 (21.5%)	
Abscess and NME	34 (47.2%)	10 (71.4%)		18 (51.4%)	26 (51.1%)	
Lymphadenopathy	66 (91.6%)	12 (85.7%)	0.48	33 (94.3%)	45 (88.2%)	0.34
Fistula	39 (54.1%)	8 (57.1%)	0.83	21 (60%)	26 (51%)	0.40
One quadrant	40 (55.6%)	8 (57.1%)	0.91	23 (65.7%)	25 (49%)	0.12
Multiple quadrants	32 (44.4%)	6 (42.9%)		12 (34.3%)	26 (51%)	
Retroareolar involvement	43 (59.7%)	7 (50%)	0.49	22 (30.6%)	28 (55%)	0.35

NME; non-mass enhancement, CCR; complete clinical response, CNR; clinical non-response, RCR; radiological complete response, RNR; radiological non-response.



There was a significant difference between the lesion diameter in the CCR and CNR groups on pre-treatment MRI ( $P=0.02$ ). The lesion diameter on pre-treatment MRI was smaller in the CCR group than in the CNR group. There was no significant difference between the lesion diameter in the RCR and RNR groups on pre-treatment MRI ( $P=0.056$ ). There was a significant difference between the lesion diameter on pre-treatment MRI and post-treatment MRI ( $P<0.001$ ). The lesion diameter was significantly reduced on pre-treatment MRI.

## DISCUSSION

MR examination has a very high sensitivity for IGM imaging. It can successfully demonstrate the extent of the disease and the involvement of the contralateral breast.<sup>17,18</sup> The most common lesions are masses with a rim-enhancing or heterogeneous enhancement pattern and non-mass enhancements (NMEs). Mass lesions display significant peripheral and heterogeneous contrast enhancement after the injection of contrast agent. Although the signal intensity varies depending on the protein content of the fluid in the mass lesions, these lesions appear hypointense on T1-weighted images and hyperintense on T2-weighted images.<sup>19</sup> According to the data of our study, the number of NME lesions was slightly higher than that of mass lesions, in line with previous studies.<sup>4,17-20</sup> We observed a higher rate of post-treatment abscess compared to NME lesions. This may be related to the organization of inflammation and its transformation into abscess formation after treatment.

IGM treatment is long-term and challenging. Optimal treatment is controversial. Medical and surgical methods are used for the treatment of IGM, the results of which are debatable. Bromocriptine, methotrexate, and corticosteroids are used in medical treatment.<sup>8,9</sup> Approximately 72% of patients have been reported to achieve complete recovery after an average of 4-10 months of treatment with steroids.<sup>4</sup> It has been suggested that steroids provide a reduction in lesion size, which can be preferred before surgery.<sup>11,16</sup> A meta-analysis reported fewer recurrences in patients who received both steroids and underwent surgery compared to those who underwent only surgery or received steroids alone. Therefore, treatment approaches combining steroid and surgical treatment are recommended.<sup>21</sup> The most important disadvantages of steroids are the prolonged duration of treatment and systemic side effects.<sup>4</sup>

Imaging findings affecting response to treatment are controversial. According to Atak *et al.*,<sup>22</sup> IGM patients with abscesses respond less to steroids. Sakurai *et al.*<sup>23</sup> reported that patients who developed fistulas and abscesses were more difficult to treat with

steroids. In a study by Altunkeser *et al.*, lesion characteristics and the presence of fistula were not associated with treatment success, similar to our results. However, they suggested that those with retroareolar involvement were more resistant to treatment.<sup>24</sup> Contrary to their results, we did not find a relationship between retroareolar involvement and treatment success.

In our study, CCR was more common in patients with a smaller lesion diameter, but there was no correlation between RCR and lesion size. This may be due to the fact that steroid therapy reduces the size of small lesions, making them difficult to detect clinically. Pre-treatment MRI findings including abscess, NME, fistula, and lymphadenopathy were not correlated with treatment response in our study. A previous study suggested that lesions with a size of less than 2cm healed in a shorter time with medical treatment.<sup>25</sup> We did not find a relationship between the number of involved quadrants, and treatment success. Factors affecting the response of IGM to steroid therapy have still not been understood and remain a mystery.

MRI is successful in the evaluation of response after steroid therapy. We noted radiological residual lesions in approximately half of the patients who achieved CCR. Clinical evaluation was not sensitive in detecting these residual lesions. On the other hand, MRI was successful in detecting residual lesions. Future studies are needed to understand whether residual lesions after CCR have clinical significance. Besides its benefits, the cost of and access to MRI should be considered. US is also useful in follow-up.<sup>15,23</sup> It can be preferred since it is a convenient and easily accessible tool.

### Limitations

The limitations of our study are its retrospective design and the small sample size.

## CONCLUSION

In conclusion, approximately half of the patients with CCR had residual lesions radiologically. MRI was helpful in the evaluation of the response of IGM patients to steroid therapy. A higher number of patients with smaller lesions before treatment achieved CCR. Apart from this, there was no correlation between pre-treatment MRI findings and clinical and radiological response.

## CONFLICTS OF INTERESTS

The authors and their institutions declare no conflicts of interest.

## FUNDING

There is no funding for this work.



## ETHICAL CONSIDERATIONS

This study was approved by our institutional review board (approval no: 202251422424). The requirement to obtain informed consent from the patients was waived.

## REFERENCES

1. Azizi A, Prasath V, Canner J, Gharib M, Sadat Fattahi A, Naser Forghani M, et al. Idiopathic granulomatous mastitis: Management and predictors of recurrence in 474 patients. *Breast J.* 2020;26(7):1358-1362. doi: 10.1111/tbj.13822.
2. Altintoprak F, Karakece E, Kivilcim T, Dikicier E, Cakmak G, Celebi F, et al. Idiopathic granulomatous mastitis: an autoimmune disease? *Sci World J* 2013;2013:148727. doi: 10.1155/2013/148727
3. Taylor GB, Paviour SD, Musaad S, Jones WO, Holland DJ. A clinicopathological review of 34 cases of inflammatory breast disease showing an association between corynebacteria infection and granulomatous mastitis. *Pathology.* 2003;35(2):109-119.
4. Pluguez-Turull CW, Nanyes JE, Quintero CJ, Alizai H, Mais DD, Kist KA, et al. Idiopathic Granulomatous Mastitis: Manifestations at Multimodality Imaging and Pitfalls. *Radiographics.* 2018;38(2):330-356. doi: 10.1148/rg.2018170095.
5. Tse GM, Poon CS, Ramachandram K, Ma TK, Pang LM, Law BK, et al. Granulomatous mastitis: a clinicopathological review of 26 cases. *Pathology* 2004;36(3):254-257. doi: 10.1080/00313020410001692602.
6. Akbulut S, Arikanoğlu Z, Senol A, Sogutcu N, Basbug M, Yeniaras E, et al. Is methotrexate an acceptable treatment in the management of idiopathic granulomatous mastitis?. *Arch Gynecol Obstet.* 2011;284(5):1189-1195. doi: 10.1007/s00404-010-1825-2.
7. Nikolaev A, Blake CN, Carlson DL. Association between hyperprolactinemia and granulomatous mastitis. *Breast J* 2016;22(2):224-231. doi: 10.1111/tbj.12552.
8. Uysal E, Soran A, Sezgin E. Granulomatous Mastitis Study Group. Factors related to recurrence of idiopathic granulomatous mastitis: what do we learn from a multicentre study? *ANZ J Surg.* 2018;88(6):635-639. doi: 10.1111/ans.14115.
9. Mizrakli T, Velidedeoglu M, Yemisen M, Mete B, Kilic F, Yilmaz H, et al. Corticosteroid treatment in the management of idiopathic granulomatous mastitis to avoid unnecessary surgery. *Surg Today.* 2015;45(4):457-465. doi: 10.1007/s00595-014-0966-5.
10. Skandarajah A, Marley L. Idiopathic granulomatous mastitis: a medical or surgical disease of the breast?. *ANZ J Surg.* 2015;85(12):979-982. doi: 10.1111/ans.12929.
11. Akcan A, Öz AB, Dogan S, Akgün H, Akyüz M, Ok E, et al. Idiopathic granulomatous mastitis: Comparison of wide local excision with or without corticosteroid therapy. *Breast Care.* 2015;9(2):111-115. doi: 10.1159/000360926.
12. Akin M, Karabacak H, Esendağlı G, Yavuz A, Gültekin S, Dikmen K, et al. Coexistence of idiopathic granulomatous mastitis and erythema nodosum: successful treatment with corticosteroids. *Turk J Med Sci.* 2017;47(5):1590-1592. doi: 10.3906/sag-1611-100.
13. Altintoprak F, Kivilcim T, Yalkin O, Uzunoglu Y, Kahyaoglu Z, Dilek ON. Topical Steroids Are Effective in the Treatment of Idiopathic Granulomatous Mastitis. *World J Surg.* 2015;39(11):2718-2723. doi: 10.1007/s00268-015-3147-9.
14. Deng JQ, Yu L, Yang Y, Feng XJ, Sun J, Liu J, et al. Steroids administered after vacuum-assisted biopsy in the management of idiopathic granulomatous mastitis. *J Clin Pathol.* 2017;70(10):827-831. doi: 10.1136/jclinpath-2016-204287.
15. Gunduz Y, Altintoprak F, Tatli Ayhan L, Kivilcim T, Celebi F. Effect of topical steroid treatment on idiopathic granulomatous mastitis: clinical and radiologic evaluation. *Breast J.* 2014;20(6):586-591. doi: 10.1111/tbj.12335.
16. Karanlık H, Ozgur I, Simsek S, Fathalizadeh A, Tukenmez M, Sahin D, et al. Can Steroids plus Surgery Become a First-Line Treatment of Idiopathic Granulomatous Mastitis?. *Breast Care (Basel).* 2014;9(5):338-342. doi: 10.1159/000366437.
17. Fazio RT, Shah SS, Sandhu NP, Glazebrook KN. Idiopathic granulomatous mastitis: imaging update and review. *Insights Imaging.* 2016;7(4):531-539. doi:10.1007/s13244-016-0499-0
18. Oztekin PS, Durhan G, Nercis Kosar P, Erel S, Hucumenoglu S. Imaging Findings in Patients with Granulomatous Mastitis. *Iran J Radiol.* 2016;13(3):e33900. doi:10.5812/iranjradiol.33900
19. Poyraz N, Emlik GD, Batur A, Gundes E, Keskin S. Magnetic resonance imaging features of idiopathic granulomatous mastitis: a retrospective analysis. *Iran J Radiol.* 2016;13(3):e20873. doi: 10.5812/iranjradiol.20873.
20. Aslan H, Pourbagher A, Colakoglu T. Idiopathic granulomatous mastitis: magnetic resonance imaging findings with diffusion MRI. *Acta Radiol.* 2016;57(7):796-801. doi: 10.1177/0284185115609804.
21. Godazandeh G, Shojaee L, Alizadeh-Navaei R, Hessami A. Corticosteroids in idiopathic granulomatous mastitis: a systematic review and meta-analysis. *Surg Today.* 2021;51(12):1897-1905. doi: 10.1007/s00595-021-02234-4.
22. Atak T, Sagioglu J, Eren T, Ali Özemir I, Alimoglu O. Strategies to treat idiopathic granulomatous mastitis: retrospective analysis of 40 patients. *Breast Dis.* 2015;35(1):19-24. doi: 10.3233/BD-140373.



23. Sakurai K, Fujisaki S, Enomoto K, Amano S, Sugitani M. Evaluation of follow-up strategies for corticosteroid therapy of idiopathic granulomatous mastitis. *Surg Today*. 2011;41(3):333-337. doi: 10.1007/s00595-009-4292-2.
24. Altunkeser A, Arslan FZ, Eryılmaz MA. Magnetic resonance imaging findings of idiopathic granulomatous mastitis: can it be an indirect sign of treatment success or fail? *BMC Med Imaging*. 2019;19(1):94. doi: 10.1186/s12880-019-0397-2.
25. Aydın HO, Baykal A, Konan A, Kaynaroğlu V. Idiopathic granulomatous mastitis: factors influencing recovery and recurrence. *The European Research Journal*, 2019 5(5), 768-775. doi: 10.18621/eurj.424016.

#### How to Cite This Article

**Rona G, Arifoğlu M, Çetin K, Fikri Kündeş M. The Value of Dynamic Contrast-Enhanced MRI in Predicting the Response of Idiopathic Granulomatous Mastitis to Steroid Therapy and Comparison of Clinical and Radiological Outcomes. Arch Breast Cancer. 2023; 10(2): 124-30.**

Available from: <https://www.archbreastcancer.com/index.php/abc/article/view/658>