



DOI: 10.32768/abc.202310181-85



## B3 Lesions of the Breast: Two Year Retrospective Analysis of 4478 Cases Carried out in a Single Centre in the UK

 Zaibun Nisa\*<sup>a</sup> , Sheena Bajaj<sup>a</sup> 
<sup>a</sup>Department of Histopathologist, Queen's Hospital, Romford, London, UK

## ARTICLE INFO

**Received:**  
15 September 2022  
**Revised:**  
11 October 2022  
**Accepted:**  
2 November 2022

**Keywords:**

B3 lesions, upgrade rate, national standards.

## ABSTRACT

**Background:** B3 category mainly consists of lesions that provide benign histology on core biopsy, but either are known to show heterogeneity or have increased risk of associated malignancy. However, the level of risk is very different for different entities. All the cases should be looked for atypia.

The objective of this study is to compare various B3 lesions in two audits, to calculate the median rate and upgrade rates (the rate at which they turn into malignancy on subsequent excision) for different B3 lesions and to compare them with the national standards and published literature. The study aims to see whether vacuum assisted excision or surgical excision has been done in such lesions.

**Methods:** This is a retrospective study and encompasses two audits done in 2017-18 and 2020-21 at Queen's hospital, Barking, Havering and Redbridge NHS trust. A total of 4478 cases were reviewed and 206 cases were graded as B3 on core biopsy.

**Results:** Overall, 113 cases were graded as B3 in 2020-21 and 93 cases in 2017-18 giving the median rate of 5% and the overall upgrade rate of 12%. Intraductal papilloma was the most commonly seen lesion in both audits. Also, 31 cases underwent vacuum assisted excision and 62 cases underwent surgical excision, with 38 cases not undergoing further excision.

**Conclusion:** The median rate was within the 'preferred median rate'- 4.5-8.5% and the upgrade rate was comparable (16.57%) with those of National Breast Cancer screening audit, 2016-2019. The type of excision for various lesions was in line with the criteria stated by the Royal College of Pathologists. The lesions which were not excised did not turn into malignancy on follow-up.

Copyright © 2022. This is an open-access article distributed under the terms of the [Creative Commons Attribution-Non-Commercial 4.0 International License](https://creativecommons.org/licenses/by-nc/4.0/), which permits copy and redistribution of the material in any medium or format or adapt, remix, transform, and build upon the material for any purpose, except for commercial purposes.

## INTRODUCTION

Core biopsies of breast are graded from B1-B5, as proposed by the United Kingdom Breast screening program for reporting core biopsies.<sup>1</sup> B1 indicates normal tissue, whether or not breast glandular tissue is included; B2 refers to benign diagnosis; B4 refers to lesions which are suspicious and preclude a definitive diagnosis due to lack of appropriate sample;

B5 is divided into B5a (DCIS and pleomorphic LCIS) and B5b (invasive tumors, lymphomas and metastatic tumors). There is another category called B5c, where a definitive diagnosis cannot be made of malignancy due to lack of surrounding stroma.

B3 lesions are lesions of uncertain malignant potential and include a vast array of lesions with heterogenous morphology and behavior. The level of risk to turn into malignancy is different for different lesions. However, all the cases should be looked for atypia as the risk of malignancy is relatively high for AIDEP (Atypical intraductal epithelial proliferation).

## \*Address for correspondence:

Zaibun Nisa, M.D.,  
 Department of Histopathologist, Queen's Hospital,  
 Romford, London, UK  
 Tel: +443304004333  
 Email: Zaibun.nisa1@nhs.net



B3 lesions are usually managed by Vacuum assisted biopsy (VAB)/vacuum assisted excision (VAE) or surgical excision.

VAB/VAE is usually done for AIDEP, FEA (Flat epithelial atypia), classical lobular neoplasia, papilloma without epithelial atypia, radial scar with or without epithelial atypia and mucocele – like lesions with or without epithelial atypia.

Surgical excision is recommended for papillomas with epithelial atypia, cellular fibroepithelial lesions, spindle cell lesions; vascular lesions which are difficult to classify, microglandular adenosis and adenomyoepithelioma.<sup>2</sup>

The lesions should also be looked for the presence of calcification and corroborated with the radiological findings, to confirm that the lesion has been sampled.

The objectives of this audit are to compare the number of various B3 lesions with the previous audit, to investigate the median rate of B3 biopsies and to compare it with national standards, to determine the upgrade rate of B3 lesions and to compare it with national standards and published literature, and to see whether vacuum assisted excision or surgical excision has been done for B3 lesions.

## METHODS

A retrospective Winpath search was done, which is a system for reporting cases in most centres in the UK. Core biopsies which were graded from B1-B5 were taken as “total number of biopsies” and biopsies reported as B3 were further assessed for this audit. The study was done in Queen’s hospital, Barking, Havering and Redbridge NHS trust from August 2020 to July 2021 and from June 2017 to May 2018.

### Exclusion criteria

Since the following types of specimens do not fall into B-categories, they were not included for this study: Breast skin biopsies, VAC Excisions, Duct excisions, Axillary Lymph node biopsies

- Median rate: Number of B3 biopsies / total number of biopsies x 100
- Upgrade rate: Number of B3 lesions which turn malignant on subsequent excision<sup>3</sup>

## RESULTS

Total number of breast biopsies (2020-21): 2213; (2017-18): 2265

B3 categorization of biopsies (2020-21): 113; (2017-18): 93

B3 lesion median rate (2020-21): 5%; (2017-18): 4.1%.

The following table shows the number of B3 lesions in the two audits:

According to the results, 23 cases were associated with atypia in 2020-21 and 15 cases in 2017-18. Radiological calcification was seen in 22 cases in 2020-21 and 32 cases in 2017-18.

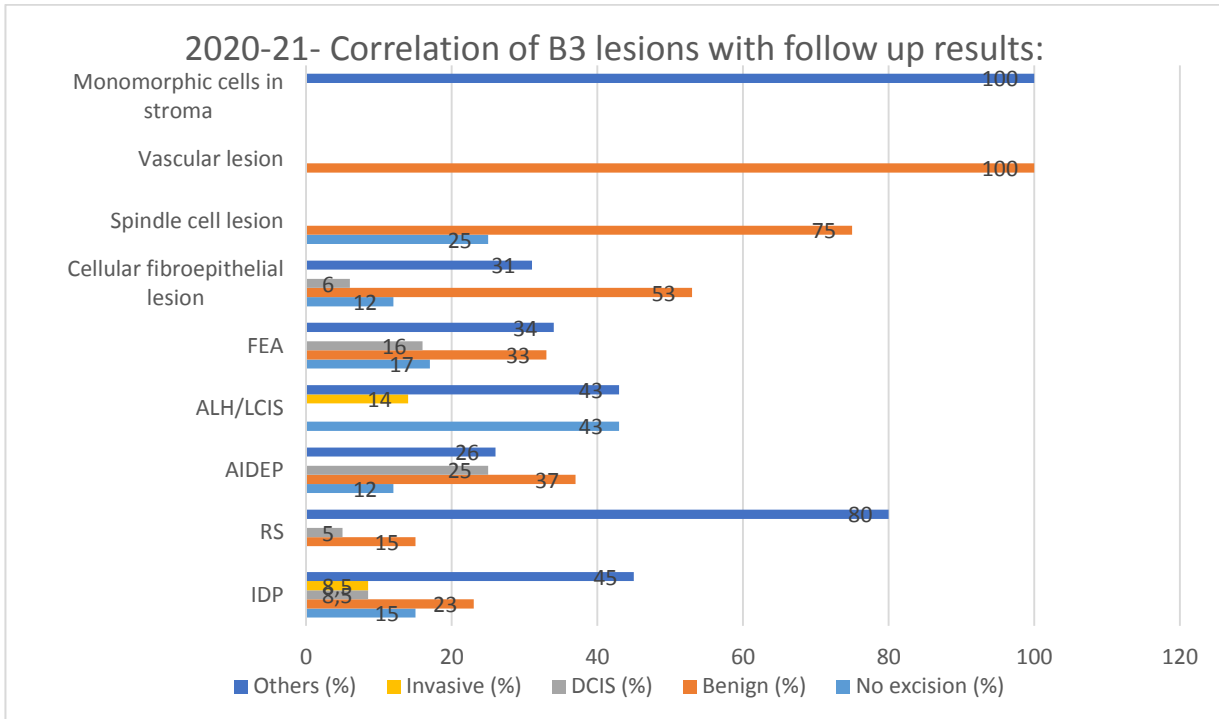
**Table 1.** Number of B3 lesions in the two audits

B3 diagnosis	2020-21	2017-18
Intraductal papilloma	47	50
Radial scar	20	21
Atypical intraductal epithelial proliferation (AIDEP)	8	6
Atypical lobular hyperplasia (ALH) / lobular carcinoma in situ (LCIS)	7	9
Cellular fibroepithelial lesion	17	4
Spindle cell lesion	4	1
Pleomorphic/Monomorphic cells in stroma	1	1
Flat epithelial atypia	6	1
Vascular lesion	2	0
Extracellular mucin in stroma	1	-
Total	113	93

Figures 1 and 2 show the number of B3 lesions which have either upgraded to ‘malignant’ or downgraded to ‘benign’ on subsequent excisions in the two audits. It also shows cases which did not have any excision. “Others” indicate cases which remained the same following excision.

With reference to the Figures 1 and 2, the following results were drawn: 8/47 (17%) cases of IDP showed DCIS (4) and invasion (4) in 2020-21 whereas 4/50 (8%) of IDP cases showed DCIS and invasive carcinoma in 2017-18. Also, 1/20 (5%) cases of radial scar showed DCIS in 2020-21, whereas none of the cases showed DCIS or invasive malignancy in 2017-18. In addition, 1/16 (6%) case of cellular fibroepithelial lesion showed DCIS on excision in 2020-21 and none of the cases showed in situ or invasive malignancy in 2017-18.

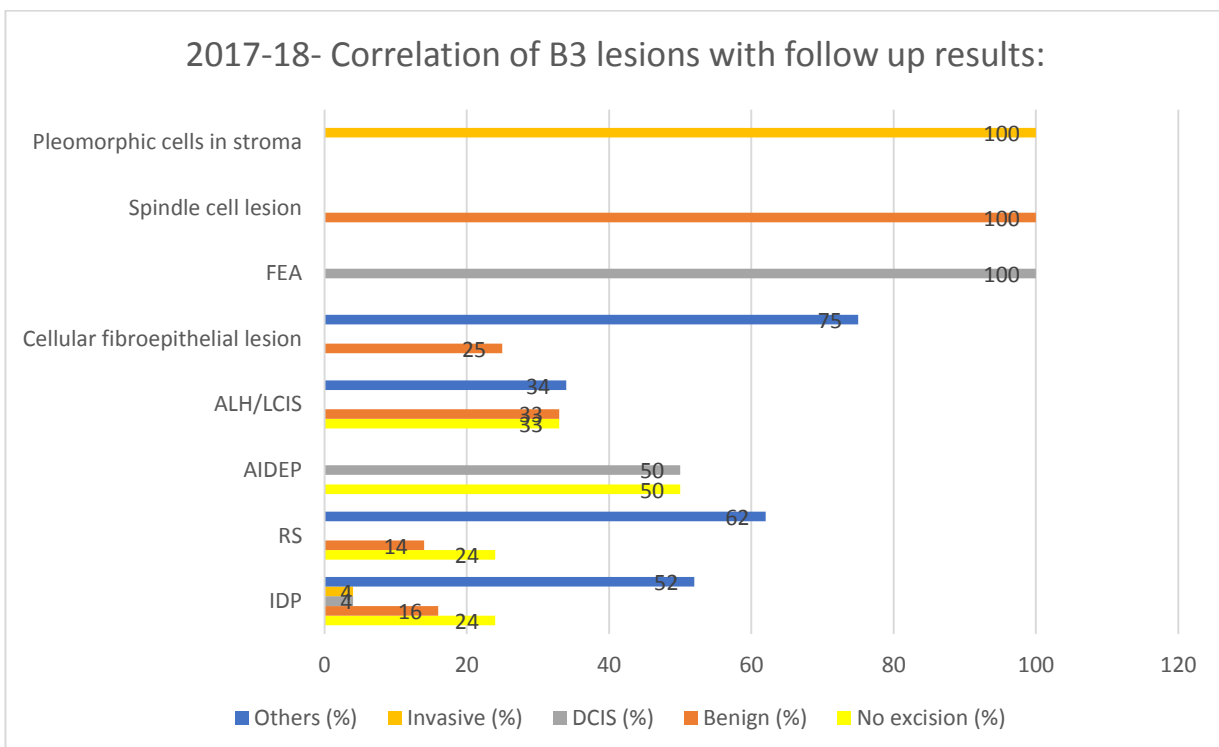
However, 5/16 (31%) cases showed benign phyllodes tumor in current audit and 3/4 (75%) cases showed benign phyllodes tumor on excision in previous audit. Also, 2/8 (25%) cases of ADH showed DCIS on excision in 2020-21 as compared to 2017-18, where 3/6 (50%) cases showed DCIS. Moreover, 1/7 (14%) cases of ALH showed invasive lobular carcinoma with LCIS on excision in 2020-21, whereas none of the cases showed invasion in 2017-18. Also, 1/6 (16%) cases of flat epithelial atypia showed DCIS on excision in 2020-21, compared to 2017-18, where 1/1 (100%) case showed DCIS on excision. None of the spindle cell lesions showed in situ or invasive malignancy in either of the audits.



**Figure 1.** Correlation of B3 lesions with follow-up results (2020-21). FEA: Flat epithelial atypia; ALH/LCIS: Atypical lobular hyperplasia / lobular carcinoma in situ; AIDEP: Atypical intraductal epithelial proliferation; RS: Radial scar; IDP: Intraductal papilloma; DCIS: Ductal carcinoma in situ.

The vascular lesions identified in 2020-21 were benign on excision. Pleomorphic cells in stroma identified in previous audit showed invasive

malignancy on excision whereas no excision was performed for monomorphic cells in stroma of current audit.



**Figure 2.** Correlation of B3 lesions with follow-up results (2017-18). FEA: Flat epithelial atypia; ALH/LCIS: Atypical lobular hyperplasia / lobular carcinoma in situ; AIDEP: Atypical intraductal epithelial proliferation; RS: Radial scar; IDP: Intraductal papilloma; DCIS: Ductal carcinoma in situ.



## DISCUSSION

As per National breast cancer screening services, England audit (2016-2019)<sup>4</sup>, the preferred rate is 4.5-8.5%, and the minimum range is 4-9%. In our study, B3 lesion median rate in 2020-21 was 5%; and in 2017-18, 4.1%.

The overall upgrade rate was 12%. Lesions with atypia, 4%; lesions without atypia, 8%. As per England National breast screening services,<sup>5</sup> the overall upgrade rate was 16.57%: 29% for lesions with atypia and 13% for lesions without atypia.

The upgrade rate for AIDEP was vast and varied from 18-87%.<sup>6</sup> In our audit, the overall upgrade rate varied between in 25-50% in 2017-18 and 2020-21.

In a systematic review by Verschuur-Maes *et al.*,<sup>7</sup> 57 (17%) of FEA had associated carcinoma on excision. The upgrade rate was 16% for FEA in 2020-21 and 100% (1/1 case) in 2017-18 in our audit.

In our audit, 2/20 (10%) cases of radial scars showed DCIS in 2020-21, out of which only one case of radial scar had atypia on biopsy. None of the cases of radial scar showed malignancy in 2017-18.

For papillary lesions, the chance of malignancy is low (9%<sup>8</sup> and 13.2%<sup>9</sup>) in the absence of atypia; when atypia is present, the upgrade rate is much higher (36%<sup>8</sup> and 47.8%<sup>9</sup>). In our audit, the upgrade rate was 17% in 2020-21 and 8% in 2017-18. The chance of malignancy was 16% with atypia and 7% without atypia. So, the rate was higher when IDP was associated with atypia. This was comparable with the published literature.

With regard to cellular fibroepithelial lesions, the “upgrade rate” is the proportion of lesions that are phyllodes tumour on excision; the figures in the literature show wide variation even in the larger series between 16%<sup>10</sup> and 76%.<sup>11</sup> Also, 5/16 (31%) cases showed benign phyllodes tumour in the current audit and 3/4 (75%) cases showed benign phyllodes tumour on excision in the previous audit.

## REFERENCES

1. Ellis IO, Humphreys S, Michell M, Pinder SE, Wells CA, Zakhour HD; UK National Coordinating Committee for Breast Screening Pathology; European Commission Working Group on Breast Screening Pathology. Best Practice No 179. Guidelines for breast needle core biopsy handling and reporting in breast screening assessment. *J Clin Pathol*. 2004 Sep;57(9):897-902. doi: 10.1136/jcp.2003.010983.
2. Pinder SE, Shaaban A, Deb R, Desai A, Gandhi A, Lee AHS, et al. NHS Breast Screening multidisciplinary working group guidelines for the diagnosis and management of breast lesions of uncertain malignant potential on core biopsy (B3 lesions). *Clin Radiol*.

Vacuum assisted biopsy and excisions were carried out in 31 cases and surgical excisions were done in 62 cases. Most of the excisions were in line with the criteria laid out by Royal College of Pathologists for B3 lesions.<sup>2</sup> No excision was done in 38 cases. Majority of the lesions were IDP and none of them upgraded to malignancy on follow-up.

## CONCLUSION

B3 lesion median rate was within the preferred median rate as per National breast cancer screening audit. The overall upgrade rate for B3 lesions was 12% which is comparable with the national standards (16.57%). However, lesions with atypia had a lower upgrade rate than lesions without atypia. This was mainly due to the population coverage for this centre where cases of atypical intraductal epithelial proliferation (AIDEP) were comparably lower than the national statistics.

The upgrade rate was highest for AIDEP followed by FEA; and was comparable with the published literature. However, only seven cases of FEA were seen in the two audits, out of which two cases were upgraded to DCIS on excision. The type of excision for various lesions was in line with the criteria stated by the Royal College of Pathologists. The lesions which were not excised did not turn into malignancy on follow-up.

## CONFLICT OF INTEREST

None.

## ACKNOWLEDGEMENTS

We extend our gratitude to our colleagues for conducting an audit in 2017-18.

## ETHICAL CONSIDERATIONS

The audit is registered with the trust and meets the ethical standards of the trust.

2018 Aug;73(8):682-692. doi: 10.1016/j.crad.2018.04.004.

3. Girardi V, Guaragni M, Ruzzenenti N, Palmieri F, Fogazzi G, Cozzi A, *et al*. B3 Lesions at Vacuum-Assisted Breast Biopsy under Ultrasound or Mammography Guidance: A Single-Center Experience on 3634 Consecutive Biopsies. *Cancers (Basel)*. 2021 Oct 29;13(21):5443. doi: 10.3390/cancers13215443.
4. National breast screening pathology audit, updated September 2021. Available from: <https://www.gov.uk/government/publications/national-breast-screening-pathology-audit/national-breast-screening-pathology-audit>



5. Sharma N, Cornford E, Cheung S, Price H, Kearins O. The impact of vacuum-assisted excision in the management of indeterminate B3 lesions in the NHS Breast Screening Programme in England. *Clin Radiol*. 2021 Jun; 76(6):470.e23-470.e29. doi: 10.1016/j.crad.2021.01.021.
6. Yu YH, Liang C, Yuan XZ. Diagnostic value of vacuum-assisted breast biopsy for breast carcinoma: a meta-analysis and systematic review. *Breast Cancer Res Treat*. 2010 Apr;120(2):469-79. doi: 10.1007/s10549-010-0750-1.
7. Verschuur-Maes AH, van Deurzen CH, Monninkhof EM, van Diest PJ. Columnar cell lesions on breast needle biopsies: is surgical excision necessary? A systematic review. *Ann Surg*. 2012 Feb;255(2):259-65. doi: 10.1097/SLA.0b013e318233523f.
8. Rakha EA, Lee AH, Jenkins JA, Murphy AE, Hamilton LJ, Ellis IO. Characterization and outcome of breast needle core biopsy diagnoses of lesions of uncertain malignant potential (B3) in abnormalities detected by mammographic screening. *Int J Cancer*. 2011 Sep 15;129(6):1417-24. doi: 10.1002/ijc.25801.
9. Bianchi S, Bendinelli B, Saladino V, Vezzosi V, Brancato B, Nori J, et al. Non-malignant breast papillary lesions—B3 diagnosed on ultrasound-guided 14-gauge needle core biopsy: analysis of 114 cases from a single institution and review of the literature. *Pathol Oncol Res*. 2015 Jul;21(3):535-46. doi: 10.1007/s12253-014-9882-7.
10. El-Sayed ME, Rakha EA, Reed J, Lee AH, Evans AJ, Ellis IO. Predictive value of needle core biopsy diagnoses of lesions of uncertain malignant potential (B3) in abnormalities detected by mammographic screening. *Histopathology*. 2008 Dec;53(6):650-7. doi: 10.1111/j.1365-2559.2008.03158.x.
11. Abdulcadir D, Nori J, Meattini I, Giannotti E, Boeri C, Vanzi E, et al. Phyllodes tumours of the breast diagnosed as B3 category on image-guided 14-gauge core biopsy: analysis of 51 cases from a single institution and review of the literature. *Eur J Surg Oncol*. 2014 Jul;40(7):859-64. doi: 10.1016/j.ejso.2014.02.222.

#### How to Cite This Article

**Nisa Z, Bajaj S. B3 Lesions of the Breast: Two Year Retrospective Analysis of 4478 Cases Carried out in a Single Centre in the UK. Arch Breast Cancer. 2023; 10(1): 81-85.**

Available from: <https://www.archbreastcancer.com/index.php/abc/article/view/633>