



DOI: 10.32768/abc.202293SI314-318



Idiopathic Granulomatous Mastitis with Incidental Lobular Carcinoma In Situ: A Case Report

 Mahsa Tavakol^a, Saba Alvand^b , Farid Amouzadeh Ardalan^c , Abdolali Assarian*^a
^aDepartment of Surgery, Tehran University of Medical Sciences, Tehran, Iran

^bFaculty of Medicine, Tehran University of Medical Sciences, Tehran, Iran

^cDepartment of Pathology, Tehran University of Medical Sciences, Tehran, Iran

ARTICLE INFO

ABSTRACT

Received:
31 May 2022
Revised:
13 June 2022
Accepted:
16 June 2022

Keywords:

Breast, Granulomatous mastitis, Lobular carcinoma in situ, benign breast disease

Background: Lobular carcinoma in situ (LCIS) is a type of lobular neoplasia within the terminal duct lobular unit, involving more than half of acini. It is mostly diagnosed incidentally and although it is not a malignant lesion, it has an association with malignancy in the future. Idiopathic granulomatous mastitis (IGM) is a benign granulomatous disease with few simultaneous reports of malignant lesions in the literature. In this case report, we present a case with LCIS and IGM in a single breast.

Case presentation: A 35-year-old female presented to the breast clinic with complaints of pain and a palpable mass in the right breast. The past medical history, habitual history, drug history, and family history of cancer were negative. Physical examinations showed a palpable mass in the right breast without nipple discharge and retraction and lymphadenopathy and the left breast was intact. Breast imaging showed a right UOQ mass. A core needle biopsy was performed showing LCIS and IGM on the right side with a positive cytoplasmic reaction for P120 catenin. E-cadherin was negative in LCIS. P63 and CK5/6 immunostainings revealed the presence of myoepithelial cells around ductal and glandular structures. The patient developed erythema nodosum at the time of diagnosis. She was put on prednisolone 50 mg per day and NSAID, and after improvement was maintained on 25 mg daily prednisolone for about 7 months, combined with 3 months of hydroxychloroquine 200 mg twice a day. At the 12-month follow-up, both breasts were completely normal in the physical examination without any mass or skin changes and the right breast mass decreased in size.

Conclusion: Radiologic findings of IGM can be suggestive of other possible causes and silent etiologies like the primary phase of breast cancer and LCIS should not be overlooked.

Copyright © 2022. This is an open-access article distributed under the terms of the [Creative Commons Attribution-Non-Commercial 4.0 International License](https://creativecommons.org/licenses/by-nc/4.0/), which permits copy and redistribution of the material in any medium or format or adapt, remix, transform, and build upon the material for any purpose, except for commercial purposes.

INTRODUCTION

Idiopathic granulomatous mastitis (IGM) first described by *Kessler et al.* in 1972, is a benign breast disease with unknown etiology.^{1,2} IGM is rare but has been reported in the middle east countries like Iran

and Turkey more than in other countries, where the mean age of the reported cases was mostly between 33.5-36 years.^{3,4} Diagnosis is made by the combination of clinical presentations and imaging and confirmation by pathologic features.^{3,5,6}

Lobular carcinoma in situ (LCIS) is a type of lobular neoplasia within the terminal duct lobular unit, involving more than half of acini.⁷ Although LCIS has characteristics of a malignant lesion in

***Address for correspondence:**

Abdolali Assarian, M.D.,
 Department of Surgery, Tehran University of Medical Sciences, Tehran, Iran
 Tel: XXX
 Email: aliassarian@yahoo.com



histopathology, the risk of progression is lower than expected. However, it is known as a potential risk factor for invasive breast cancer, and close clinical surveillance is recommended.^{8,9} This case report presents a patient diagnosed with IGM and LCIS simultaneously for the first time.

CASE PRESENTATION

Our patient is a 35-year-old woman who presented to the breast clinic of Imam Khomeini Hospital Complex (IKHC), Tehran University of Medical Sciences (TUMS) with a chief complaint of pain and a small palpable mass in her right breast in the last month and a small palpable mass in her left breast for the last 6 years. She did not report any nipple discharge or breast ulcer. She was married and had two pregnancies and a history of 28 months of breastfeeding. There was no problem in her past medical history and she did not use any medications or hormonal contr. She denies any family history of breast or ovarian cancer in her first or second-degree relatives. On physical examination, her breasts were huge and there was a large hard 8cm palpable mass in the upper outer quadrant (UOQ) of the right breast without any erythema or skin retraction. The left breast and bilateral axillary regions were intact. The blood tests including complete blood cell and liver function test and ESR were normal. The tuberculosis skin test (PPD) was negative. She underwent breast ultrasonography (US) and a right breast biopsy 50 days before referral. In the breast US, a diffuse heterogenous ill-defined irregular area with internal microcalcification and skin thickening (BIRADS 4b) was noted in the right UOQ. There was also a well-defined hypochoic mass in the left breast at 12 o'clock (BIRADS 3). Through the breast MRI, she had fibroglandular and heterogeneous dense breast with breast composition of type C. In the right breast, there was an asymmetrical parenchymal thickening with multiple round to oval-shaped and lobulated rim enhanced masses measuring 14 mm to 35 mm in UOQ. Also, extensive asymmetrical non-mass enhancement of about 140*80*60 mm was noted in UOQ, and the lateral part of the right breast extended to the retro areolar region with a type 3 dynamic curve. All findings in the right breast were suspicious of extensive ductal carcinoma in situ (DCIS) with invasive foci; however, atypical mastitis could be considered in the differential diagnosis (BIRADS 4c). In the left breast upper inner quadrant (UIQ), there was a 23*16mm multilobulated heterogeneously enhancing mass with dark internal septa and type 2-3 dynamic curves (BIRADS 4a). The bilateral axilla contained enlarged lymph nodes with mild cortical thickening. In mammography, there was a large hypo to hetero echoic mass measuring about 150 mm in the

lateral part of the right breast without any microcalcification or distortion which was enhanced in MRI.

A core needle biopsy (CNB) of the right breast was performed. The pathologic report was compatible with fibroepithelial neoplasm in favor of fibroadenoma with the presence of moderate usual ductal hyperplasia (UDH) and no evidence of malignancy or microcalcification in the specimen. Due to the difference in imaging findings and pathology report, bilateral mammography, US and MRI were reviewed in the breast imaging center, IKHC, TUMS. Regarding the imaging, a phyllodes tumor could be suggested for the solid mass in both breasts (BIRADS 4a). According to discordance between imaging and pathologic results, a core needle biopsy of each breast was done again.

The second pathology report showed a benign fibroepithelial lesion consistent with fibroadenoma on the left side. On the right side, it revealed breast tissues with LCIS, UDH, lobulocentric and confluent granulomatous inflammation accompanied with a mixed inflammatory infiltrate, microabscess formation, and focal myxoid change and hyalinization in stroma associated with fibroadenomatoid hyperplasia without any microcalcification. No acid-fast bacilli or fungal elements were identified on Ziehl Neelsen and Gomori methenamine silver stainings. Immunostaining for P120 catenin and E-cadherin confirmed the lobular nature of intralobular epithelial proliferations. Immunostaining for P63 and CK5/6 highlighted the myoepithelial cells around glandular and ductal structures. CK5/6 immunostaining demonstrated a mosaic pattern of staining in intraductal proliferations supporting UDH (Figure 1).

The histopathologic changes were compatible with IGM. Although special stains did not show any evidence of infectious agent, further clinicolaboratory investigations for exclusion of infections were recommended. In contrast to sarcoidosis which showed naked granulomas in both intralobular and interlobular stroma, the granulomas were lobulocentric and associated with mixed inflammation in this case. The clinical presentation was not compatible with sarcoidosis either. After the second biopsy, she presented bilateral lower extremities erythema nodosa and discharge from the right-side biopsy orifice.

She was presented in a multidisciplinary team (MDT) meeting. According to MDT recommendation, IGM with incidental LCIS finding was confirmed with anti-inflammatory treatment with corticosteroid and NSAID (Naproxen, 500mg, twice daily) under close follow-up.

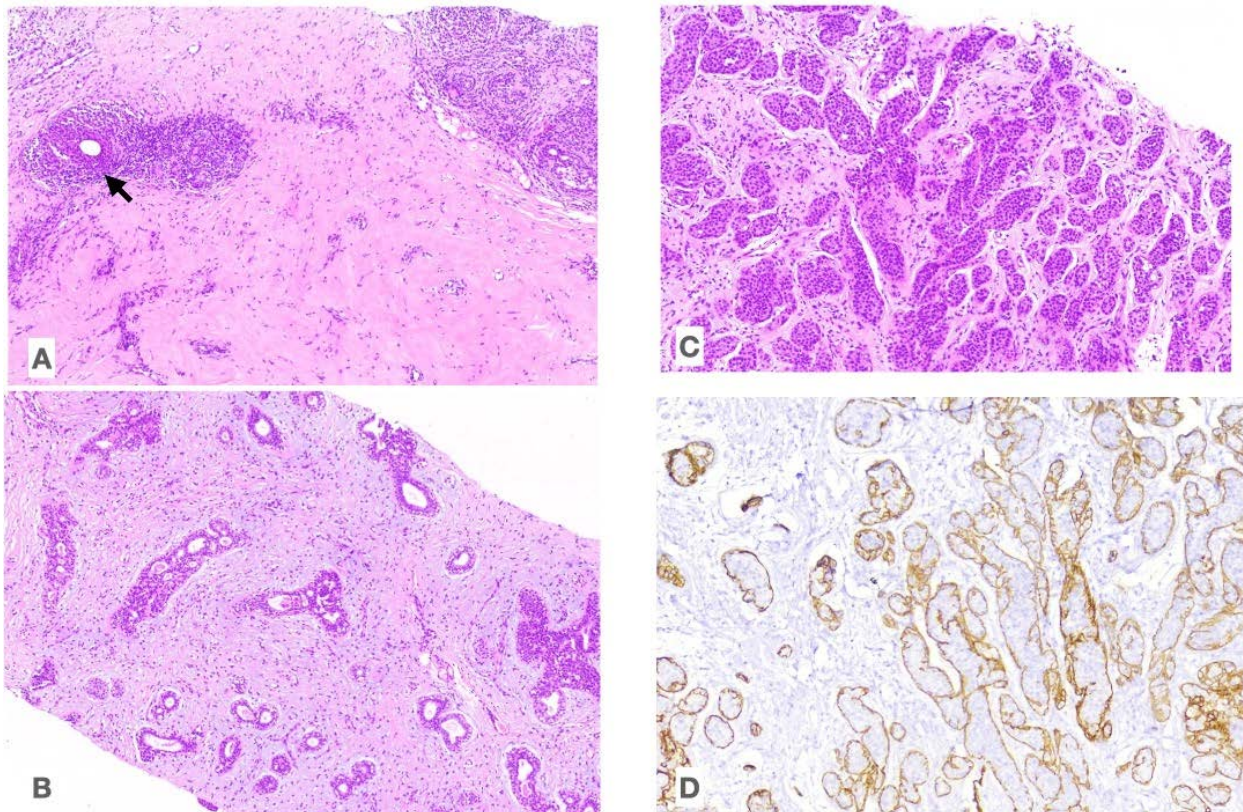


Figure 1. A. The photomicrograph shows the lobulocentric infiltration of mixed inflammatory cells with granulomatous reaction (Black arrow), H&E stain, 100x. B. Usual ductal hyperplasia is seen in another area, H&E stain, 100x. C. Lobular carcinoma in situ. Note the lobules that are filled with proliferated cells, H&E stain, 100x. D. Immunostaining for E. cadherin demonstrates absence of staining in the proliferated interlobular cells. E. cadherin immunostain, 100x.

Also, a consultation with a rheumatologist was requested.

She was started on high-dose prednisolone (50 mg daily). The erythema nodosum and the breast pain disappeared under treatment and the right breast mass became smaller and firm. We started to taper the prednisolone, and when the dose reached 20mg, all the changes reversed. Therefore, we could control her symptoms by changing her treatment protocol to 25 mg daily prednisolone for about 7 months, combined with 3 months of hydroxychloroquine 200 mg twice a day. Then we tapered the prednisolone and discontinued it.

She was evaluated every month in the breast clinic and a follow-up with the US was done every 6 months. In the last month, after a year since she came to our clinic, her breasts were completely normal in the physical examination without any mass or skin changes and her right breast mass decreased in size to 66*17 mm. Her left breast mass had no change in the latest surveillance imaging. Therefore, she underwent a vacuum-assisted biopsy of the right breast mass that was identified in the last MRI but not palpable in the physical examination. Based on the histopathology report, there was not any malignancy or granulomatous inflammation but only fibrocystic

changes with UDH and columnar cell changes and adenosis were reported.

DISCUSSION

Idiopathic granulomatous mastitis (IGM) is a rare benign inflammatory breast disease that was first described by Kessler in 1972.¹ Most patients are reported from the middle east and are of childbearing age with a mean age of 33.5-36 years.^{3,10} The exact etiology of IGM is obscure, although it is thought to be immunologically mediated and characterized by the presence of noncaseating granulomas confined to the breast lobules and neutrophilic infiltration.¹¹ It has a chronic relapsing course usually presented with a breast mass with or without mastalgia, skin thickening, fistula, or sinus tract formation.^{3,10,12} Also, some other symptoms like arthralgia and erythema nodosum are reported.^{13,14} The diagnosis of IGM is challenging and based on excluding other benign inflammatory and malignant breast lesions. The imaging criteria are characteristic but not diagnostic and have to be confirmed by histopathologic findings in core needle specimens.^{3-5,11,15}

On the other hand, classic lobular carcinoma in situ (LCIS) is commonly a silent disease and found



incidentally. It is a noninvasive proliferation of lobular cells within a terminal-duct lobular unit and involves multiple lobules.^{16,17} LCIS is a high-risk breast lesion that is diagnosed through breast biopsies incidentally in many cases.^{8,18} Patients with incidental findings of LCIS on core needle biopsies especially those without imaging findings have a small risk of progression, and surgical excision is not usually considered.^{9,16}

In this study, we presented a patient with a simultaneous diagnosis of IGM and LCIS. Both diseases mostly involve women of childbearing age; however, pleomorphic and florid LCIS commonly occur after menopause.⁷ To the best of our knowledge, this is the first case report presenting simultaneous LCIS and IGM in a patient. However, two case reports have reported simultaneous ductal carcinoma in situ (DCIS) and IGM.^{19,20} The first one was a 35-year-old woman presenting with right breast swelling.²⁰ She was diagnosed with IGM after CNB and because of not responding to treatment, she underwent excisional surgery and was diagnosed with DCIS in the second pathology assessment and immunohistochemical staining. The second case was a 44-year-old woman with a complaint of left breast swelling and a painful mass. She received antibiotics and as she did not respond to them, she underwent a biopsy and was diagnosed with IGM and DCIS.¹⁹ Although IGM and LCIS were in the same breast in our study and the previous studies on DCIS, it is possible to have IGM in one breast and an invasive carcinoma or carcinoma in situ in the other breast.²¹

The relationship between inflammation and malignancy has always been interesting to scientists and clinicians. The inflammation can be triggered by infection or autoimmune diseases; however, the exact biologic relationship between IGM and malignant lesions is not clarified due to the small number of

cases. One of the leading factors of malignancy is DNA damage due to prolonged inflammation.²² DNA methylation, microRNA dysregulation, and sharing responsible genes in both autoimmunity and carcinogenicity constitute other possible reasons.^{23,24}

According to the immunologic etiology of IGM, many studies have recommended anti-inflammatory treatments like NSAID, and prednisolone, and considered limited surgical intervention for severe cases.^{3,10,12} The recommendation for treating these patients is controversial and varies from follow-up with or without imaging to risk reduction therapies and surgery in suspicious lesions to malignancy.^{8,17,18} This patient underwent treatment with prednisolone, NSAID, and hydroxychloroquine due to associated disturbing symptoms of IGM, whereas for the classic LCIS due to its form, excision was not required and close follow-up for cancer screening took place.

CONCLUSION

In conclusion, radiologic findings of IGM can be suggestive of other possible causes and silent etiologies like the primary phase of breast cancer and LCIS can easily mimic IGM presentation. Moreover, resistance to treatment is a red flag indicating possible underlying malignancy and should be taken into account in unresponsive cases and needs further workups.

ETHICAL CONSIDERATIONS

The patient has provided written informed consent to the publication of this case (including the publication of images).

CONFLICT OF INTEREST

The authors declare that they have no conflict of interests.

REFERENCES

1. Kessler E, Wolloch Y. Granulomatous mastitis: a lesion clinically simulating carcinoma. *Am J Clin Pathol.* 1972 Dec;58(6):642–6. doi: 10.1093/ajcp/58.6.642.
2. Pluguez-Turull CW, Nanyes JE, Quintero CJ, Alizai H, Mais DD, Kist KA, et al. Idiopathic Granulomatous Mastitis: Manifestations at Multimodality Imaging and Pitfalls. *Radiographics.* 2018 Apr;38(2):330–56. doi: 10.1148/rg.2018170095.
3. Omeranipour R, Mohammadi SF, Samimi P. Idiopathic granulomatous lobular mastitis - report of 43 cases from iran; introducing a preliminary clinical practice guideline. *Breast Care (Basel).* 2013 Dec;8(6):439–43. doi: 10.1159/000357320.
4. Oztekin PS, Durhan G, Nercis Kosar P, Erel S, Hucumenoglu S. Imaging Findings in Patients with Granulomatous Mastitis. *Iran J Radiol.* 2016 Jul;13(3):e33900. doi: 10.5812/iranjradiol.33900.
5. Alikhassi A, Azizi F, Ensani F. Imaging features of granulomatous mastitis in 36 patients with new sonographic signs. *J Ultrasound.* 2020 Mar;23(1):61–8. doi: 10.1007/s40477-019-00392-3.
6. Stachs A, Stubert J, Reimer T, Hartmann S. Benign Breast Disease in Women. *Dtsch Arztebl Int.* 2019 Aug 9;116(33–34):565–74. doi: 10.3238/arztebl.2019.0565.
7. Sokolova A, Lakhani SR. Lobular carcinoma in situ: diagnostic criteria and molecular correlates. *Mod Pathol.* 2021 Jan;34(Suppl 1):8–14. doi: 10.1038/s41379-020-00689-3.
8. Thomas PS. Diagnosis and Management of High-Risk Breast Lesions. *J Natl Compr Canc Netw.* 2018 Nov;16(11):1391–6. doi: 10.6004/jnccn.2018.7099.



9. Middleton LP, Sneige N, Coyne R, Shen Y, Dong W, Dempsey P, et al. Most lobular carcinoma in situ and atypical lobular hyperplasia diagnosed on core needle biopsy can be managed clinically with radiologic follow-up in a multidisciplinary setting. *Cancer Med*. 2014 Jun;3(3):492–9. doi: 10.1002/cam4.223.
10. Kaviani A, Vasigh M, Omranipour R, Mahmoudzadeh H, Elahi A, Farivar L, et al. Idiopathic granulomatous mastitis: Looking for the most effective therapy with the least side effects according to the severity of the disease in 374 patients in Iran. *Breast J*. 2019 Jul;25(4):672–7. doi: 10.1111/tbj.13300.
11. Altintoprak F, Kivilcim T, Ozkan OV. Etiology of idiopathic granulomatous mastitis. *World J Clin Cases*. 2014 Dec 16;2(12):852–8. doi: 10.12998/wjcc.v2.i12.852.
12. Aghajanzadeh M, Hassanzadeh R, Alizadeh Sefat S, Alavi A, Hemmati H, Esmaeili Delshad MS, et al. Granulomatous mastitis: Presentations, diagnosis, treatment and outcome in 206 patients from the north of Iran. *Breast*. 2015 Aug;24(4):456–60. doi: 10.1016/j.breast.2015.04.003.
13. Binesh F, Shiryazdi M, Bagher Owlia M, Azimi S. Idiopathic granulomatous mastitis, erythema nodosum and bilateral ankle arthritis in an Iranian woman. *BMJ Case Rep*. 2013 Jan 25;2013:bcr2012007636. doi: 10.1136/bcr-2012-007636.
14. Zabetian S, Friedman BJ, McHargue C. A case of idiopathic granulomatous mastitis associated with erythema nodosum, arthritis, and reactive cough. *JAAD Case Rep*. 2016 Mar;2(2):125–7. doi: 10.1016/j.jdcr.2016.01.011.
15. Sripathi S, Ayachit A, Bala A, Kadavigere R, Kumar S. Idiopathic granulomatous mastitis: a diagnostic dilemma for the breast radiologist. *Insights Imaging*. 2016 Aug;7(4):523–9. doi: 10.1007/s13244-016-0497-2.
16. Chu AJ, Cho N, Park IA, Cho SW. Features of Pure Lobular Carcinoma In Situ on Magnetic Resonance Imaging Associated with Immediate Re-Excision after Lumpectomy. *J Breast Cancer*. 2016 Jun;19(2):199–205. doi: 10.4048/jbc.2016.19.2.199.
17. Simpson PT, Gale T, Fulford LG, Reis-Filho JS, Lakhani SR. The diagnosis and management of pre-invasive breast disease: pathology of atypical lobular hyperplasia and lobular carcinoma in situ. *Breast Cancer Res*. 2003;5(5):258–62. doi: 10.1186/bcr624.
18. Wen HY, Brogi E. Lobular Carcinoma In Situ. *Surg Pathol Clin*. 2018 Mar;11(1):123–45. doi: 10.1016/j.path.2017.09.009.
19. Oddó D, Domínguez F, Gómez N, Méndez GP, Navarro ME. Granulomatous lobular mastitis associated with ductal carcinoma in situ of the breast. *SAGE Open Med Case Rep*. 2019;7:2050313X19836583. doi: 10.1177/2050313X19836583.
20. Özşen M, Tolunay Ş, Gökğöz MŞ. Case Report: Ductal Carcinoma in Situ Within A Granulomatous Mastitis. *Eur J Breast Health*. 2018 Jul;14(3):186–8. doi: 10.5152/ejbh.2018.3894.
21. Kaviani A, Zand S, Karbaksh M, Ardalan FA. Synchronous Idiopathic Granulomatous Mastitis and Breast Cancer: A Case Report and Review of Literature. *Arch Breast Cancer*. 2017 Mar 6;32–6. doi: 10.19187/abc.20174132-36.
22. Kay J, Thadhani E, Samson L, Engelward B. Inflammation-induced DNA damage, mutations and cancer. *DNA Repair (Amst)*. 2019 Nov;83:102673. doi: 10.1016/j.dnarep.2019.102673.
23. Cappelli LC, Shah AA. The relationships between cancer and autoimmune rheumatic diseases. *Best Pract Res Clin Rheumatol*. 2020 Feb;34(1):101472. doi: 10.1016/j.berh.2019.101472.
24. Murata M. Inflammation and cancer. *Environ Health Prev Med*. 2018 Oct 20;23(1):50. doi: 10.1186/s12199-018-0740-1.

How to Cite This Article

Tavakol M, Alvand S, Amouzadeh Ardalan F, Assarian A. Idiopathic Granulomatous Mastitis with Incidental Lobular Carcinoma In Situ: A Case Report. Arch Breast Cancer. 2022; 9(3): 314-18.
Available from: <https://www.archbreastcancer.com/index.php/abc/article/view/596>