



DOI: 10.32768/abc.202292247-249



## Late Sensory Neurotization of the Nipple-Areola Complex after Implant-Based Breast Reconstruction

Jose E. Telich-Tarriba<sup>\*a</sup>, Daniel Garza-Arriaga<sup>b</sup>, Alejandro López-Garibay<sup>c</sup>, David Navarro-Barquin<sup>c</sup>, Alexander Cardenas-Mejia<sup>c</sup>

<sup>a</sup>Plastic and Reconstructive Surgery Department, Hospital Angeles Pedregal, Mexico City, Mexico

<sup>b</sup>Breast Reconstruction Department, Fundación de Cáncer de Mama, Mexico City, Mexico

<sup>c</sup>Plastic and Reconstructive Surgery Division, Hospital General "Dr. Manuel Gea Gonzalez", Mexico City, Mexico

### ARTICLE INFO

**Received:**  
20 February 2022  
**Revised:**  
08 March 2022  
**Accepted:**  
10 March 2022

**Keywords:**  
Nipple areola complex,  
intercostal nerves, breast  
implants,  
sensory recovery

### ABSTRACT

**Background:** Nipple-sparing mastectomy (NSM) has become widely adopted owing to its oncologic safety, aesthetic results and psychological benefits. Lack of sensation on the Nipple-areola complex (NAC) after reconstruction remains a common complaint that has been scarcely researched in the alloplastic reconstruction population. The aim of this report is to present a nipple neurotization technique suitable for patients undergoing implant-based breast reconstruction.

**Case Presentation:** A 42-year-old female with ductal breast carcinoma underwent periareolar NSM with implant-based reconstruction and complained about lack of tactile sensation on mastectomy flaps and NAC. A year after the reconstruction surgery, she underwent late NAC neurotization by bridging the 4th intercostal nerve to the undersurface of the areola using a 15cm sural nerve autograft. Recovery of protective and pressure sensation was seen six months later over the NAC.

**Conclusion:** This case confirms that late neurotization in alloplastic reconstruction by bridging the areolar dermis to a donor intercostal nerve provides sensory recovery at the NAC.

Copyright © 2022. This is an open-access article distributed under the terms of the [Creative Commons Attribution-Non-Commercial 4.0 International License](https://creativecommons.org/licenses/by-nc/4.0/), which permits copy and redistribution of the material in any medium or format or adapt, remix, transform, and build upon the material for any purpose, except for commercial purposes.

### INTRODUCTION

Nipple sparing mastectomy (NSM) has received much attention owing to its oncologic safety, aesthetic results and psychological benefits. However, lack of protective and erogenous sensation on the Nipple-areola complex (NAC) after reconstruction remains a common complaint that can be associated with deleterious physical, psychological, and sexual implications.<sup>1</sup>

Spontaneous neurotization of mastectomy flaps is highly variable and may be seen in less than 50% of

patients.<sup>2</sup> Neurotized free flaps have been successfully used for over 20 years, allowing for consistent return of sensation to the breast mound and improved quality of life. Unfortunately, neurotization after alloplastic reconstruction has been scarcely researched.

Peled,<sup>2</sup> and Djohan,<sup>3</sup> independently published preliminary results for immediate NAC neurotization at the time of mastectomy showing recovery of pressure sensation and two-point discrimination. Although their results are promising, we should consider that thousands of patients undergo breast reconstruction yearly and still lack nipple sensation.<sup>4</sup> For this reason, we have developed a technique suitable for patients undergoing implant-based breast reconstruction.

#### \*Address for correspondence:

José E. Telich-Tarriba, M.D.  
Plastic and Reconstructive Surgery Department, Hospital Angeles Pedregal, Mexico City, Mexico  
Tel: +52-551-392-3848  
Email: [josetelich@gmail.com](mailto:josetelich@gmail.com)



## CASE PRESENTATION

A 42-year-old female with ductal carcinoma in situ underwent periareolar NSM with immediate reconstruction using a submuscular breast expander, with no radiotherapy administered. Eleven months later the expander was exchanged for an anatomical silicone implant.

After one year, the patient complained about a lack of tactile sensation on the NAC. Physical exam showed lack of protective and pressure sensation over the NAC and mastectomy flaps. Direct neurotization was proposed. Informed consent was signed and the protocol was approved by our institution's ethical board (PI-20-01).

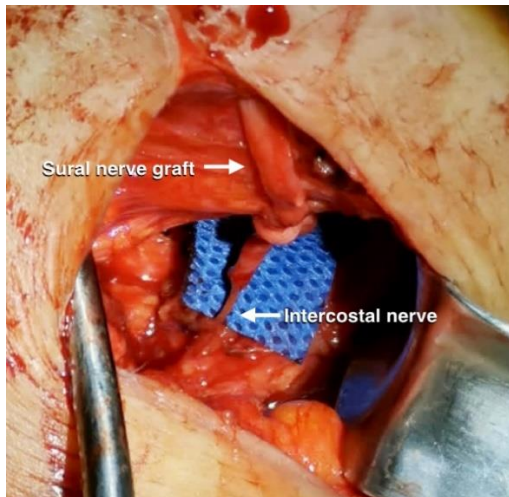
### *Surgical procedure*

A 3cm incision was placed at the intersection of the 4th intercostal space and the external border of the breast implant. Blunt dissection was used to retract the subcutaneous tissue and serratus anterior muscle fibers

until the intercostal space was identified. The rib's perichondrium was incised and the intercostal muscles were detached from the rib to identify the intercostal nerve. A 5cm segment was released and transected distally.

Afterwards, the undersurface of the NAC was exposed through the previous periareolar incision. A second team who worked simultaneously harvested a 15cm sural nerve graft using three discontinuous incisions. The graft was tunneled from the chest incision to the areola in an orthodromic fashion using a malleable metal tunneler.

Coaptation between the intercostal and sural nerve graft was done under magnification with 9-0 nylon (Figure 1), and the distal ends of the nerve were buried in the areolar dermis and fixed in place using 6-0 nylon (Figure 2). All wounds were sutured and the patient was discharged without complications.

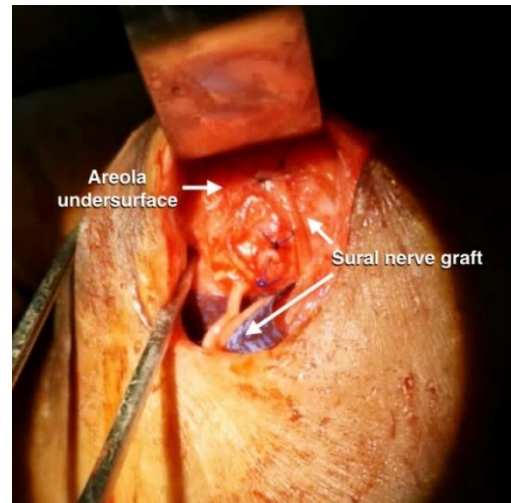


**Figure 1.** Transoperative photograph showing the coaptation between the 4th intercostal nerve and the sural nerve graft

The patient was seen in the outpatient clinic at one, three and six months after surgery. Nipple sensation was evaluated using the Semmes-Weinstein monofilament test and two-point discrimination over the areola. Axon regeneration was evaluated using Tinnel's sign. At six months, the patient reported recovery in light and deep pressure sensation, and had a 15mm two-point discrimination. The sensation of the mastectomy flaps remained unchanged throughout the study period.

## DISCUSSION

Sensory loss after mastectomy is a distressing outcome for patients and has recently sparked interest in breast reconstruction research. Recovery of sensory input from the NAC has been shown to improve quality of life and postoperative satisfaction, and its evaluation



**Figure 2.** Fixation of the sural nerve fibers to the undersurface of the areola.

has recently been incorporated into the BREAST-Q outcomes instrument.<sup>4</sup>

Breast neurotization is not a novel idea, and satisfactory results have been reported for autologous reconstruction but the concept has not been widely adopted for implant-based reconstruction.<sup>5</sup> Immediate NAC neurotization by bridging an intraglandular branch of the fourth intercostal nerve to the areolar dermis at the time of mastectomy has been described for cases of alloplastic,<sup>2,3</sup> and autologous breast reconstruction,<sup>6</sup> as well after gender-affirming mastectomy.<sup>7</sup> Researchers reported recovery of sensation of the NAC and mastectomy flaps comparable to their preoperative status between 6 to 12 months after surgery.<sup>2,3,6,7</sup>

Based on the satisfactory early results on direct nipple neurotization, we aimed to develop a technique



suitable for patients who have already completed their reconstructive protocol. Our technique differs from previous reports in two main areas: the donor nerve and the source of the graft.

Since the glandular branches of the intercostal nerve are no longer available, a subperichondrial harvest of the donor nerve must be performed. Intercostal nerves have been reliably used as donors in brachial plexus reconstruction for decades<sup>8</sup> and have been deemed adequate for targeted skin reinnervation.<sup>9</sup> Dissection requires delicate handling of the nerve but can be successfully achieved by surgeons with experience in microsurgery or peripheral nerve surgery.

Contrary to previous reports, we opted to use a nerve autograft due to the length of the gap and the higher expenses associated with allografts. Despite the differences in approach, our patient had a satisfactory outcome, with return of protective and tactile sensation to the NAC; however, longer follow-up is needed to fully evaluate sensation of the mastectomy flap.

Limitations to our approach include the need for a second donor site, and an extra incision on the breast. Graft harvest was done using small discontinuous incisions, while the chest incision respects aesthetic

subunits and is hidden behind the breast contour, thus limiting aesthetic disturbance. Nevertheless, this technique has the advantage of being tailored for patients that have already completed their reconstructive protocol but remain dissatisfied with breast sensation, especially in cases such as ours in which no recovery was perceived two years after mastectomy. It is simple and reproducible by surgeons with experience in peripheral nerve reconstruction.

### CONCLUSION

This case confirms that late neurotization in alloplastic reconstruction by bridging the areolar dermis to a donor intercostal nerve is capable of providing sensory recovery at the NAC.

### ACKNOWLEDGEMENTS

None.

### ETHICAL CONSIDERATIONS

The patient signed informed consent, and the protocol was approved by our institution's ethical board (PI-20-01).

### CONFLICT OF INTEREST

None.

### REFERENCES

1. Weissler JM, Koltz PF, Carney MJ, Serletti JM, Wu LC. Sifting through the Evidence: A Comprehensive Review and Analysis of Neurotization in Breast Reconstruction. *Plast Reconstr Surg*. 2018 Mar;141(3):550–65. doi: 10.1097/PRS.0000000000004108.
2. Peled AW, Peled ZM. Nerve Preservation and Allografting for Sensory Innervation Following Immediate Implant Breast Reconstruction. *Plast Reconstr Surg Glob Open*. 2019 Jul;7(7):e2332. doi: 10.1097/GOX.0000000000002332.
3. Djohan R, Scomacao I, Knackstedt R, Cakmakoglu C, Grobmyer SR. Neurotization of the Nipple-Areola Complex during Implant-Based Reconstruction: Evaluation of Early Sensation Recovery. *Plast Reconstr Surg*. 2020 Aug;146(2):250–4. doi: 10.1097/PRS.0000000000006976.
4. Peled AW, Amara D, Piper ML, Klassen AF, Tsangaris E, Pusic AL. Development and Validation of a Nipple-Specific Scale for the BREAST-Q to Assess Patient-Reported Outcomes following Nipple-Sparing Mastectomy. *Plast Reconstr Surg*. 2019 Apr;143(4):1010–7. doi: 10.1097/PRS.0000000000005426.
5. Gatherwright J, Knackstedt R, Djohan R. Anatomic Targets for Breast Reconstruction Neurotization: Past Results and Future Possibilities. *Ann Plast Surg*. 2019 Feb;82(2):207–12. doi: 10.1097/SAP.0000000000001733.
6. Tevlin R, Brazio P, Tran N, Nguyen D. Immediate targeted nipple-areolar complex re-innervation: Improving outcomes in immediate autologous breast reconstruction. *J Plast Reconstr Aesthet Surg*. 2021 Jul;74(7):1503–7. doi: 10.1016/j.bjps.2020.11.021.
7. Rochlin DH, Brazio P, Wapnir I, Nguyen D. Immediate Targeted Nipple-Areolar Complex Reinnervation: Improving Outcomes in Gender-affirming Mastectomy. *Plast Reconstr Surg Glob Open*. 2020 Mar;8(3):e2719. doi: 10.1097/GOX.0000000000002719.
8. Tsuyama N, Hara T, Maehiro S, Imoto T. [Intercostal nerve transfer for traumatic brachial nerve palsy]. *Seikei Geka*. 1969 Nov;20(14):1527–9. doi: Not Available
9. Viterbo F, Ripari WT. Nerve grafts prevent paraplegic pressure ulcers. *J Reconstr Microsurg*. 2008 May;24(4):251–3. doi: 10.1055/s-2008-1078692..

### How to Cite This Article

Telich-Tarriba JE, Garza-Arriaga D, López-Garibay A, Navarro-Barquin D, Cardenas-Mejia A. Late Sensory Neurotization of the Nipple-Areola Complex After Implant-Based Breast Reconstruction. *Arch Breast Cancer*. 2022; 9(2): 247-9.

Available from: <https://www.archbreastcancer.com/index.php/abc/article/view/536>