



DOI: 10.32768/abc.202292231-235



Accuracy of Digital Mammography Unit in Diagnosis Breast Cancer in Gaza Strip, Palestine

Samira S Abo Al-Shiekh^{*a}, Zinah Abdul-Rahman Tawfeeq^b, Kamal Jabre^c^aPublic Health, Ministry of Health, Palestine^bPalestinian Board of Radiology, MOH, Palestine^cConsultant Radiologist, MOH, Palestine

ARTICLE INFO

Received:

07 January 2022

Revised:

02 February 2022

Accepted:

02 February 2022

Keywords:Digital mammography,
Ultrasound,
Accuracy measures,
Gaza Strip

ABSTRACT

Background: Breast cancer is considered a major health problem and the most common cancer among females in both developed and non-developed countries. Early diagnosis of breast cancer decreases morbidities and mortalities. This study attempts to explore the accuracy measures of a digital mammography unit in the diagnosis of breast cancer and compare the mammography results with the final histopathology results.

Methods: The study was designed as a cross-sectional prospective hospital base in which mammography examination was used for patients. Then, U/S was performed as a complementary study. All the mammography and U/S reports were reviewed and compared with the histopathology results. Six indicators were used to measure the accuracy of the mammography system using their formulas. SPSS program was used to examine the correlation between imaging results and histopathological findings and to draw the area under the receiver operating characteristic curve (AUC). Confidence interval was considered at 95% and margin of error at 5%.

Results: Sensitivity, Specificity, PPV, NPV, accuracy and the area under the ROC curve of mammography alone were 94.9%, 66.7%, 90%, 66.7%, 0.771 and increased to 100%, 76.9%, 90.3%, 100%, 92.7%, 0.917, respectively when Ultrasound was used as a complementary to mammography. A statistically significant moderate correlation was shown between the results of mammography alone and histopathology results (Spearman correlation= 0.527, P-value<0.01), and a statistically significant strong correlation between mammography combined with ultrasound, and histopathology results (Spearman correlation=0.882, P-value<0.01).

Conclusion: Mammography is an important tool to detect breast cancer. Mammography when combined with Ultrasound yields a very significant improvement in sensitivity and specificity for diagnosing different breast lesions.

Copyright © 2022. This is an open-access article distributed under the terms of the [Creative Commons Attribution-Non-Commercial 4.0](https://creativecommons.org/licenses/by-nc/4.0/) International License, which permits copy and redistribution of the material in any medium or format or adapt, remix, transform, and build upon the material for any purpose, except for commercial purposes.

INTRODUCTION

Breast cancer is the most common cancer among females in both developing and developed countries.¹⁻⁴ It is becoming an important health problem in low and

middle-income countries where historically low incidence rate has increased by approximately 5 % per year.² In addition, a study by Forouzanfar and colleagues revealed that there was a 3.1% annual increase in breast cancer incidence, with an increased estimated rate of 641,000 cases in 1980 to 1,643,000 cases in 2010.³

In Palestine, according to the Ministry of Health (MOH), there were 503 new cases in the West Bank in

***Address for correspondence:**Samira S Abo Al-Shiekh, Ph.D
Public Health, Ministry of Health, Palestine
Tel: +97-259-7155586
Email: Samira.alshiekh.1980@gmail.com



2017 constituting around 17.2% of all cancer cases.⁴ According to the cancer registry in the Gaza strip, there were 684 cases in 2016 constituting around 20.5% of all cancer cases.⁵ In addition, the most affected age groups were (45 – 54) years, and (55 – 64) years old constituting 23%, and 24.6% of all BC cases, respectively.⁶

Mammography is considered the first line of investigation of breast cancer. However, studies show a lower sensitivity of mammography with high-density and relatively small breasts.⁷ Also, there are some limitations to doing mammography for women under the age 40- 50 years old.^{8,9} Over the last decade, most analogue mammography screening has changed into full field digital mammography (FFDM) which provides additional benefits for breast screening.¹⁰ Digital mammography increases the detection rate and decreases the number of false positive leads, increasing the effectiveness of screening with sensitivity of over 85% and specificity over 90%. However, the efficacy of mammography varies depending on performance of interpretation radiologist.^{11,12} A new digital diagnostic mammography unit was recently introduced at Al Shifa Hospital- MOH. Its role in the initial diagnosis of breast diseases particularly breast cancer has not been studied yet.

This study attempts to explore the accuracy measures of a digital mammography unit in the diagnosis of breast cancer and compare mammography results with final histopathology results. In addition, the study will compare the results of mammography when combined with Ultrasound with the final histopathology results.

METHODS

This study is designed as a cross-sectional prospective hospital base study.

Sample size

This study included all the women who came to the digital mammography unit at Al Shifa Hospital to conduct mammography and were approved to have breast cancer within six months in the period 1.1.2019 to 20.7.2019.

Mammography examination

Mammography machine: All the patients underwent the mammogram on a digitalized mammography system (Fuji film- Amulet Innovality) that has been recently used in the MOH.

Mammographic views: Conventional views (Cranio-caudal (CC and medio-lateral oblique (MLO) views. Additional views (exaggerated CC, spot compression, magnification Views) whenever indicated.

Exposure factors: Automatic exposure used for all patients

Compression was applied and respiration was suspended on exposure.

The mammography exams were interpreted by two radiology experts together. The radiologist did not know the impression of the surgeon and the possible diagnosis because in many cases the patients are not examined physically due to the cultural barriers and in some cases the surgeon did not report their clinical impression to the radiologists.

U/S examination

The U/S was performed only as a complementary study, when needed, by an expert radiologist. The radiologist doing the U/S was aware of the results of the previous mammography.

Biopsy

Biopsy reports reviewed were done at the histopathology department at Al Shifa Hospital, NGOs or the private sectors.

Mammography reports with normal, asymmetry, dense breast and benign lesions were classified as mammography with nonmalignant findings. Mammography reports concluded as either suspected malignancy for other investigations or with evidence of malignancy were classified as mammography with malignant findings.

Indicators

We used six indicators to evaluate the diagnostic performance of the system: accuracy, sensitivity, specificity, negative predictive value (NPV), positive predictive value (PPV), and the area under the receiver operating characteristic curve (AUC).

Accuracy is described as the ratio of the correct samples distinguished by the classifier to the total samples. The indicators can be described as follows:

$$\text{Accuracy} = (\text{TP} + \text{TN}) / (\text{TP} + \text{TN} + \text{FP} + \text{FN}) * 100\%$$

$$\text{Sensitivity} = \text{TP} / (\text{TP} + \text{FN}) * 100\%$$

$$\text{Specificity} = \text{TN} / (\text{TN} + \text{FP}) * 100\%$$

$$\text{PPV} = \text{TP} / (\text{TP} + \text{FP}) * 100\%$$

$$\text{NPV} = \text{TN} / (\text{TN} + \text{FN}) * 100\%$$

In addition, we used the AUC the area of the ROC (receiver operating characteristic) curve to appraise the performance.

Ethical consideration

Ethical approval was obtained from the Palestinian Health Research Council (PHRC/HC/291/17). Patients' rights and confidentiality of information were ensured. All gathered documents were kept and saved in a private closet.

Data analysis

Data were analyzed using SPSS program version-23. Descriptive statistics and frequency tables were used to describe the main features of the data. The



indicators of diagnostic performance of mammography unit alone, and with the combination of US exam were calculated based on histopathology reports using its formulas. The AUC was also drawn. Spearman correlation test was used to examine the correlation between imaging results and histopathological findings. Confidence interval was set at 95% and margin of error at 5%.

RESULTS

Fifty-two women participated in the study. Among them, 8 were 40 years and less, 30 patients were in the age group 41- 60 years, and 14 patients were 61 years and more. Also, 84.6% of patients were married at the

time of data collection, and only six patients did not have breastfeeding. The majority of participants (39) complained of a breast mass, with other complaints including axilla mass among four participants, nipple discharge among three, pain among four, and breast readiness among two participants. Sixty five of the participants had a right breast problem, and 30.8% of them had a left breast problem. Fifty percent of patients used to perform breast self-exam and the majority of them (84.6%) conducted a clinical breast exam before their referral to the unit. Eight patients had a family history of breast cancer. Baseline characteristics of the participants are shown in Table 1.

Table 1. Baseline characteristics of the participants

Variable	Category	Frequency (%)
Age	40 years and less	8 (15.4)
	41-60 years	30 (57.7)
	61 and more	14 (26.9)
Marital status	Single	2 (3.8)
	Married	44 (84.6)
	Widowed	6 (11.5)
Breastfeeding	No	6 (11.5)
	Not all children	2 (3.8)
	All children	44 (84.6)
Breast problem	Breast mass	39 (75)
	Axilla mass	4 (7.7)
	Nipple discharge	3 (5.8)
	Pain	4 (7.7)
Problem place	Breast readiness	2 (3.8)
	At the RT Side	34 (65.4)
	At the LT Side	16 (30.8)
The patient used to perform Breast Self-Examination	At Both breasts	2 (3.8)
	Yes	26 (50)
A clinical breast exam was performed	No	26 (50)
	Yes	44 (84.6)
Family history of breast cancer	No	8 (15.4)
	Yes	8 (15.4)
	No	44 (84.6)

Of the Fifty-two women, mammography individually detected 40 lesions and missed four lesions, which were subsequently detected by Ultrasound and approved by histopathology results. Four of the forty lesions detected by digital mammography were subsequently proved by Ultrasound and

histopathology as nonmalignant findings. Sensitivity, specificity, PPV, NPV, accuracy, and the area under the ROC curve of mammography alone were 94.9%, 66.7%, 90%, 66.7%, 0.771, respectively.

When Ultrasound was used as a complementary to mammography, Sensitivity, Specificity, PPV, NPV,



accuracy and the area under the ROC curve were 100%, 76.9%, 90.3%, 100%, 92.7%, 0.917, respectively.

A statistically significant moderate correlation was shown between the results of mammography alone and histopathology results (Spearman correlation = 0.527, $P < 0.01$), and a statistically significant strong correlation between mammography combined with Ultrasound and histopathology results (Spearman correlation = 0.882, $P < 0.01$)

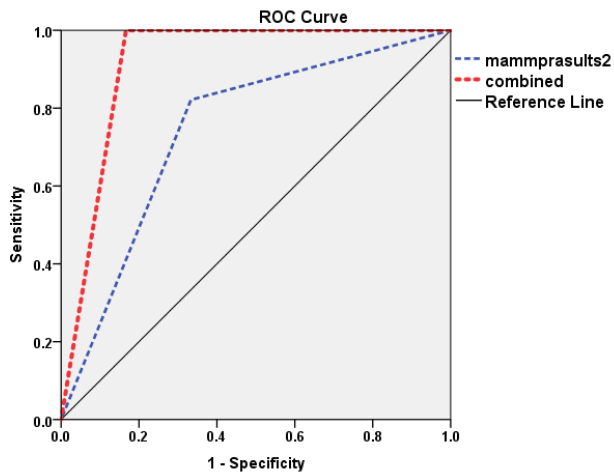


Figure 1. ROC curves for mammography alone, and combined with U/S

DISCUSSION

Patients with signs and symptoms of breast cancer present for imaging evaluation. However, studies show that mammography is not a perfect tool to detect breast cancer as it misses some tumors in some women, particularly in women at early ages,^{13,14} and women with dense breasts.^{9,13,14}

The significance of combined mammographic and sonographic imaging in symptomatic patients has been previously studied. Also, the sensitivity of the two modalities on 45 participants was studied⁹, which resulted in 90.6% for mammography and 100% for U/S. This figure was 77.7% for mammography and 55.5% for U/S.¹⁵ Also, another study⁷ found this value at 81.71% for mammography and 95.53%. Moreover, additional U/S significantly increased the sensitivity of digital mammography from 69.05% to 92.86%.¹⁶

Ultrasound is more sensitive than mammography in detecting lesions in women with dense breast tissue. The sensitivity and diagnostic accuracy among patients <50 years of age and in premenopausal or perimen-

opausal patients were significantly higher for sonography than for mammography.⁷ In our study, four patients were diagnosed with cancer by Ultrasound, which was previously diagnosed as a nonmalignant finding in mammography. In another study, two patients out of nine (22.22%) were diagnosed with cancer in Ultrasound, which was occult in mammography.¹⁵ Regarding the high rate of PPV (90%), the PPV of tests is known to vary with the prevalence of the condition in different settings.¹⁷ This should be considered when interpreting the results and implementing the findings of this study for various groups of patients, and populations with different pre-test probabilities of breast cancer.

The strong and statistically significant correlation between combined imaging modalities (mammography and Ultrasound) and biopsy leads us to the conclusion that with the combination of mammography and Ultrasound we can almost achieve the accuracy of fine-needle biopsy in detecting breast malignancy.

CONCLUSION

Mammography is an important tool to detect breast cancer. However, it is not 100% accurate. The combination of mammography and U/S increases the accuracy of detecting malignancy in symptomatic patients. Mammography when combined with Ultrasound yields very significant improvement in sensitivity and specificity for diagnosing different breast lesions.

FUNDING

None.

ETHICAL CONSIDERATIONS

This research was approved by the Palestinian Health council in 2019.

DATA AVAILABILITY

The data used to support the findings of this study are available from the corresponding author upon request.

ACKNOWLEDGEMENTS

None.

CONFLICT OF INTEREST

The authors declare no conflict of interest, financial or otherwise.

REFERENCES

1. Ibrahim AS, Khaled HM, Mikhail NNH, Baraka H, Kamel H. Cancer incidence in Egypt: results of the national population-based cancer registry program. *J Cancer Epidemiol.* 2014;2014. doi: 10.1155/2014/437971.
2. Bray F, Ren J, Masuyer E, Ferlay J. Global



- estimates of cancer prevalence for 27 sites in the adult population in 2008. *Int J cancer*. 2013;132(5):1133–45. doi: 10.1002/ijc.27711.
3. Forouzanfar MH, Foreman KJ, Delossantos AM, Lozano R, Lopez AD, Murray CJL, et al. Breast and cervical cancer in 187 countries between 1980 and 2010: a systematic analysis. *Lancet*. 2011;378(9801):1461–84. doi: 10.1016/S0140-6736(11)61351-2.
 4. Ministry of Health. Health annual report. Palestinian Health Information Center. 2018. doi: Not Applicable.
 5. Ministry of Health. Cancer incidence in the Gaza Strip Facts and Figures 2015-2016. 2016. doi: Not Applicable.
 6. Ministry of Health. Gaza Strip cancer report 2009-2014. 2015. doi: Not Available
 7. Ying X, Lin Y, Xia X, Hu B, Zhu Z, He P. A comparison of mammography and ultrasound in women with breast disease: a receiver operating characteristic analysis. *Breast J*. 2012;18(2):130–8. doi: 10.1111/j.1524-4741.2011.01219.x.
 8. Britton P, Warwick J, Wallis MG, O’Keeffe S, Taylor K, Sinnatamby R, et al. Measuring the accuracy of diagnostic imaging in symptomatic breast patients: team and individual performance. *Br J Radiol*. 2012;85(1012):415–22. doi: 10.1259/bjr/32906819.
 9. Fatima ST, Zahur Z, Jeilani A, Hussain SJA, Abbasi NZ, Khan AA, et al. Ultrasound-a useful complementary tool to mammography in assessment of symptomatic breast diseases. *J Ayub Med Coll Abbottabad*. 2015;27(2):381–3. doi: Not Available.
 10. Hodgson R, Heywang-Köbrunner SH, Harvey SC, Edwards M, Shaikh J, Arber M, et al. Systematic review of 3D mammography for breast cancer screening. *The Breast*. 2016;27:52–61. doi: 10.1016/j.breast.2016.01.002.
 11. Kim E-K, Kim H-E, Han K, Kang BJ, Sohn Y-M, Woo OH, et al. Applying data-driven imaging biomarker in mammography for breast cancer screening: preliminary study. *Sci Rep*. 2018;8(1):1–8. doi: 10.1038/s41598-018-21215-1.
 12. Vinnicombe S, Pinto Pereira SM, McCormack VA, Shiel S, Perry N, dos Santos Silva IM. Full-field digital versus screen-film mammography: comparison within the UK breast screening program and systematic review of published data. *Radiology*. 2009;251(2):347–58. doi: 10.1148/radiol.2512081235.
 13. Alshayookh FS, Ahmed HM, Awad IA, Jastaniah SD. Ultrasound alongside with mammogram in women with physically dense breast. *Adv Breast Cancer Res*. 2014;2014. doi: 10.4236/abcr.2014.33013.
 14. Wanders JOP, Holland K, Veldhuis WB, Mann RM, Pijnappel RM, Peeters PHM, et al. Volumetric breast density affects performance of digital screening mammography. *Breast Cancer Res Treat*. 2017;162(1):95–103. doi: 10.1007/s10549-016-4090-7.
 15. Tiwari P, Ghosh S, Agrawal VK. Evaluation of breast lesions by digital mammography and ultrasound along with fine-needle aspiration cytology correlation. *J Cancer Res Ther*. 2018;14(5):1071. doi: 10.4103/0973-1482.191053.
 16. Elizalde A, Pina L, Etxano J, Slon P, Zalazar R, Caballeros M. Additional US or DBT after digital mammography: which one is the best combination? *Acta radiol*. 2016;57(1):13–8. doi: 10.1177/0284185114563641.
 17. Usher-Smith JA, Sharp SJ, Griffin SJ. The spectrum effect in tests for risk prediction, screening, and diagnosis. *bmj*. 2016;353. doi: 10.1136/bmj.i3139.

How to Cite This Article

Abo Al-Shiekh S, Abdul-Rahman Tawfeeq Z, Jabre K. Accuracy of Digital Mammography Unit in Diagnosis Breast Cancer in Gaza Strip, Palestine. Arch Breast Cancer. 2022; 9(2): 231-5.

Available from: <https://www.archbreastcancer.com/index.php/abc/article/view/518>