



DOI: 10.32768/abc.202292236-239



Familial Fibroadenoma of Breast: A Case Series of Uncommon Presentation of a Common Disease

Mahim Koshariya^a, Vidhu S. Khare^{*a}, Badri Patel^a, Shikha Shukla^a, Aryesh K. Gupta^a, Mohammad Riyaz^a, Gyanendra Kumar^a

^aDepartment of General Surgery, Gandhi Medical College & Hamidia Hospital, Bhopal, India

ARTICLE INFO

Received:

18 October 2021

Revised:

21 February 2022

Accepted:

22 February 2022

Keywords:

Fibroadenoma,
Multiple,
Bilateral,
Familial

ABSTRACT

Background: Fibroadenoma is the second most common tumour in the breast (after carcinoma) and is the most common tumour in women younger than 30 years. Multiple fibroadenomas (more than five lesions in one breast) are very uncommon and are considered disease. Familial bilateral multiple fibroadenoma is an exceedingly rare presentation with only one such case described earlier in medical literature where three siblings had multiple bilateral breast fibroadenomas. We report a case series of familial fibroadenomas present in four siblings, along with one case presenting with bilateral multiple fibroadenoma, which is first in the medical literature.

Case Presentation: Fine needle Aspiration were suggestive of bilateral multiple fibroadenoma. Upon surgery, 10 fibroadenomas were removed from the right breast and 9 fibroadenomas were removed from the left breast. Histopathological examination was consistent with fibroadenoma with myxomatous change.

Conclusion: Familial fibroadenoma of the breast is an exceedingly rare presentation of a very common tumour. This was the first reported case of 4 siblings having familial fibroadenoma. Further studies are required to investigate the familial nature of this disorder.

Copyright © 2022. This is an open-access article distributed under the terms of the [Creative Commons Attribution-Non-Commercial 4.0 International License](https://creativecommons.org/licenses/by-nc/4.0/), which permits copy and redistribution of the material in any medium or format or adapt, remix, transform, and build upon the material for any purpose, except for commercial purposes.

INTRODUCTION

Fibroadenoma is the second most common tumour in the breast (after carcinoma) and is the most common tumour in women younger than 30 years.¹ Multiple fibroadenomas (more than five lesions in one breast) are very uncommon and are considered a disease.²

A fibroadenoma does not require excision unless it is associated with suspicious cytology, it becomes exceptionally large, or the patient expressly desires the lump to be removed.³ Therefore, women should be counselled for whom the options for treatment include

surgical removal, cryoablation, vacuum-assisted biopsy, or observation.²

Familial bilateral multiple fibroadenoma is a very rare presentation, with only one such case described earlier in the medical literature where three siblings had multiple bilateral breast fibroadenomas.⁴ We report a case series familial fibroadenoma with one case of bilateral multiple bilateral fibroadenomas present in four siblings, which is first in the medical literature.

CASE PRESENTATION

Case A - Sibling 1

The patient, a 29-year-old female, presented with complain of multiple lumps in bilateral breasts for 8 years. They were associated with cyclical pain, which coincided with menstruation. The pain was mild in severity, non-radiating, dull aching and relieved on analgesics. There was no history of discharge from the

***Address for correspondence:**

Vidhu Shekhar Khare, M.D

Department of Surgery, Gandhi Medical College & Hamidia Hospital, Bhopal India

Tel: +91-942-446-8472

Email: vidsfriendcircle@gmail.com



nipple. She had conceived once 8 years back. She was the eldest of four sisters, and the rest of the three sisters also had similar complaints, of whom two were operated 1 month back in the same institute. Both had left breast fibroadenoma confirmed on histopathological examination of excised lump. None of the first-degree relatives had history of Breast Carcinoma.

The general and systemic examination was unremarkable. On local examination, 2 lumps of size approximately 5x3cm and 3x1cm were palpable in the upper outer quadrant and upper inner quadrant of right breast, respectively. They were mobile, non-tender and not fixed to surrounding tissue or skin. In the left breast, a lump of size approximately 3x1cm was palpated in the upper outer quadrant. It was mobile, non-tender and not fixed to surrounding tissue or skin.

HR (High Resolution) USG of bilateral breasts was performed, which showed well marginated round to oval hypoechoic mass lesion in the mammary zone of the right breast in upper outer and inner quadrant measuring 18x15mm and 21x17mm, respectively. A similar lesion was noted in the left breast, measuring 17x13mm at the upper outer quadrant. A well-defined anechoic cyst of 30x26cm was seen in the left breast upper inner quadrant. FNAC of bilateral breast was done, which was suggestive of fibroadenoma. Core

biopsy was not done as the findings were strongly in favour of fibroadenoma and more invasive procedures were avoided. The patient requested removal of the pathology.

Routine blood investigations were done, and the patient was planned for surgery. Informed consent was taken from the patient. General anesthesia was given. Periareolar incisions were given in both breasts. Then, 10 fibroadenomas were removed from the right breast, of which the maximum size was 4x2cm. One of them had a greenish-coloured discharge. Also, 8 fibroadenomas were removed from the left breast, of which the maximum size was 3x2cm. Also, one cystic lesion of size 4x2cm was removed, which had turbid fluid as its content. The removed tissue was sent for histopathological examination and fluids were sent for culture and sensitivity.

Histopathological examination was consistent with intra and peri canalicular fibroadenoma breast with myxomatous change. No evidence of malignancy was seen. The fluid culture came back sterile. The patient was discharged on 5th post-operative day and the sutures were removed on 7th post-operative day on follow-up. The patient had no complications or recurrence. Last follow-up was 1 year post surgery.

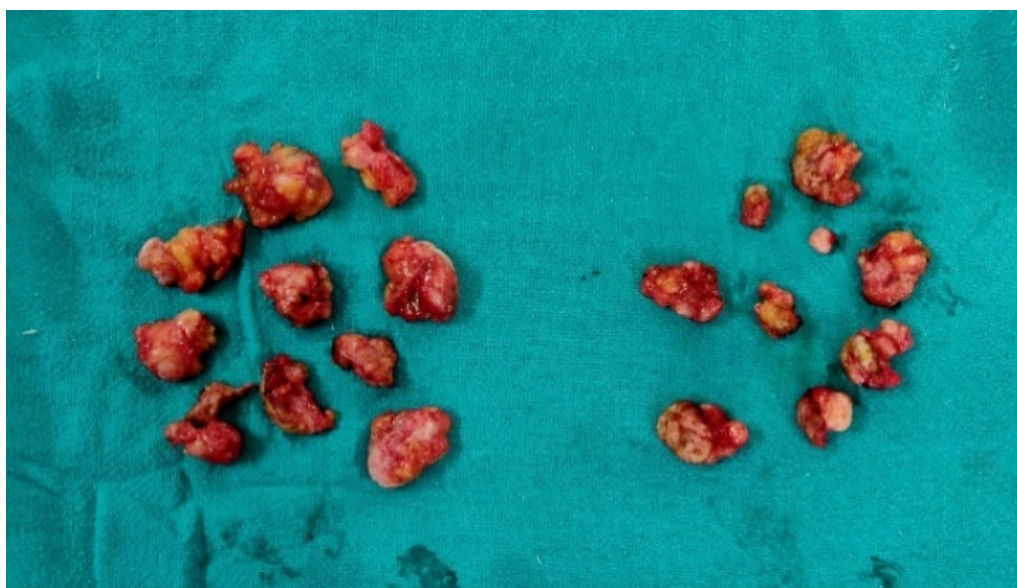


Figure 1. Intraoperative photo of excised fibroadenomas

Case B - Sibling 2

A 24-year-old female presented with a complaint of a lump in the left breast for 3 years. It was not associated with pain. A lump of size 5x6cm was removed from the junction of upper outer and lower outer quadrant of the left breast as per the patient's request. Histopathological examination was consistent with fibroadenoma breast. There were no associated complications/recurrence in 18 months follow-up.

Case C - Sibling 3

A 28-year-old female presented with complain of lump in the left breast for 6 months. It was not associated with pain. Then, 2 lumps of size 5x6cm and 2x2cm were removed from junction of upper outer and upper inner and lower inner quadrant of the left breast, respectively as the patient requested removal. Histopathological examination was consistent with



fibroadenoma breast. There were no associated complications/recurrence in 18 months follow-up.

Case D - Sibling 4

A 17-year-old female presented with lump in right breast for 6 months. She had a history of open appendectomy 4 years back with no complications.

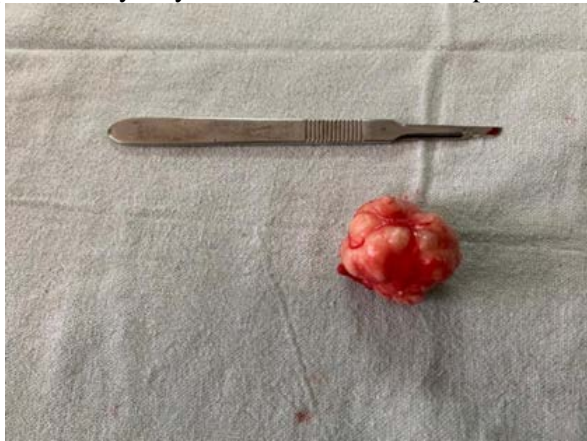

Figure 2. Photo of excised fibroadenoma

DISCUSSION

Fibroadenomas are benign solid tumours composed of stromal and epithelial elements. Fibroadenoma is the second most common tumour in the breast (after carcinoma) and is the most common tumour in women younger than 30 years. In contrast to cysts, fibroadenomas most often arise during the late teens and early reproductive years.¹

Fibroadenomas usually grow to 1 or 2cm in diameter and then are stable but may grow to a larger size. Small fibroadenomas (≤ 1 cm in size) are considered normal, whereas larger fibroadenomas (≤ 3 cm) are disorders and giant fibroadenomas (> 3 cm) are disease. Similarly, multiple fibroadenomas (more than five lesions in one breast) are very uncommon and are considered a disease.²

A fibroadenoma does not require excision unless it is associated with suspicious cytology, it becomes exceptionally large, or the patient expressly desires the lump to be removed. Alternatives to surgery include cryoablation, heating with high-frequency ultrasound (ecotherapy) or removal with a large core vacuum biopsy system.³ Therefore, women should be counselled for whom the options for treatment include surgical removal, cryoablation, vacuum-assisted biopsy, or observation.²

Bilateral multiple fibroadenoma is an uncommon presentation.⁵ Familial bilateral multiple fibroadenomas is an exceedingly rare presentation, with only one such case described earlier in medical literature where three siblings had multiple bilateral breast fibroadenomas. The patient undergoing surgery had 14

The female currently does not wish to get any operative procedure done.

Genetic consultation is currently not available in the institute, so we could not offer it to any of the patients.

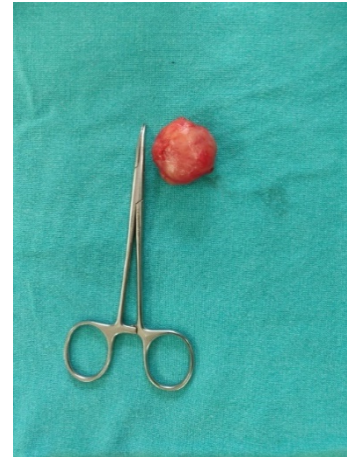

Figure 3. Photo of one of the excised fibroadenoma

classical fibroadenomas in the right and 9 in the left breast.⁴

This was a case of bilateral multiple fibroadenomas present in four siblings, which is first in the medical literature.

A review of 9,067 females showed that the risk of breast carcinoma in females with Fibroadenoma is similar to females with other benign breast diseases, even in females with complex fibroadenomas (cyst diameter 3mm or larger, sclerosing adenosis, epithelial calcifications, and papillary apocrine metaplasia).⁶ On the other hand, a cohort study done on 70877 Swedish females demonstrated that females with a confirmed histological diagnosis of Fibroadenoma have a 74% higher rate of being diagnosed with Breast Carcinoma. Both Breast Carcinoma and Fibroadenoma share common risk factors like higher education and family history of Breast cancer. Late menarche, larger childhood BMI and more children are associated with lower incidence of both Carcinoma and Fibroadenoma, while the use of OCPs is not directly translated to the development of either.⁷ There is some evidence that multiple breast fibroadenomas may be caused by using hormonal contraceptives.⁸

The development of malignant transformation in a fibroadenoma is a rare occurrence, with just around 100 cases in the literature.⁹

Recent studies have shown the role of *MED12* mutations in patients of fibroadenomas, but their relationship to familial presentation is not yet clear.¹⁰ A subset of complex fibroadenoma also demonstrate exon *MED12* mutations, although at a lower



frequency. Further research is warranted to confirm the prognostic significance of these mutations and their correlation to Carcinoma development.¹¹

CONCLUSION

Familial bilateral multiple fibroadenoma of the breast is an exceedingly rare presentation of a quite common tumour, i.e., fibroadenoma. This was the first reported case series of 4 siblings having familial fibroadenoma and of a case of familial bilateral multiple fibroadenoma. Further studies are required to investigate the familial nature of this disorder.

REFERENCES

1. Kelly K. Hunt EAM. Diseases of the Breast. Sabiston textbook of surgery : the biological basis of modern surgical practice. 20 ed: Elsevier; 2016. p. 820-64.
2. Kelly K. Hunt JFRR, and Kirby I. Bland. The Breast. In: F. Charles Bruniciardi, Dana K. Andersen, Timothy R. Billiar, David L. Dunn, Lillian S. Kao, John G. Hunter, Jeffrey B. Matthews, Raphael E. Pollock. The Breast. Schwartz's principles of surgery. 11 ed: McGraw-Hill; 2019. p. 497-564.
3. Sainsbury. RC. The Breast. Bailey & Love's short practice of surgery. 27 ed: CRC Press; 2018. p. 860-82.
4. Naraynsingh V, Raju GC. Familial bilateral multiple fibroadenomas of the breast. *Postgrad Med J*. 1985;61(715):439-40. doi: 10.1136/pgmj.61.715.439.
5. Panda SK, Patro B, Mishra J, Dora RK, Subudhi BSK. Multiple fibroadenomas in bilateral breasts of a 46-year-old Indian woman - A case report. *Int J Surg Case Rep*. 2014;5(5):262-4. doi: 10.1016/j.ijscr.2013.12.013.
6. Nassar A, Visscher DW, Degnim AC, Frank RD, Vierkant RA, Frost M, et al. Complex fibroadenoma and breast cancer risk: a Mayo Clinic Benign Breast Disease Cohort Study. *Breast Cancer Res Treat*. 2015;153(2):397-405. doi: 10.1007/s10549-015-3535-8.
7. Li J, Humphreys K, Ho PJ, Eriksson M, Darai-Ramqvist E, Lindström LS, et al. Family History, Reproductive, and Lifestyle Risk Factors for Fibroadenoma and Breast Cancer. *JNCI Cancer Spectr*. 2018;2(3):pky051. doi: 10.1093/jncics/pky051.
8. Wiegenstein L, Tank R, Gould VE. Multiple breast fibroadenomas in women on hormonal contraceptives. *N Engl J Med*. 1971;284(12):676. doi: Not Available
9. Chintamani, Khandelwal R, Tandon M, Yashwant K, Kulshreshtha P, Aeron T, et al. Carcinoma developing in a fibroadenoma in a woman with a family history of breast cancer: a case report and review of literature. *Cases J*. 2009;2:9348. doi: 10.1186/1757-1626-2-9348.
10. Loke BN, Md Nasir ND, Thike AA, Lee JYH, Lee CS, Teh BT, et al. Genetics and genomics of breast fibroadenomas. *J Clin Pathol*. 2018;71(5):381-7. doi: 10.1136/jclinpath-2017-204838.
11. da Silva EM, Beca F, Sebastiao APM, Murray MP, Silveira C, Da Cruz Paula A, et al. Stromal MED12 exon 2 mutations in complex fibroadenomas of the breast. *J Clin Pathol*. 2020. doi: 10.1136/jclinpath-2020-207062.

ETHICAL CONSIDERATIONS

Informed consent was taken from all patients for operative intervention as well as publication of the findings. Ethical approval was given by the Institutional Ethics Committee.

ACKNOWLEDGEMENTS

None.

CONFLICT OF INTEREST

None.

How to Cite This Article

Koshariya M, Khare VS, Patel B, Shukla SH, Gupta AK, Riyaz M, et al. Familial Fibroadenoma of Breast: A Case Series of Uncommon Presentation of a Common Disease. *Arch Breast Cancer*. 2022; 9(2): 236-9.

Available from: <https://www.archbreastcancer.com/index.php/abc/article/view/477>