



DOI: 10.19187/abc.201524129-132

## Sternal Resection for Sternal Metastasis from Breast Cancer: Report of a Case and Review of the Literature

Massoome Najafi<sup>a</sup>, Afsaneh Alikhassi<sup>b</sup>, Mohammad Ashouri<sup>c</sup>, Ramesh Omranipour<sup>\*\*a</sup>

<sup>a</sup> Division of Surgical Oncology, Department of Surgery, Cancer Institute, Tehran University of Medical Sciences, Tehran, Iran

<sup>b</sup> Department of Radiology, Cancer Institute, Tehran University of Medical Sciences, Tehran, Iran

<sup>c</sup> Department of Surgery, Imam Khomeini Hospital, Tehran University of Medical Sciences, Tehran, Iran

### ARTICLE INFO

**Received:**  
28 September 2015  
**Revised:**  
19 November 2015  
**Accepted:**  
22 November 2015

**Keywords:**  
Sternectomy,  
breast cancer,  
sternal metastasis

### ABSTRACT

**Background:** There has been increasing trend towards surgical treatment of metastases across different cancer types, including breast cancer, in the recent decade. Single metastasis of breast cancer to sternum is a rare situation. We present a case of sternectomy for metastasis from breast cancer.

**Case presentation:** A 58-year-old woman with a history of modified radical mastectomy for breast cancer 13 years earlier, presented with a mass over sternum. Diagnostic work up revealed a mass involving sternum and no evidence of systemic spread. She underwent resection of sternum and reconstruction of chest wall. Pathology revealed an invasive carcinoma that was hormone receptor positive on immunohistochemistry. Chemotherapy and radiotherapy were delivered after surgery and hormone therapy with Letrozole was initiated. She is disease free 37 months after surgery.

**Conclusion:** Surgical treatment of solitary sternal metastasis of breast cancer is justifiable and may result in long term disease-free survival.

### Introduction

Breast cancer is the most common cancer among women worldwide. The most common metastasis site of breast cancer is the bone.<sup>1</sup> The sternum is the third common site of bone metastasis after the spine and the ribs.<sup>1,2</sup> An isolated metastasis of breast cancer to the sternum is however rare. There has been an increasing interest in the surgical management of metastases of some cancers including breast cancer in the last decade.<sup>3</sup> We present a case of sternum

resection for breast cancer recurrence in the chest wall after a long disease-free interval.

### Case presentation

A 58-year-old woman was referred to our breast clinic because of a chest wall mass. She had a history of modified radical mastectomy for invasive ductal carcinoma of the right breast 13 years ago. The tumor diameter was 2.5 cm and there was no axillary lymph node metastasis. She received chemotherapy with epirubicin, 5-fluorouracil and cyclophosphamide after the surgery but no radiotherapy was performed. The tumor was hormone receptor positive and the patient received Tamoxifen for five years. HER-2 status of the tumor was not reported. She was disease free until 3 months before admission when she noticed pain and a mass in the chest wall over the sternum.

On physical examination, there was a hard 10 cm

### Address for correspondence:

Ramesh Omranipour, MD  
Address: Cancer Institute, Imam Khomeini hospital,  
Keshavarz Blvd., Tehran, Iran  
Tel: +98 21 61192509  
Fax: +98 21 66935063  
Email: omranipour@sina.tums.ac.ir

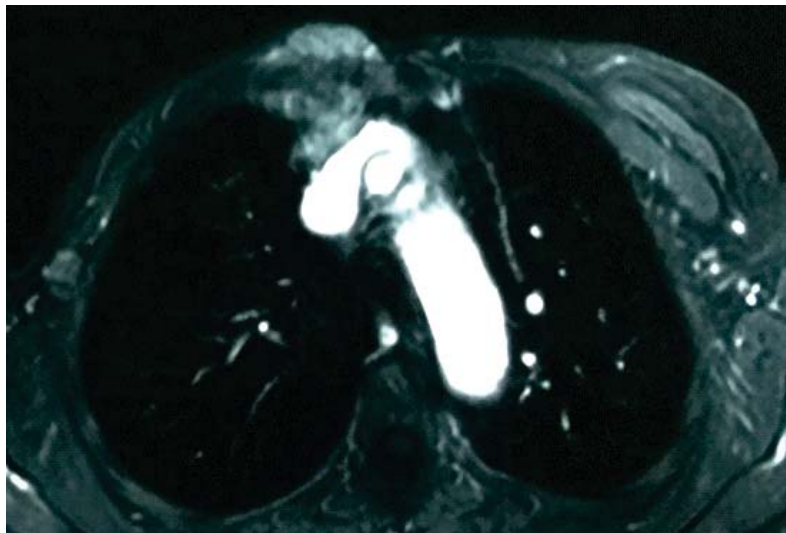

mass above the medial end of the mastectomy incision over the sternal body. There was also a 1.5 cm nodule inferior to the lateral end of the mastectomy incision. There were no palpable axillary lymph nodes on either sides.

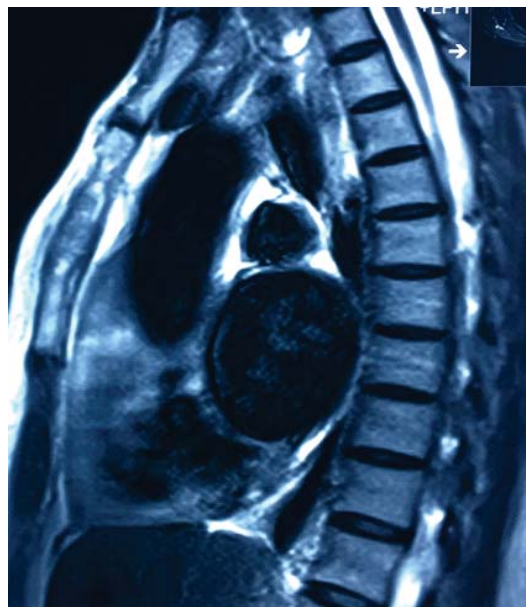
The patient had a history of valvular heart disease (mitral valve regurgitation) with atrial fibrillation and was under anticoagulant treatment with Dabigatran because she was intolerant of warfarin.

Imaging studies revealed a lobulated well-

defined heterogeneous enhancing mass on the anterior right side of the chest wall which involved the sternal body and the right side costochondral junction. The mass was in close proximity to both brachiocephalic veins but did not invade the vessels (Figures 1 and 2). Fine needle aspiration of the sternal mass and the smaller mass in the lateral part of the mastectomy incision revealed malignant cells. Core needle biopsy was not performed due to the use of Dabigatran.



**Figure 1.** Axial thoracic MRI with fat suppression and contrast injection. There is a lobulated well defined heterogeneous enhancing mass on the anterior right side of the chest wall with right side sternal body involvement and right costochondral junction invasion. The mentioned mass extends to the anterior mediastinum and has a close contact with both brachiocephalic veins without apparent signs of major mediastinal vessels extension. A prominent lymph node is also visible in the right axilla.



**Figure 2.** Thoracic MRI. Sagittal image T2 sequence without fat suppression and without contrast injection showing sternal body tumoral infiltration.

Computed tomography scans of the thorax, abdomen, and pelvis, and whole body nuclear bone scan revealed no other sites of metastasis. The treatment plan was discussed in the multidisciplinary

panel of the hospital. Considering the long term disease-free survival and the good performance status of the patient despite cardiac disease, the panel suggested surgical removal of the lesion.



The patient underwent en bloc resection of the body of the sternum and right costal cartilages involved by the mass and the skin overlying the mass. The lesion was separated from the brachiocephalic veins easily and there was no vascular invasion. After removing the sternum, the suspicious lymph node in the mediastinum was found and frozen section examination of the lymph node was performed which was reported as metastasis. There was also seeding on the pericardium; biopsies were taken from the lesions and sent for permanent pathology. The subcutaneous mass on the lateral of the chest wall was also excised with margin. The defect in the chest wall was repaired with a prolene mesh. The remnant of the right pectoral and whole left pectoral muscles were used to cover the mesh after releasing their attachments to the humerus.

The patient was transferred to the intensive care unit and was extubated on the second postoperative day. She was transferred to the ward on the third postoperative day and discharged from the hospital on the eighth post-operative day.

The pathology report revealed a 12x6.5 cm invasive carcinoma which involved the sternum and costal cartilages. All peripheral margins were free. The tumor was very close to the skin (which was removed). The lymph node of the mediastinum was involved and the lesions over the pericardium were reported as tumoral seeding. The mass on the lateral of the chest wall was also reported as invasive carcinoma. The tumor was estrogen and progesterone receptor positive on immunohistochemistry but; the HER-2 receptor was reported negative.

The patient received six courses of chemotherapy with Taxol and Carboplatin. Radiotherapy of the mediastinum and chest wall was performed and hormone therapy with Letrozole was started after chemotherapy. The patient was followed up every 3 months and was disease-free 37 months after the operation.

### Discussion

The bone is the most common site of breast cancer metastasis with reported incidence ranging from 28 to 67%.<sup>2,4,5</sup> The sternum is the third most common site of bone metastasis of breast cancer after the spine and ribs.<sup>1,2</sup> An isolated metastasis to the sternum is rare with a reported incidence of 1.9 to 2.4%.<sup>6</sup> The route of metastasis is considered to be hematogenous spread or direct invasion by enlarged internal mammary lymph nodes.<sup>7,8</sup> Some authors consider it the result of regional lymphatic tumor spread because its occurrence has no relationship with axillary lymph node metastasis and it tends to remain solitary for long periods.<sup>9-11</sup>

There has been an increasing interest in the surgical resection of the metastasis of different cancers during the past decade, especially for

malignancies of the colon and rectum, lung, breast, and melanoma. This trend of increased metastasectomy is attributed to the reports of favorable long-term outcomes of these operations.<sup>3</sup>

There are numerous reports of liver or pulmonary resection for breast cancer metastasis with favorable outcomes.<sup>12-16</sup> The treatment of an isolated metastasis to the sternum is controversial. The literature includes case reports or retrospective case series of sternectomy for the isolated recurrence of breast cancer.

Noguchi reported a series of 9 patients with isolated sternal metastasis of breast carcinoma treated by sternal resection and mediastinal and parasternal lymph node dissection followed by systemic therapy. In their series, mediastinal or parasternal lymph node involvement was an important prognostic factor and all patients with lymph node involvement died within 30 months.<sup>17</sup>

Another series of 28 cases of radical sternectomy for recurrent breast cancer reported a 10-year overall survival of 41.8% and the authors concluded that sternal resection was a safe operation which provided effective palliation and improved the quality of life.<sup>18</sup>

Koppert reported the outcome of 68 sternectomy cases including 17 cases of recurrent breast cancer. The postoperative mortality in their series was 3%. The 5-year overall survival and disease-free survival of breast cancer patients was 40% and 15%, respectively.<sup>19</sup>

Although the reports of sternectomy for recurrent breast cancer are numerous and the outcomes might be appealing, this operation should be undertaken cautiously in this setting. Lee *et al.* reported a case of a single metastasis of breast cancer to the sternum diagnosed in the postpartum period who underwent radical resection of the sternum and developed bilateral supraclavicular lymph node metastases six weeks postoperatively.<sup>7</sup> Kwai reported that 14 out of 26 patients with sternal metastasis of breast cancer developed other sites of distant metastasis during a median follow-up of 20 months.<sup>9</sup>

In conclusion, patients presenting with the isolated sternal metastasis of breast cancer should be evaluated by a multidisciplinary team and re-staging should be performed to find other sites of metastasis. In highly selected patients, resection of the sternum along with systemic therapy might provide long term relief of symptoms and favorable outcomes.

### References

1. Kakhki VR, Anvari K, Sadeghi R, Mahmoudian AS, Torabian-Kakhki M. Pattern and distribution of bone metastases in common malignant tumors. *Nucl Med Rev Cent East Eur* 2013; 16(2): 66-9.
2. Wang CY, Wu GY, Shen MJ, Cui KW, Shen Y. Comparison of distribution characteristics of



- metastatic bone lesions between breast and prostate carcinomas. *Oncol Lett* 2013; 5(1): 391-7.
- Bartlett EK, Simmons KD, Wachtel H, Roses RE, Fraker DL, Kelz RR, *et al.* The rise in metastasectomy across cancer types over the past decade. *Cancer* 2015; 121(5): 747-57.
  - Tofe AJ, Francis MD, Harvey WJ. Correlation of neoplasms with incidence and localization of skeletal metastases: An analysis of 1,355 diphosphonate bone scans. *J Nucl Med* 1975; 16(11): 986-9.
  - Wilson MA, Calhoun FW. The distribution of skeletal metastases in breast and pulmonary cancer: concise communication. *J Nucl Med* 1981; 22(7): 594-7.
  - Ohtake E, Murata H, Maruno H. Bone scintigraphy in patients with breast cancer: malignant involvement of the sternum. *Radiat Med* 1994; 12(1): 25-8.
  - Lee L, Keller A, Clemons M. Sternal resection for recurrent breast cancer: a cautionary tale. *Curr Oncol* 2008; 15(4): 193-5.
  - Chen L, Gu Y, Leaw S, Wang Z, Wang P, Hu X, *et al.* Internal mammary lymph node recurrence: rare but characteristic metastasis site in breast cancer. *BMC Cancer* 2010; 10: 479.
  - Kwai AH, Stomper PC, Kaplan WD. Clinical significance of isolated scintigraphic sternal lesions in patients with breast cancer. *J Nucl Med* 1988; 29(3): 324-8.
  - Park HM, Tarver RD. Solitary sternal metastasis from breast carcinoma. *Clin Nucl Med* 1983; 8(8): 373-4.
  - Takanami I, Ohnishi H. [Study of surgical resection of sternal metastasis from carcinoma of the breast]. *Gan No Rinsho* 1989; 35(15): 1735-8.
  - Dohba S, Kondoh M, Fujita H, Kinami S, Inoue T, Komura Y, *et al.* [A case of 19th year pulmonary metastasis after radical mastectomy for breast cancer]. *Kyobu Geka* 2000; 53(13): 1129-32.
  - Spiguel LR, Khan SA. Hepatic metastasectomy for breast cancer and melanoma: trends in highly selected patients. *Oncology (Williston Park)* 2011; 25(12): 1173-5.
  - Abbott DE, Brouquet A, Mittendorf EA, Andreou A, Meric-Bernstam F, Valero V, *et al.* Resection of liver metastases from breast cancer: estrogen receptor status and response to chemotherapy before metastasectomy define outcome. *Surgery* 2012; 151(5): 710-6.
  - Bacalbasa N, Dima SO, Purtan-Purnichescu R, Herlea V, Popescu I. Role of surgical treatment in breast cancer liver metastases: a single center experience. *Anticancer Res* 2014; 34(10): 5563-8.
  - Yin D, Zhang G, Zhao L, Chai Y. Pulmonary resection and systemic lymph node dissection in a patient with breast cancer who had a 33-year disease-free interval. *World J Surg Oncol* 2015; 13(1): 150.
  - Noguchi S, Miyauchi K, Nishizawa Y, Imaoka S, Koyama H, Iwanaga T. Results of surgical treatment for sternal metastasis of breast cancer. *Cancer* 1988; 62(7): 1397-401.
  - Lequaglie C, Massone PB, Giudice G, Conti B. Gold standard for sternectomies and plastic reconstructions after resections for primary or secondary sternal neoplasms. *Ann Surg Oncol* 2002; 9(5): 472-9.
  - Koppert LB, van Geel AN, Lans TE, van der Pol C, van Coevorden F, Wouters MW. Sternal resection for sarcoma, recurrent breast cancer, and radiation-induced necrosis. *Ann Thorac Surg* 2010; 90(4): 1102-8 e2.