



DOI: 10.32768/abc.202184277-283



Surgical Prevention of Breast Cancer-Related Lymphedema: Delayed Distal Lymphaticovenicular Anastomosis— An Alternative to the Classic LYMPHA Technique

Lynn M Orfahli^a, Tony C.T. Huang^b, Wei F Chen^{*a}^aDepartment of Plastic and Reconstructive Surgery, Cleveland Clinic Foundation, Cleveland, United States^bDivision of Plastic Surgery, Department of Surgery, Mayo Clinic, Rochester, United States

ARTICLE INFO

ABSTRACT

Received:

02 June 2021

Revised:

25 July 2021

Accepted:

26 July 2021

Keywords:

lymphedema, supermicrosurgery, lymphaticovenicular anastomosis, lymphatic reconstruction, distal delayed LVA

Breast cancer-related lymphedema (BCRL) is a devastating potential complication of axillary lymphadenectomy and radiotherapy. Several effective surgical treatment measures now exist, including lymphaticovenicular anastomosis (LVA), vascularized lymph node transplant (VLNT), and vascularized lymph vessel transplant (VLVT) for fluid-predominant disease, and liposuction and radical excision for solid-predominant disease. Super-microsurgical LVA is of particular interest, owing to its minimally invasive nature and highly favorable outcomes in the hands of experienced supermicrosurgeons. As LVA techniques are refined and improved, interest is rising in utilizing it to prevent the manifestation of disease in the first place. Lymphatic microsurgical preventive healing approach (LYMPHA), also known as immediate lymphatic reconstruction (ILR), is the most widely used approach. It involves performing axillary LVA immediately following axillary lymphadenectomy. While preliminary results are favorable, the high-pressure proximal axillary venous branches used in ILR and the site's vulnerability to damage from radiotherapy endanger the long-term patency of these anastomoses. Moreover, a theoretical oncologic concern exists regarding creating a direct conduit for the remaining malignant cells in the axilla into the circulation. Finally, coordinating ILR with axillary lymphadenectomy creates significant logistical challenges. Delayed, distally-based LVA (DD-LVA) has emerged as an alternative method that avoids these issues. This article presents an overview of the development of preemptive lymphatic reconstruction, and the senior author's approach to the novel technique of DD-LVA.

Copyright © 2021. This is an open-access article distributed under the terms of the [Creative Commons Attribution-Non-Commercial 4.0 International License](https://creativecommons.org/licenses/by-nc/4.0/), which permits copy and redistribution of the material in any medium or format or adapt, remix, transform, and build upon the material for any purpose, except for commercial purposes.

INTRODUCTION

A variety of treatment strategies are now available to target fluid-predominant lymphedema. In cases where functioning lymphatic vessels can be found, supermicrosurgical lymphaticovenicular anastomosis

(LVA) is a suitable option. When the disease process causes excessive lymphatic injury, healthy lymphatic tissue can be microsurgically transferred in the form of vascularized lymph node transplant (VLNT) or its more novel successor, vascularized lymph vessel transplant (VLVT).^{1, 2} As experience with LVA has grown, surgeons have expanded its indications to include nascent or subclinical lymphedema. It is most commonly known form, lymphatic microsurgical preventative healing approach (LYMPHA), involves performing proximal LVA immediately following mastectomy and axillary lymph node dissection.³ However, this technique is not truly “preventive” or

***Address for correspondence:**

Wei F Chen, MD, FACS

Address: Department of Plastic and Reconstructive Surgery, Cleveland Clinic Foundation, 9500 Euclid Avenue, Desk A60, Cleveland, OH 44195.

Tel: +1 216 444 5415

Fax: +1 216 444 9414

Email: weifchen@hotmail.com



“prophylactic,” because an injury to the lymphatic system has already occurred.^{4,6} Therefore, immediate lymphatic reconstruction (ILR) has been adopted by some as an alternative name.^{7,9} While preliminary results are favorable, concerns exist surrounding scheduling issues, unfavorable proximal lymphovenous pressure gradients, oncologic safety, and anastomotic injury from postoperative radiation.¹⁰ Delayed, distally-based LVA (DD-LVA) is an emerging alternative method that allows surgeons to avoid these issues. In this article, the senior author outlines his approach to LVA for subclinical, or asymptomatic, lymphedema, supplemented with a focused review of its development, techniques, outcomes, and controversies.

RESULTS AND DISCUSSION

Classic and modified techniques of immediate lymphatic reconstruction

As surgical treatment of lymphedema has been refined and improved, interest arose in using it to prevent the manifestation of this disease. In 2009, Boccardo, *et al.* published their initial report on immediate proximal LVA following axillary lymphadenectomy. Initially termed LYMPHA, it involved mapping limb-draining lymphatics with isosulfan blue and anastomosing them to branches of the axillary vein.³ At 4-year follow-up, 4% of their 74-patient cohort had developed lymphedema, versus an estimated incidence rate of 20-40% in this population at large. Rates of lymphorrhea and lymphocele, complications associated with increased regional intralymphatic pressure, were also reduced.¹¹⁻¹³

As surgeons began to adapt this technique into their own practices, a push arose to move away from the term LYMPHA. Lymphadenectomy is inherently injurious to the lymphatic system—a concept confirmed by postoperative indocyanine green (ICG) lymphographic studies of asymptomatic limbs demonstrating significant rates of subclinical lymphatic dysfunction.^{4,6} Therefore, many surgeons began describing this procedure as an immediate lymphatic reconstruction (ILR), rather than preventive or prophylactic.^{7,9}

Boccardo and colleagues' results have been replicated by several retrospective and prospective studies. A 2018 meta-analysis of 4 papers found that patients who underwent upper- or lower-extremity ILR had a relative risk of 0.33 for developing lymphedema when compared to controls ($P < 0.0001$).¹⁴ A broader 2019 meta-analysis of 19 papers found a 12% reduction in lymphedema incidence after axillary lymph node dissection (ALND) and a 23.1% reduction in lymphedema incidence after ALND combined with radiotherapy ($P = 0.029$ and 0.004 , respectively).¹⁵ While these results are encouraging, the data should be interpreted with caution. The incidence of lymphedema peaks 2

years after axillary lymph node dissection; however, many published studies utilized follow-up periods of less than 2 years. Additionally, the most common screening methods for lymphedema were volumetric measurements, circumference measurements, or clinical evaluation—none of which are adequately accurate diagnostic measures, especially in early-stage disease.^{5, 15, 16} More robust and long-term follow-up protocols are warranted to gain a true understanding of the impact of this procedure.

Immediate reconstruction combines oncologic surgery and lymphatic surgery into one event, which can be more convenient for patients. However, oncologic surgeons cannot predict the necessity of a lymphadenectomy pre-operatively. Coordinating ILR in these uncertain circumstances can cause significant scheduling difficulties for the lymphatic supermicrosurgeon. Delaying lymphatic reconstruction in a staged fashion post-lymphadenectomy alleviates this logistical burden, allowing for more optimal scheduling of this delicate procedure. While delaying LVA does require that patients return for a separate procedure, this minimally invasive technique can be performed under local anesthesia with sedation; healthy lymphatics abound in subclinical lymphedema and only one or two small incisions are needed. The literature on the outcomes of delayed LVA is limited. In 2016, Yamamoto, *et al.* published a study of 14 patients with subclinical lower extremity lymphedema (ICG dermal backflow [DB] Stage 1) who underwent preemptive LVA at the groin. One year postoperatively, 6 remained at DB Stage 1 and 8 were downstaged to Stage 0 ($P < 0.001$); subjective symptomatology was significantly reduced ($P = 0.008$).¹⁷

Classic ILR entails the use of a proximal site for anastomosis. However, this is associated with several theoretical concerns. From an oncological safety standpoint, performing LVAs in a cancer-containing field could create a direct passage for any remaining malignant cells to enter the systemic circulation. Additionally, many lymphadenectomy patients require postoperative radiotherapy; long-term LVA patency is questionable given the resultant axillary or inguinal fibrosis in these patients. Moreover, the high-pressure proximal axillary and inguinal venous branches used in proximal ILR can result in unfavorable LVA pressure gradients—the very issue that led to the inconsistent outcomes of LVA's predecessor, traditional microsurgical lymphovenous bypass (LVB) attempted in the 60s and 70s (18–23),¹⁸⁻²³ and the subsequent switch to distal locations for supermicrosurgical therapeutic LVA.²⁴⁻²⁸ If proximal anastomoses are not expected to be patent long-term following therapeutic LVA, should this be expected following preemptive LVA? Utilizing distal sites for lymphatic recon-



truction facilitates the selection of small, low-pressure venules, leading to favorable pressure gradients and antegrade lympho-venous flow. In addition, the superficial location of the distal lymphatics facilitates easier supermicrosurgical manipulation. This is especially advantageous in delayed reconstruction, as scarring and inflammation from recent lymphadenectomy and/or radiotherapy increases the difficulty of dissecting proximal lymphatic beds. Finally, creating distal LVAs keeps any potential remaining cancer cells well out-of-range of these lympho-venous connections.

After experiencing the above issues with classic IRL, the senior author began performing delayed, distally-based LVA (DD-LVA) for preemptive lymphatic reconstruction. Delaying this procedure resolves the logistical issues inherent in performing ILR following sentinel lymph node biopsy and lymphadenectomy. Because LVA is minimally invasive, it can be performed under local anesthesia as an outpatient surgery to avoid subjecting the patient to a second round of general anesthesia. By moving the anastomoses distally, damage from high-pressure proximal veins and adjuvant radiotherapy can be avoided, and the theoretical oncologic risk is mitigated.¹⁰ The limited literature on DD-LVA has demonstrated favorable preliminary results. In 2014, Onoda and colleagues described preemptive LVA of the asymptomatic contralateral limbs of ten patients with unilateral lower extremity lymph-edema. All anastomoses were created via a single incision over the ankle. Complications were limited to one case of lymphorrhea that necessitated suturing of the surgical site. Six months postoperatively, all patients remained at their preoperative Campisi stage (50%: Stage 0, 50%: Stage 1A).²⁹ While longer follow-up with robust diagnostic tools is needed to establish the efficacy of DD-LVA, these preliminary results demonstrate that this is a safe and promising alternative to prevent the consequences of this devastating disease.

DD-LVA technique – our current technique of choice

The senior author's technique for DD-LVA is as follows.^{10, 30-32}

As with any therapeutic intervention for lymphedema, proper patient evaluation and selection are paramount to the success of DD-LVA for subclinical disease. Patients with clinically overt disease (i.e., significant swelling, severe dermal backflow patterns on ICG, skin changes, cellulitis, etc.) will require stratification to therapeutic LVA, VLNT, VLVT, or debulking surgery, as previously described.^{2, 32} DD-LVA is indicated following lymphatically injurious events such as axillary/groin lymph node dissection or adjuvant radiation therapy. Patients undergo ICG lymphography 1 month postoperatively/post-radiation in order to establish a baseline. Frequently, lymphatic injury is already

detectable at this time, despite absence of swelling upon visual inspection or bioimpedance spectroscopy (BIS) measurement. Some of these patients will already be experiencing prodromes of lymphedema, such as sensations of heaviness, tightness, or generalized discomfort. Thus, establishing baseline symptomatology with a thorough history and any of the several quality of life (QoL) questionnaires is recommended.³³⁻³⁸

In overt lymphedema, the overall quality of available lymphatics is often less than ideal, especially as one moves proximally, owing to the proximal-to-distal progression of this disease.²⁵⁻²⁷ This reality necessitates planning numerous incisions, starting at the ankle or wrist, to ensure a sufficient quantity of LVAs.^{24, 28} In contrast, in subclinical lymphedema, sufficient healthy lymphatics can easily be found with only one or two incisions, and surgeons have more freedom to choose an ideal site that reliably offers high-flow lymphatic vessels. Thus, when performing DD-LVA, the senior author prefers areas adjacent to the elbow. The movement of the elbow, combined with compression between fascial layers, theoretically enhances the pumping of lymphatic fluid.^{39, 40} Superficial lymphatic vessels are mapped by injecting ICG just distal to the elbow. An infrared vein finder is used to locate veins adjacent to the mapped lymphatics, and one or two 2-3cm incisions are marked in proximity to both (Figure 1). Following this, isosulfan blue is injected 2cm distal to each marked incision to further enhance identification of lymphatic vessels. Following incision, mapped vessels are skeletonized using meticulous supermicrosurgical dissection, which ends once the underlying deep fascia is reached. The healthy state of the dissected lymphatics can be confirmed by visualization of peristalsis and of lymph fluid leak after vessel transection. The high-quality lymphatics and low-pressure distal venules used in DD-LVA create favorable lymphovenous pressure gradients. Because lymphatic pressure exceeds venous pressure, any anastomotic configuration should be successful. Thus, the technically straightforward end-to-end anastomosis is often chosen. If awkward vessel positioning, vessel number mismatch, or vessel size mismatch are encountered, more sophisticated anastomotic configurations (Figure 2) may be more appropriate.

Anastomosis is performed with 12-0 nylon on a 50µm needle; for vessels 0.5mm in diameter or larger, 11-0 nylon can be used. If the vessel lumen is too small to accommodate supermicrosurgical forceps tips, the needle tip should be used to evert the vessel edge against the side of the forceps to prevent backwalling (Figure 3). A 7-0 monofilament nylon suture can be utilized as a stent if needed. Sutures are



placed until a watertight anastomosis is achieved and to ensure that lymphatic pressure exceeds venular pressure. Following anastomosis, patency is confirmed with ICG lymphography and/or the “washout” sign (absence of blood in the venous lumen); because lymph vessel contractile function is preserved in subclinical lymphedema, this sign is

quickly and easily observed. The low number of incisions and high-quality vessels allow a relatively technically straightforward procedure; thus, operative time is generally less than 1 hour. The procedure is performed on an outpatient basis. For most patients, no narcotic pain medication is needed.

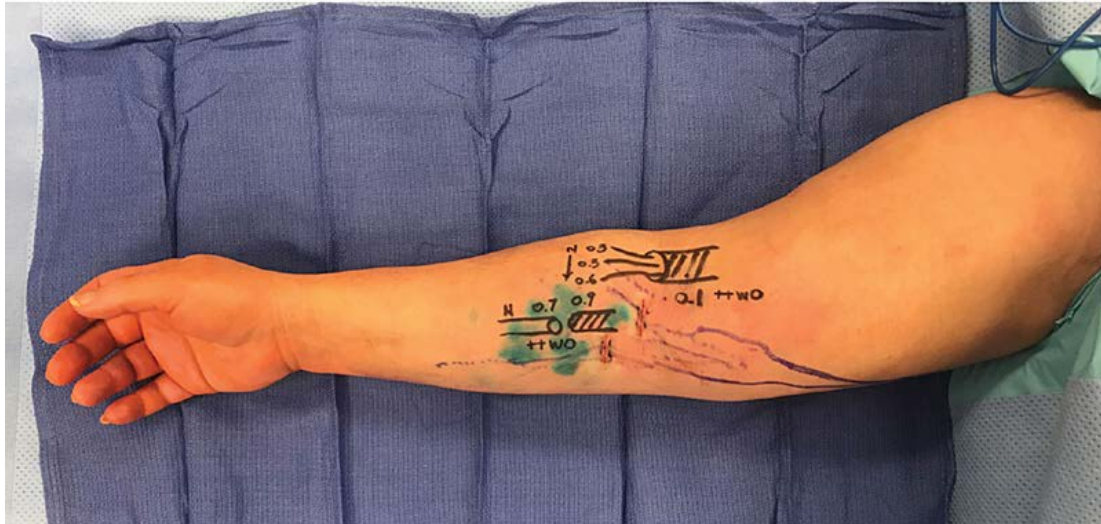

Figure 1. Following lymphatic mapping (green) with ICG lymphography and venous mapping (blue) with an infrared vein finder, 2-3 cm incisions (red) are marked near the elbow in proximity to these two structures. Dissected lymphatics are graded as normal, ectatic (mild injury), contracted (moderate injury), or sclerotic (severe injury) – in subclinical lymphedema, a sufficient quantity of healthy/normal lymphatics should be available for use. Because lymphatic vessels are sufficiently healthy, only one to two incisions are needed to create an adequate number of anastomoses. Following anastomosis, patency is confirmed with positive “washout” signs (absence of blood in the venous lumen); because lymph vessel contractile function is preserved in subclinical lymphedema, this sign is quickly and easily observed. The final anastomoses created in this patient are depicted in the diagram on the arm. Measurements of each vessel (in mm) are marked (erratum: the proximal-most vein, marked 0.1, measured 1.0mm). ICG: indocyanine green, N: normal, ++WO: briskly positive washout sign, Tubes without fill and lines: the utilized lymphatics, Tubes with dashed line fill: the utilized veins.

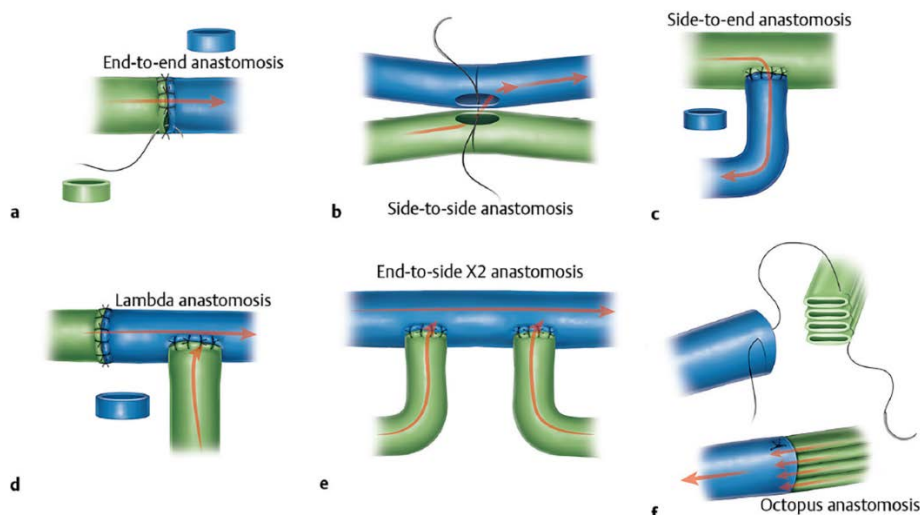


Figure 2. End-to-end anastomosis is often sufficient in LVA for subclinical lymphedema. However, several LVA configurations are available to maximize drainage pathways in the face of awkward vessel positioning, vessel size mismatch, or vessel number mismatch. Named in a lymphatic-to-vein convention: A) Simple end-to-end anastomosis; B) Side-to-side anastomosis; C) Side-to-end anastomosis; D) Lambda anastomosis; E) Double end-to-side anastomosis; F) Octopus anastomosis. We recommend that surgeons train in all of these configurations in order to efficiently address the difficult vessel positioning and size and number mismatch commonly encountered during LVA. LVA: Lymphaticovenicular anastomosis.




Figure 3. If the vessel lumen is too small to accommodate the insertion of supermicrosurgical forceps tips to prevent backwalling, this alternative method can be employed. A) The side of the forceps is used as a barrier to prevent movement of the vessel wall. B) the needle tip is used to evert the vessel edge at a point ~2 needle diameters from the edge against the side of the forceps. C) Once the edge is everted, the needle is driven through the wall.

Postoperatively, following a month of bandage compression, all patients are fitted with a 30-40mmHg circular knit compression garment. They may also commence other components of complex decongestive therapy (CDT) at this time, which can include manual lymphatic drainage (MLD) and physiotherapy.⁴¹ A 2015 Cochrane review examining the various components of CDT in subclinical lymphedema could not draw any firm conclusions about their efficacy; however, it is a low-harm intervention that we anecdotally find to be useful in this subgroup.⁴² Obesity impairs lymphatic function. Not only is it a major risk factor in the development of breast-cancer related lymphedema, but it has been shown to be an independent cause of lymphedema as well.⁴³ Therefore, weight control with diet and exercise should be incorporated into post-operative management, with the goal of achieving height- and age- appropriate weight.⁴⁴ The benefits of exercise are twofold, as it also enhances lymphatic drainage through muscle contraction.⁴⁵ However, not all exercise produces similar results. In our experience, many patients report that swimming is helpful but that walking exacerbates symptoms. This is likely because walking places arms below the level of the heart and creates centrifugal forces through arm swing. Ultimately, each patient's lymphatic drainage and production is unique; regular post-operative follow-

up is required to monitor changes and adjust non-operative treatment accordingly.

CONCLUSION

The efficacy of the procedure is monitored based on the relief of prodromal symptoms (heaviness, tightness, and discomfort) and with ICG lymphography at 3, 6, and 12 months postoperatively. Compression garments are discontinued at 3 months postoperatively if 1) the patient reports relief of prodromal symptoms and 2) ICG lymphography demonstrates sufficiently improved or resolved lymphatic injury.

Now that lymphedema can be controlled with surgical intervention, focus has expanded to the prevention of the manifestations of this devastating disease. DD-LVA offers a promising method for the prevention of symptomatic lymphedema without the theoretical risks and logistical obstacles associated with ILR. As more insight is gained into the pathophysiology of lymphedema and long-term outcomes are collected, effective patient selection and treatment planning can continue to be refined for more effective control of lymphedema.

CONFLICT OF INTEREST

The author declares no conflicts of interest.

REFERENCES

1. Chen WF, McNurlen M, Ding J, Bowen M. Vascularized lymph vessel transfer for extremity lymphedema-is transfer of lymph node still necessary? *Int Microsurg J.* 2019;3(3):1-7.
2. Orfahli LM FV, Chen WF. Vascularized lymph vessel transplant (VLVT): our experience and lymphedema treatment algorithm. *Ann Breast Surg.* 2021.
3. Boccardo F, Casabona F, De Cian F, Friedman D, Villa G, et al. Lymphedema microsurgical preventive healing approach: a new technique for primary prevention of arm lymphedema after mastectomy. *Ann Surg Oncol.* 2009;16(3):703-8.
4. Akita S, Mitsukawa N, Rikihisa N, Kubota Y, Omori N, et al. Early diagnosis and risk factors for lymphedema following lymph node dissection for gynecologic cancer. *Plast Reconstr Surg.* 2013;131(2):283-90.
5. Akita S, Nakamura R, Yamamoto N, Tokumoto H, Ishigaki T, et al. Early Detection of Lymphatic Disorder and Treatment for Lymphedema following



- Breast Cancer. *Plast Reconstr Surg.* 2016;138(2):192e-202e.
6. Yamamoto T, Matsuda N, Doi K, Oshima A, Yoshimatsu H, et al. The earliest finding of indocyanine green lymphography in asymptomatic limbs of lower extremity lymphedema patients secondary to cancer treatment: the modified dermal backflow stage and concept of subclinical lymphedema. *Plast Reconstr Surg.* 2011;128(4):314e-21e.
 7. Coriddi M, Mehrara B, Skoracki R, Singhal D, Dayan JH. Immediate Lymphatic Reconstruction: Technical Points and Literature Review. *Plast Reconstr Surg Glob Open.* 2021;9(2):e3431.
 8. Johnson AR, Singhal D. Immediate lymphatic reconstruction. *J Surg Oncol.* 2018;118(5):750-7.
 9. Cakmakoglu C, Kwiciejn GJ, Schwarz GS, Gastman B. Lymphaticovenous Bypass for Immediate Lymphatic Reconstruction in Locoregional Advanced Melanoma Patients. *J Reconstr Microsurg.* 2020;36(4):247-52.
 10. Chen WF, Knackstedt R. Delayed Distally Based Prophylactic Lymphaticovenular Anastomosis: Improved Functionality, Feasibility, and Oncologic Safety? *J Reconstr Microsurg.* 2020;36(9):e1-e2.
 11. Boccardo F, Casabona F, De Cian F, Friedman D, Murelli F, et al. Lymphatic microsurgical preventing healing approach (LYMPHA) for primary surgical prevention of breast cancer-related lymphedema: over 4 years follow-up. *Microsurgery.* 2014;34(6):421-4.
 12. DiSipio T, Rye S, Newman B, Hayes S. Incidence of unilateral arm lymphoedema after breast cancer: a systematic review and meta-analysis. *Lancet Oncol.* 2013;14(6):500-15.
 13. Shaitelman SF, Chiang YJ, Griffin KD, DeSnyder SM, Smith BD, et al. Radiation therapy targets and the risk of breast cancer-related lymphedema: a systematic review and network meta-analysis. *Breast Cancer Res Treat.* 2017;162(2):201-15.
 14. Jorgensen MG, Toyserkani NM, Sorensen JA. The effect of prophylactic lymphovenous anastomosis and shunts for preventing cancer-related lymphedema: a systematic review and meta-analysis. *Microsurgery.* 2018;38(5):576-85.
 15. Johnson AR, Kimball S, Epstein S, Recht A, Lin SJ, et al. Lymphedema Incidence After Axillary Lymph Node Dissection: Quantifying the Impact of Radiation and the Lymphatic Microsurgical Preventive Healing Approach. *Ann Plast Surg.* 2019;82(4S Suppl 3):S234-S41.
 16. Chen WF, Zhao H, Yamamoto T, Hara H, Ding J. Indocyanine Green Lymphographic Evidence of Surgical Efficacy Following Microsurgical and Supermicrosurgical Lymphedema Reconstructions. *J Reconstr Microsurg.* 2016;32(9):688-98.
 17. Yamamoto T, Yamamoto N, Yamashita M, Furuya M, Hayashi A, et al. Efferent Lymphatic Vessel Anastomosis: Supermicrosurgical Efferent Lymphatic Vessel-to-Venous Anastomosis for the Prophylactic Treatment of Subclinical Lymphedema. *Ann Plast Surg.* 2016;76(4):424-7.
 18. Gilbert A, O'Brien BM, Vorrath JW, Sykes PJ. Lymphaticovenous anastomosis by microvascular technique. *Br J Plast Surg.* 1976;29(4):355-60.
 19. Nielubowicz J, Olszewski W. Surgical lymphaticovenous shunts in patients with secondary lymphoedema. *Br J Surg.* 1968;55(6):440-2.
 20. Ti-Sheng C, Liang-Yu H, Wei W, Wen-Yi H. *Microsurgery for Lymphedema and Lymphatics.* Princ Tech Appl Microsurg: World Scientific; 1986. p. 331-62.
 21. Yamada Y. The studies on lymphatic venous anastomosis in lymphedema. *Nagoya J Med Sci.* 1969;32(1):1-21.
 22. Laine JB, Howard JM. Experimental Lymphaticovenous Anastomosis. *Surg Forum.* 1963;14:111-2.
 23. O'Brien BM, Sykes P, Threlfall GN, Browning FS. Microlymphaticovenous anastomoses for obstructive lymphedema. *Plast Reconstr Surg.* 1977;60(2):197-211.
 24. Koshima I, Inagawa K, Urushibara K, Moriguchi T. Supermicrosurgical lymphaticovenular anastomosis for the treatment of lymphedema in the upper extremities. *J Reconstr Microsurg.* 2000;16(6):437-42.
 25. Koshima I, Kawada S, Moriguchi T, Kajiwara Y. Ultrastructural observations of lymphatic vessels in lymphedema in human extremities. *Plast Reconstr Surg.* 1996;97(2):397-405; discussion 6-7.
 26. Mihara M, Hara H, Hayashi Y, Narushima M, Yamamoto T, et al. Pathological steps of cancer-related lymphedema: histological changes in the collecting lymphatic vessels after lymphadenectomy. *PLoS One.* 2012;7(7):e41126.
 27. Mihara M, Hara H, Kawakami Y, Zhou HP, Tange S, et al. Site-Specific Evaluation of Lymphatic Vessel Sclerosis in Lower Limb Lymphedema Patients. *Lymphat Res Biol.* 2018;16(4):360-7.
 28. Nagase T, Gonda K, Inoue K, Higashino T, Fukuda N, et al. Treatment of lymphedema with lymphaticovenular anastomoses. *Int J Clin Oncol.* 2005;10(5):304-10.
 29. Onoda S, Todokoro T, Hara H, Azuma S, Goto A. Minimally invasive multiple lymphaticovenular anastomosis at the ankle for the prevention of lower leg lymphedema. *Microsurgery.* 2014;34(5):372-6.
 30. Chen WF. How to Get Started Performing Supermicrosurgical Lymphaticovenular Anastomosis to Treat Lymphedema. *Ann Plast Surg.* 2018;81(6S Suppl 1):S15-S20.



31. Chen WF, Tuncer FB, Zeng W. Advanced Technical Pearls for Successful Supermicrosurgical Lymphaticovenular Anastomosis. *Ann Plast Surg.* 2021;86(3S Suppl 2):S165-S72.
32. Chen WF MM, Bowen M. . Surgical Treatments of Lymphedema. In: Jones GE, editor. *Bostwick's Plastic and Reconstructive Breast Surgery.* Fourth. New York: Thieme Medical Publishers. 2020:1478-99.
33. Armer JM, Radina ME, Porock D, Culbertson SD. Predicting breast cancer-related lymphedema using self-reported symptoms. *Nurs Res.* 2003;52(6):370-9.
34. Bulley C, Coutts F, Blyth C, Jack W, Chetty U, et al. A Morbidity Screening Tool for identifying fatigue, pain, upper limb dysfunction and lymphedema after breast cancer treatment: a validity study. *Eur J Oncol Nurs.* 2014;18(2):218-27.
35. Chen WF, Yamamoto T, Fisher M, Liao J, Carr J. The "Octopus" Lymphaticovenular Anastomosis: Evolving Beyond the Standard Supermicrosurgical Technique. *J Reconstr Microsurg.* 2015;31(6):450-7.
36. Coster S, Poole K, Fallowfield LJ. The validation of a quality-of-life scale to assess the impact of arm morbidity in breast cancer patients post-operatively. *Breast Cancer Res Treat.* 2001;68(3):273-82.
37. Keeley V, Crooks S, Locke J, Veigas D, Riches K, et al. A quality-of-life measure for limb lymphoedema (LYMQOL). *J Lymphoedema.* 2010;5(1):26-37.
38. Ridner SH, Dietrich MS. Development and validation of the Lymphedema Symptom and Intensity Survey-Arm. *Support Care Cancer.* 2015;23(10):3103-12.
39. Seki Y, Kajikawa A, Yamamoto T, Takeuchi T, Terashima T, et al. Single Lymphaticovenular Anastomosis for Early-Stage Lower Extremity Lymphedema Treated by the Superior-Edge-of-the-Knee Incision Method. *Plast Reconstr Surg Glob Open.* 2018;6(2):e1679.
40. Seki Y, Yamamoto T, Yoshimatsu H, Hayashi A, Kurazono A, et al. The Superior-Edge-of-the-Knee Incision Method in Lymphaticovenular Anastomosis for Lower Extremity Lymphedema. *Plast Reconstr Surg.* 2015;136(5):665e-75e.
41. Schaverien MV, Moeller JA, Cleveland SD. Nonoperative Treatment of Lymphedema. *Semin Plast Surg.* 2018;32(1):17-21.
42. Stuiver MM, ten Tusscher MR, Agasi-Idenburg CS, Lucas C, Aaronson NK, et al. Conventional interventions for preventing clinically detectable upper-limb lymphoedema in patients who are at risk of developing lymphoedema after breast cancer therapy. *Cochrane Database Syst Rev.* 2012(4).
43. Sudduth CL, Greene AK. Current Overview of Obesity-Induced Lymphedema. *Adv Wound Care (New Rochelle).* 2021.
44. Nitti MD, Hespe GE, Kataru RP, García Nores GD, Savetsky IL, et al. Obesity-induced lymphatic dysfunction is reversible with weight loss. *J Physiol.* 2016;594(23):7073-87.
45. Garza R, 3rd, Skoracki R, Hock K, Povoski SP. A comprehensive overview on the surgical management of secondary lymphedema of the upper and lower extremities related to prior oncologic therapies. *BMC Cancer.* 2017;17(1):468.

How to Cite This Article

Orfahli LM, Huang CT, Chen WF. Surgical Prevention of Breast Cancer-Related Lymphedema: Delayed Distal Lymphaticovenular Anastomosis– An Alternative to the Classic LYMPHA Technique. *Arch Breast Cancer.* 2021; 16(4):277-283

Available from: <https://www.archbreastcancer.com/index.php/abc/article/view/431>