



DOI: 10.32768/abc.202184338-341



Pure Mucinous Breast Carcinoma with Micropapillary Pattern in a 32-Year-Old Female

Nahid Sadighi^a, Razieh Shahnazari^{*b}, Fariba Asadi^a

^aDepartment of Radiology, Tehran University of Medical Sciences, Tehran, Iran

^bDepartment of Radiology, Iran University of Medical Sciences, Tehran, Iran

ARTICLE INFO

Received:

07 March 2021

Revised:

01 July 2021

Accepted:

06 July 2021

Keywords:

Breast,
Mucinous Carcinoma,
pure type,
mixed type

ABSTRACT

Background: Mucinous carcinoma (MC) is a rare breast malignancy with a large extracellular mucin secretion. It has a good prognosis in comparison to other breast malignancies.

Case presentation: We report a 32 years old female with multiple hard palpable masses in the left breast with rapid growth in 6 months. She was mentally retarded with lower limb varicose veins associated with mucocutaneous lesions on the face. She underwent ultrasound examination of the breast, thyroid and lower extremity veins. Core needle biopsy and fine needle aspiration from left breast lesions and right thyroid nodules showed MC and follicular lesion with hurtle cell change, respectively. Suspected metastasis in the left rib and calvarium in the subsequent bone scan survey and brain magnetic resonance imaging was reported. She underwent radical mastectomy and right hemi-thyroidectomy.

Conclusion: Pure mucinous carcinoma with micropapillary pattern (MUMPC) is a new histology variant of Pure Mucinous Carcinoma (PMC) that shows favorable prognosis with less aggression and occurs in older patients. However, PMC in our patient occurred at a young age with greater aggression.

Copyright © 2021. This is an open-access article distributed under the terms of the [Creative Commons Attribution-Non-Commercial 4.0 International License](https://creativecommons.org/licenses/by-nc/4.0/) which permits copy and redistribution of the material in any medium or format or adapt, remix, transform, and build upon the material for any purpose, except for commercial purposes.

INTRODUCTION

Mucinous carcinoma, also called Colloid carcinoma¹, is an uncommon type of breast carcinoma classified as pure and mixed subtypes. It occurs mostly in older patients (7% in older versus 1% in younger patients).¹⁻³

The pure subtype is more likely to be well circumscribed, lobulated, and soft according to the percentage of mucin in tumor tissue composition. In contrast, the mixed type is larger and more palpable upon examination, is ill-defined, and is associated with microlobulation, necrosis and microcalcification in the ultrasound. The pure type occurs at younger age with

good prognosis in comparison to mixed type.¹⁻⁴ Lymph node involvement in the pure type is about 2 to 14%, compared to approximately 46 to 64% in the mixed type.² The five-year survival rate in the pure type is near 90% versus 60% in the mixed type¹. MUMPC is a new histology variant of PMC with tumor cells forming a micropapillary architecture that accounts for about 12-35% of all PMC.⁵ We studied a 32 year old female suffering from left breast MUMPC with unusual manifestation as calcification and cystic changes as well as suspected bone metastasis.

CASE PRESENTATION

A 32-year-old female with mental retardation was referred to the breast radiology department in Imam Khomeini Hospital with complaints of multiple firm lumps in her left breast over the preceding 6 months with progressive distribution from one quadrant to involvement of the whole breast. She was mentally

*Address for correspondence:

Razieh Shahnazari, MD

Address: Department of Radiology, Iran University of Medical Sciences, Tehran, Iran

Tel: +989133298736

Email: Rsh.medicen1999@gmail.com



retarded and tall (190cm) with multiple pigmentations on the face and bilateral lower limbs varicose and twisted veins with skin discoloration from several

years ago (Figure 1). Her familial history was unremarkable.

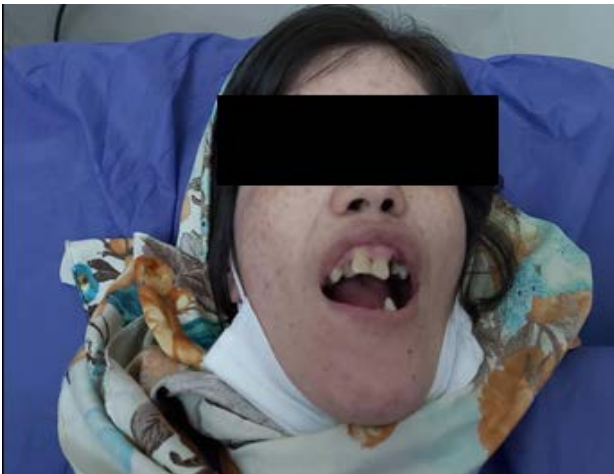
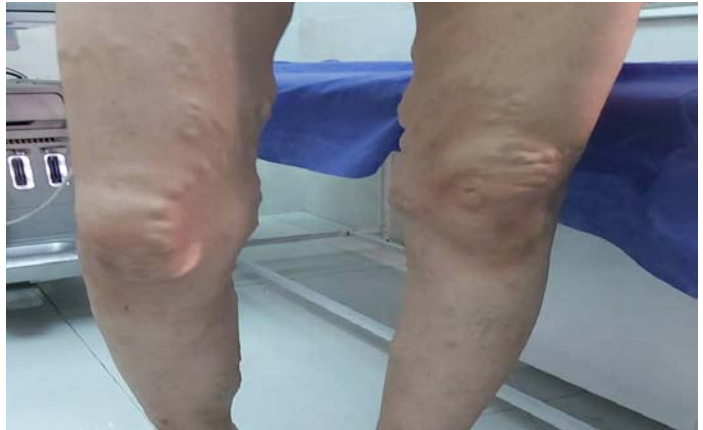
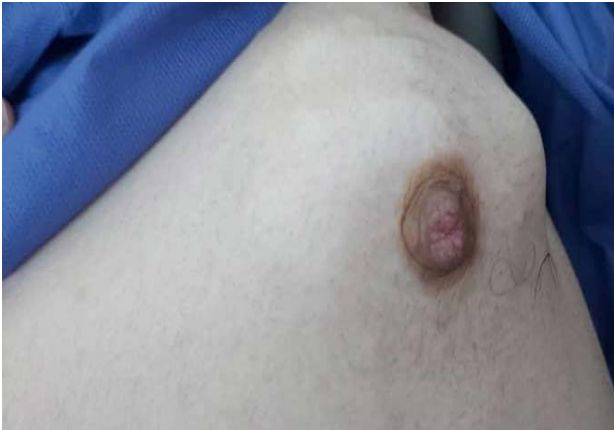Figure 1. A 32-year-old female with hard palpable mass in the left breast (a) with bilateral varicose veins in lower limbs (b) and freckles on the face (c).

The ultrasonography (US) showed multiple varying size hypoechoic solid and cystic masses (4cm to 10.5cm) showing angular, micro-lobulated and spiculated margins and acoustic shadowing with duct extension, branch pattern with thick echogenic halo

associated with macrocalcification from areolar margin to the far zone of the whole left breast. Some cystic and mucocele-like masses had vascularity in color doppler ultrasound. Lymph node involvement was not detected in the US (Figure 2).

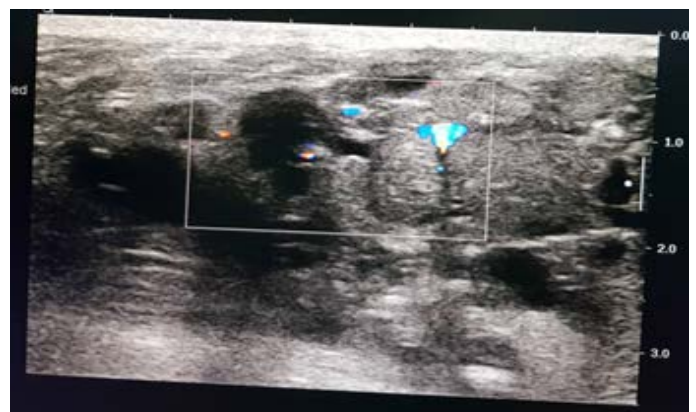
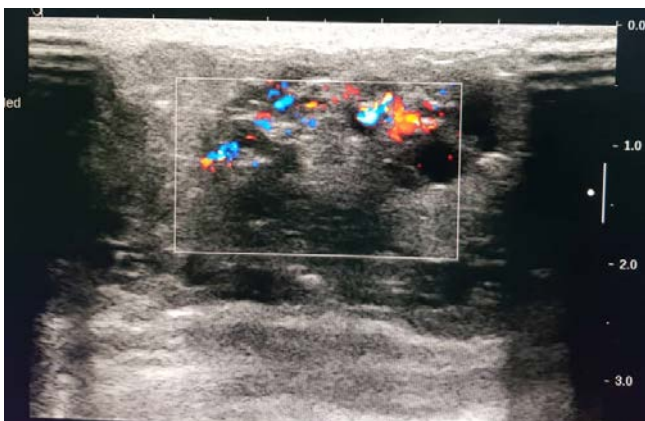


Figure 2. Supersonic ultrasonography images depict solid cystic, irregular and hypoechoic vascular mass (a) with duct extension and twinkling artifact due to calcification (b).

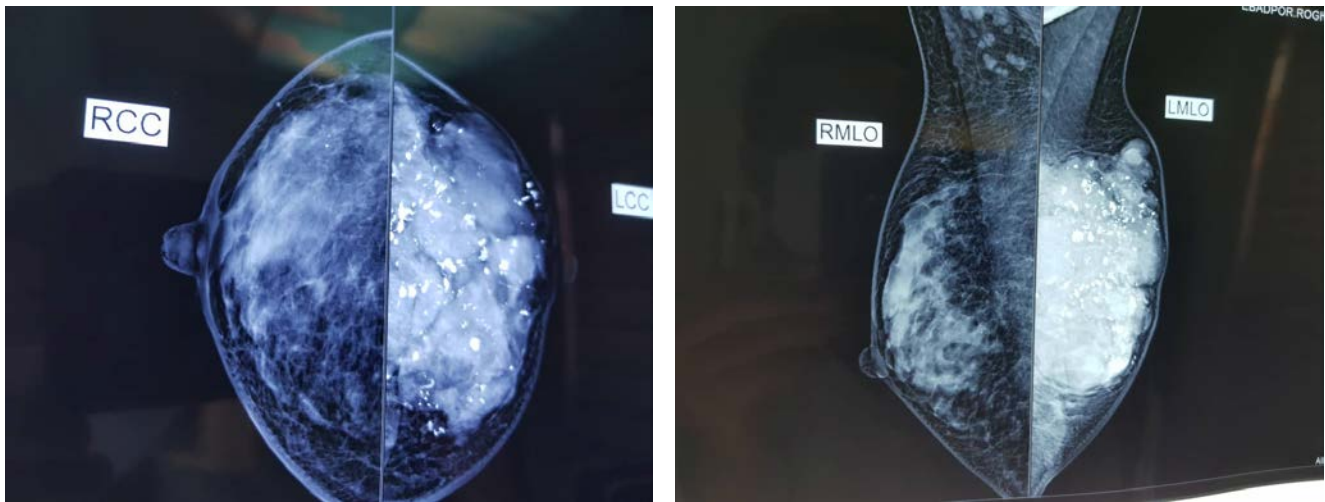


Figure 3. Craniocaudal(a) and mediolateral oblique(b) views of mammography show multiple hyperdense irregular shapes and margin lesions with coarse macrocalcification and a few coarse heterogenous microcalcifications.

Mammographic findings were multiple hyperdense irregular shape with micro-lobulated margin with coarse macrocalcification and a few coarse heterogenous microcalcifications with diffuse distribution (Figure 3). Subsequently, core needle biopsy showed MC with morphologic feature as well as IHC survey. IHC results were strongly positive for estrogen receptor (ER), weakly positive for progesterone receptor (PR), and negative for Herceptin receptor 2 (HER-2); the KI67 was positive in 20 percent of cells.

Whole body bone scans showed suspected bone metastasis in the anterior arc of left 6th rib. In Brain MRI, suspected calvarium metastasis was detected. Due to the non-cooperation of the patient and the dissatisfaction of her family, further evaluation to confirm bone metastasis was not performed.

During the examination of the patient's breast, we noticed that the patient's thyroid was prominent, so we also did a thyroid ultrasonography. Two solid-cystic nodules with comet-tail artifact in the right lobe were seen that underwent FNA. pathologic evaluation showed follicular lesion with hurtle cell change. The patient underwent radical left mastectomy and left axillary lymph nodes dissection with right hemithyroidectomy. Surgical pathology reports showed MUMPC in the left breast. Macroscopic features of the tumor were tan-whitish color and gelatinous cut surface. It was multi-cystic with an area of solid component with the size of 10.5*8*4 centimeter at all quadrants of the left breast. Overall, the histologic grade was determined to be 1 with glandular differentiation score: 2, nuclear pleomorphism score: 2, mitotic score: 1.

Lymphovascular invasion was reported. Axillary nodal involvement and dermal lymphovascular invasion or necrosis were not detected. Pathologic stage was pT3pN0. Thyroid surgical pathology report

was multinodular thyroid goiter and lymphocytic thyroiditis in the right thyroid lobe.

DISCUSSION

Breast cancer is probably the most common tumor in patients with intellectual disability (ID). The mean age of intellectually disabled women with breast cancer is lower than in the general population with breast cancer. Tumor size, lymph node involvement, and distant metastasis are more common in ID patients than in the general population. The detection of breast cancer in patients with ID is delayed due to the difficulty of clinical examination and communication problems and the lack of pain diagnosis by caregivers.⁶⁻⁸ All of the above were the cause of our patient's advanced breast cancer. Due to the concurrence of breast cancer and thyroid abnormality, mucocutaneous lesions, vascular and mental retardation in the patient, we suspected Cowden syndrome. The clinical criteria for the diagnosis of Cowden syndrome are one of the following: three major criteria or two major criteria and three minor criteria.⁹ Our patient had one definitive major criterion (breast cancer). Mucocutaneous lesions are part of the major criteria but her family did not allow skin biopsy. Mental retardation and multinodular goiter and vascular anomalies of the patient constituted minor criteria. We needed one major criterion for definitive Cowden syndrome diagnosis. Due to the dissatisfaction of the patient's family, evaluation of gastrointestinal tract for colon cancer and hamartoma was not performed. Our patient was younger than the average age of pure type patients with suspected bone metastasis. Cystic changes and calcification and distant metastasis in the pure type are unusual,^{2-5, 10} but we detected these rare manifestations of the pure type in our patient. Differential diagnosis of PMC is invasive micropapillary carcinoma (IMPC) with associated mucin production. If MUMPC presents pathological



characteristics suggestive of PMC, biologically it is called IMPC. PMC and MUMPC have favorable prognosis, unlike IMPC. MUMPC has an IMPC-like form in the clinic with lymphovascular and lymph node invasion in pathology.⁵ The association between Cowden syndrome and bone lesions has not been described in the literature. Therefore, we related the patient's bone lesions to breast cancer. Bone is the most common site for breast cancer metastasis but the frequency of the bone metastasis in MC was not well known and a few case reports have been published.^{11, 12} Finally, our patient who suffered from MUMPC, possible Cowden syndrome, and suspected bone metastasis showed unusual manifestations of PMC.

CONCLUSION

Pure MUMPC is a new subtype of PMC with good manifestation and prognosis. It occurs mostly in older

patients. although, PMC in our patient occurred at a young age with unusual behavior.

ACKNOWLEDGEMENT

We thank Tehran University of Medical Science and Imam Khomeini Hospital for providing us with data and facilities to conduct this study.

CONFLICT OF INTEREST

The three authors have contributed sufficiently to the project to be included as authors. No conflict of interest, financial or other, exists for all authors.

ETHICAL CONSIDERATION

A written consent was signed by the patient to present her documents and images in this journal.

REFERENCES

1. Luna-Abanto J, Mendoza Tisoc G. Mucinous carcinoma of the breast: a case report and review of the literature. *Medwave*. 2017;17(6):e7003.
2. Bitencourt AG, Graziano L, Osorio CA, Guatelli CS, Souza JA, et al. MRI Features of Mucinous Cancer of the Breast: Correlation With Pathologic Findings and Other Imaging Methods. *AJR Am J Roentgenol*. 2016;206(2):238-46.
3. Chaudhry AR, El Khoury M, Gotra A, Eslami Z, Omeroglu A, et al. Imaging features of pure and mixed forms of mucinous breast carcinoma with histopathological correlation. *Br J Radiol*. 2019;92(1095):20180810.
4. Iqbal BM, Banerjee B. Mucinous carcinoma of breast in a 30-year-old female: A rare case report and discussion. *Clin Cancer Investig J*. 2016;5(5):489.
5. Asano Y, Kashiwagi S, Nagamori M, Tanaka S, Kuwae Y, et al. Pure Mucinous Breast Carcinoma with Micropapillary Pattern (MUMPC): A Case Report. *Case Rep Oncol*. 2019;12(2):554-9.
6. Davies N, Duff M. Breast cancer screening for older women with intellectual disability living in community group homes. *J Intellect Disabil Res*. 2001;45(Pt 3):253-7.
7. Satgé D, Sauleau E-A, Jacot W, Raffi F, Azéma B, et al. Age and stage at diagnosis: a hospital series of 11 women with intellectual disability and breast carcinoma. *BMC cancer*. 2014;14(1):1-6.
8. Truesdale-Kennedy M, Taggart L, McIlpatrick S. Breast cancer knowledge among women with intellectual disabilities and their experiences of receiving breast mammography. *J Adv Nurs*. 2011;67(6):1294-304.
9. Eng C. Will the real Cowden syndrome please stand up: revised diagnostic criteria. *J Med Genet*. 2000;37(11):828-30.
10. Dumitru A, Procop A, Iliesiu A, Tampa M, Mitrache L, et al. Mucinous Breast Cancer: a Review Study of 5 Year Experience from a Hospital-Based Series of Cases. *Maedica (Bucur)*. 2015;10(1):14-8.
11. Chen WZ, Shen JF, Zhou Y, Chen XY, Liu JM, et al. Clinical characteristics and risk factors for developing bone metastases in patients with breast cancer. *Sci Rep*. 2017;7(1):11325.
12. Dogan E, Aksoy S, Dizdar O, Arslan C, Dede DS, et al. Pure mucinous carcinoma of the breast: a single center experience. *J BUON*. 2011;16(3):565-7.

How to Cite This Article

Sadighi N, Shahnazari R, Asadi R. Pure Mucinous Breast Carcinoma with Micropapillary Pattern in a 32-Year-Old Female. *Arch Breast Cancer*. 2021; 16(4):338-341.

Available from: <https://www.archbreastcancer.com/index.php/abc/article/view/384>