



DOI: 10.32768/abc.202182143-148

Pre-Operative Localization of Axillary Lymph Nodes with Tattoo Ink: A Preliminary Report

Kelly S Myers^{*a}, Sachin Aggarwal^a, Eniola T Oluyemi^a, Mehran Habibi^b, Emily B Ambinder^a, Armina Azizi^a, Parvinder Sujlana^a, Jessica Hung^a, Nagi Khouri^a, David Eisner^a, Philip A Di Carlo^a, Ashley M Cimino-Mathews^c, Melissa S Camp^b

^a Department of Radiology, Johns Hopkins School of Medicine, Baltimore, Maryland, USA

^b Department of Surgery, Johns Hopkins School of Medicine, Baltimore, Maryland, USA

^c Department of Pathology, Johns Hopkins School of Medicine, Baltimore, Maryland, USA

ARTICLE INFO

Received:
19 February 2021
Revised:
09 March 2021
Accepted:
11 March 2021

Key words:

Axilla,
sentinel Lymph node,
pre-operative localization,
ink,
interventional ultrasonography

ABSTRACT

Background: Pre-operative localization options in the axilla are limited. This study aimed to explore the utility of pre-operative localization of axillary lymph nodes using tattoo ink with multidisciplinary correlations.

Methods: In this prospective, Institutional Review Board (IRB)-approved study, 19 lymph nodes in 17 patients underwent pre-operative localization with ultrasound-guided injection of Spot tattoo ink. The success rate of intraoperative identification of the tattooed node as well as the frequency in which the tattooed node was also a sentinel node were recorded. Radiologic, surgical and pathologic images were collected.

Results: Tattoo ink localization was successful in 16/17 (94.1%) of patients. Tattoo ink did not hinder pathologic evaluation in any cases but was taken up by additional adjacent nodes in 1/17 successful localizations (5.9%). Successful sentinel lymph node biopsy (SLNB) occurred in 13 patients in whom 14 lymph nodes underwent pre-operative tattoo ink localization. Nine of the 14 (64.2%) tattooed lymph nodes were also a sentinel node.

Conclusion: In this study, pre-operative localization of axillary lymph nodes with tattoo ink was highly successful. In patients undergoing SLNB, a significant number of the tattooed nodes were not sentinel nodes (35.8%), suggesting the importance of targeted lymph node excision in addition to SLNB.

Introduction

Pre-operative localization of axillary lymph nodes is often desired. For example, localization may ensure that a previously biopsied lymph node is excised, which is especially important in patients undergoing neoadjuvant chemotherapy in order for pathologic

response to be fully assessed. However, options for pre-operative localization in the axilla are limited. Historically at our institution, in the absence of pre-operative localization of previously biopsied lymph nodes, the excised lymph nodes are evaluated with an intraoperative specimen radiograph to confirm the presence of a biopsy clip. This method, however, is limited as it does not provide targeted localization. While hook wires are commonly used for localization for findings in the breast, there is only a small amount of data regarding the safety and reliability of hook wires in the axilla.¹⁻³ Other options such as radioactive ¹²⁵I seeds, MagSeed and Tag localizations have additional limitations, as they require special

* Address for correspondence:

Kelly S Myers, MD
Johns Hopkins School of Medicine, Department of Radiology
601 N Caroline St, Baltimore, MD, 21287, USA
Tel: 410-955-7095
Fax: 410-614-7663
Email: kmyers25@jhmi.edu



equipment and are costly.³⁻⁷ Ultrasound-guided injection of tattoo ink has emerged as a safe, widely-available, cost-effective technique for labeling specific lymph nodes for which excision is desired.⁸⁻¹⁵

Multiple previous studies have reported experience with ultrasound-guided injection of tattoo ink into targeted axillary lymph nodes using Charcotrace (Phebra, Sydney, Australia) or Spot endoscopic marker (GI Supply, Camp Hill, PA) with sample sizes ranging from 20 to 75 patients.⁸⁻¹⁵ All of these studies report a 100% technical success rate of the injection procedure and no adverse outcomes. Additionally, all studies report a high success rate of visualization of the tattooed lymph node intra-operatively, with success rates ranging from 96.4-100%. Several studies report that the tattoo ink spilled to several additional axillary lymph nodes; however, this was predominantly in studies where the injection procedure occurred weeks to months prior to surgery.⁹⁻¹¹ Among three studies in which the injection was performed on the day of or the day prior to surgery, two did not report this finding^{13,14}, and one reported occasional spilling of tattoo ink into lymph nodes along the injection track.¹² In previous studies using a tattoo ink in patients also undergoing sentinel lymph node biopsy (SLNB), the tattooed lymph node was also a sentinel node in 58-98.5% of cases.⁸⁻¹⁵

The aim of this prospective study was to report the success rate of pre-operative localization of axillary lymph nodes using ultrasound-guided injection of tattoo ink and to provide direct surgical and pathologic correlation. Additionally, in patients undergoing SLNB, the frequency in which the tattooed lymph node corresponded to a sentinel lymph node was also evaluated.

Methods

In this prospective, Health Insurance Portability and Accountability Act (HIPAA)-compliant, Institutional Review Board-approved study, 17 patients with 19 axillary lymph nodes participated after providing written informed consent from August 1, 2018 to March 10, 2020. All patients aged 18 years or older with one or more axillary lymph nodes for which pre-operative localization with tattoo ink was desired by the breast surgeon were eligible. At our institution, Hydromark biopsy clips are routinely placed at the time of ultrasound guided biopsy of axillary lymph nodes in order to guide future ultrasound-guided localization if needed. Ultrasound-guided injection of 0.1-0.5 ml Spot endoscopic marker (GI Supply, Camp Hill, PA) into the cortex of the target lymph node was performed on the day of surgery (n=17) or the day before surgery (n=2) by one of nine radiologists specialized in breast imaging. With the patient in the surgical position, the skin overlying the inked lymph node was marked with a sterile surgical marker.

In the 14 patients undergoing sentinel lymph

node biopsy (SNLB), dual tracing was used (both Tc^{99m} and blue dye). For the Tc^{99m} tracer, approximately 1 mCi was injected subdermally at the areolar margin 2-24 hours prior to surgery. For the blue dye, 5 cc of Lymphazurin blue dye was injected into the retroareolar location of the breast after induction of anesthesia. After entry into the axillary space, using a gamma probe and visual inspection, all identifiable hot, blue and inked nodes were resected. Intraoperative specimen radiograph of the resected lymph nodes was performed to evaluate for presence of a previously placed biopsy clip, if indicated.

Tattoo ink localization was considered technically successful if the breast surgeon was able to visually identify the black tattooed lymph node intra-operatively. In those patients undergoing SLNB, the breast surgeon reported whether the tattooed node was also a sentinel node (hot and/or blue in addition to containing tattoo ink). All lymph nodes and associated surgically resected breast specimens were sent to surgical pathology for routine, standard of care processing, histologic evaluation, and diagnosis. At the initiation of this study, the pathology slides of the tattooed lymph nodes from the first several study patients were reviewed by the study pathologist (board-certified pathologist specializing in breast pathology) to confirm that the tattoo ink did not interfere with the diagnostic interpretation, before additional patients were accrued. A representative sample of at least four tattooed lymph nodes was also evaluated histologically at the conclusion of the study.

Descriptive statistics including success rate of pre-operative localization with the tattoo ink and the percent of tattooed nodes that were also sentinel nodes were calculated using SPSS version 26 (IBM, Armonk NY).

Results

Study Population

Seventeen patients with 19 axillary lymph nodes for which pre-operative localization was desired by the breast surgeon gave written informed consent and were included in the study. While most patients underwent tattoo ink injection for a single specific lymph node, two patients underwent tattoo ink injection into two lymph nodes. Mean patient age was 56 years (standard deviation 14.1 years, range 28 to 81). Mean body mass index (BMI) was 28.5 (standard deviation 7.3). Sixteen of the 17 patients (94.1%) were female. Fifteen of the 17 patients (88.2%) had a diagnosis of breast cancer, one patient had a diagnosis of melanoma and one patient had a core biopsy of an axillary lymph node suspicious for B cell lymphoma. Of the 15 breast cancer patients, 11 (73.3%) underwent neoadjuvant chemotherapy or neoadjuvant immunotherapy prior to the localization procedure and SNLB. Sixteen of the 19 (84.2%) targeted lymph nodes had previously



undergone an ultrasound-guided core biopsy.

Success Rate of Tattooed Node Localization

Ultrasound-guided injection of tattoo ink into the cortex of the target lymph node was successful for all 19 nodes (Figure 1). There were no reported complications from the localization procedure. Seventeen of the 19 lymph nodes (89.5%) were identified intra-operatively (Figure 2). The two lymph nodes that were not identified intra-

operatively were in the same patient and were not identified due to diffuse seepage of tattoo ink in the adjacent tissues. In one patient, the ink had diffused into the surrounding tissues with three lymph nodes containing tattoo ink (including the targeted lymph node). This localization was considered successful as the targeted node could be identified and excised. Therefore, tattoo ink localization was successful in 16/17 (94.1%) of patients.

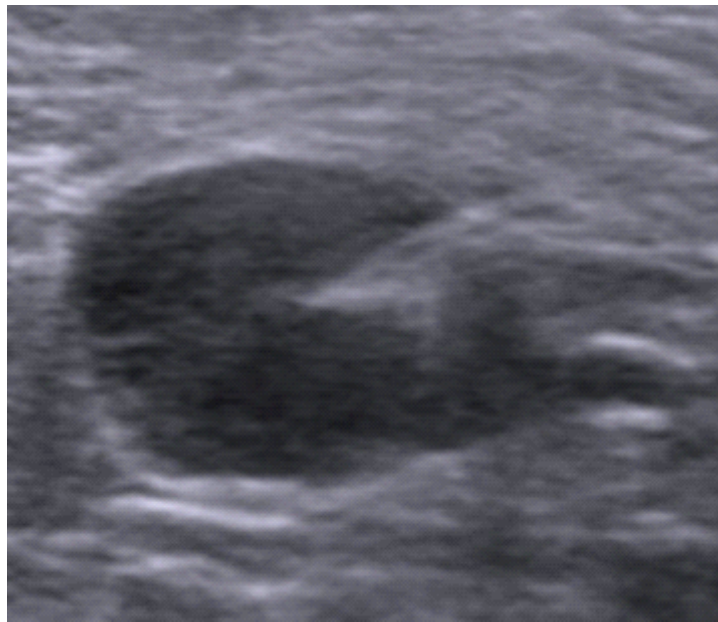


Figure 1. Pre-operative localization with tattoo ink: 67-year-old female with right breast cancer and biopsy proven metastasis to a right axillary lymph node. Ultrasound image demonstrates ultrasound-guided injection of Spot tattoo ink into the cortex of the previously biopsied lymph node. The tattooed lymph node was visually identified as a black lymph node intra-operatively, and surgical pathology confirmed metastatic carcinoma involving the lymph node with biopsy site changes. However, the tattooed node was not a sentinel node. The patient also underwent sentinel lymph node biopsy which yielded 0/1 positive lymph nodes.

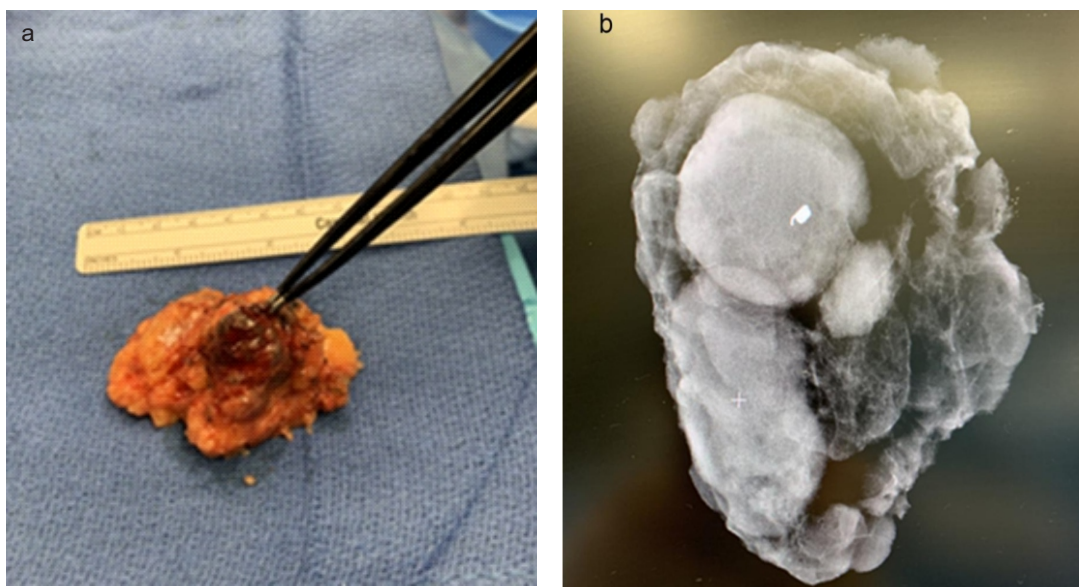


Figure 2. Successful surgical excision of a lymph node localized with tattoo ink: 47-year-old female with invasive lobular carcinoma and biopsy proven metastasis to an axillary lymph node. Following neoadjuvant chemotherapy, ultrasound-guided tattoo ink localization of the previously biopsied lymph node was performed on the day of surgery. Intraoperatively, (A) the lymph node was visually identified as black, with (B) a specimen radiograph confirming the biopsy clip within the node. Sentinel lymph node biopsy (SNLB) was also performed, and the previously biopsied node was also the sentinel node and was malignant at surgical excision.

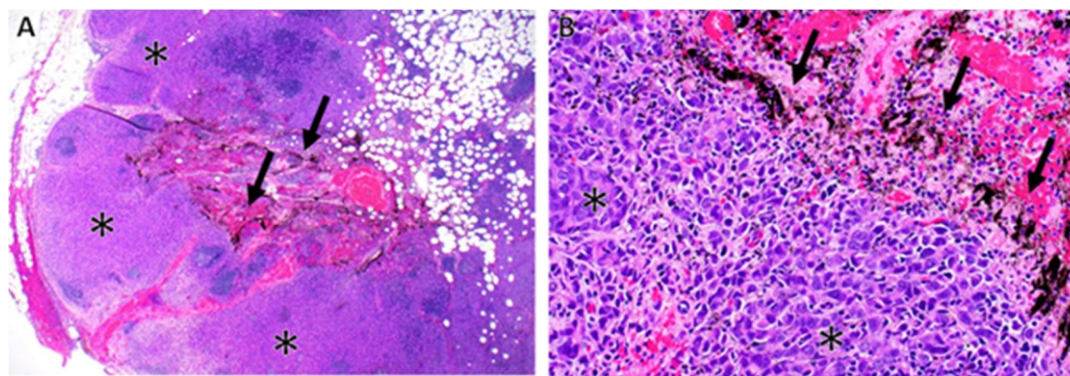


Figure 3. Histologic confirmation of tattoo ink within localized lymph node: A previously biopsied, radiographically abnormal axillary lymph node was spot ink localized on the day of surgery and was identified intraoperatively to be a sentinel lymph node. Upon histologic review, the black tattoo ink (arrows) was identified within the medullary sinuses of the lymph node, which was extensively involved by metastatic lobular carcinoma (asterisks) (A & B, H&E, X20 and X200).

Sentinel Lymph Node Biopsy Outcomes

Sentinel lymph node biopsy (SLNB) was attempted in 14/15 (93.3%) of the breast cancer patients and was successful in 13/14 (92.9%). SLNB was not performed in one breast cancer patient, who was an 81 year-old female with an 11 year history of stage 4 breast cancer. Although there was no progression in distant metastasis, there was increased size of her left breast mass and a single left axillary lymph node, and, therefore, targeted excision was performed without SLNB. Among the 13 successful SLNB, the average number of excised lymph nodes was 2.8 (standard deviation 1.6, median 2.5, range 1-6). In one patient in whom SLNB was unsuccessful, intra-operative identification of the previously biopsied lymph node containing tattoo ink was successful. Among the 13 patients with successful SLNB, there were 14 lymph nodes which underwent pre-operative tattoo ink localization. Nine of the 14 (64.2%) tattooed lymph nodes were also a sentinel node. Of the 5 excised tattooed nodes that were not a sentinel node, all 5 had a previous ultrasound guided biopsy, 3/5 (60%) were in patients who underwent neoadjuvant chemotherapy prior to surgery and 4/5 (80%) contained malignancy at surgical excision. In 1/5 (20%) of these patients, the sentinel node was benign but the localized lymph node was malignant.

Surgical Pathology

The presence of tattoo ink did not interfere with surgical pathology interpretation (Figure 3). Histologically, the tattoo ink was visualized within the cortical or medullary sinuses of the lymph nodes, and occasionally in the adjacent mature adipose tissue.

The patient with melanoma had tattoo ink localization of two borderline-appearing lymph nodes, one of which had undergone core biopsy with findings consistent with benign nevus cells. However, in the setting of a history of axillary melanoma, excision was recommended. Tattoo ink localization of both lymph nodes was successful and

surgical pathology was benign for both lymph nodes at excision.

The second non-breast cancer patient had increased size of axillary lymph node with core biopsy demonstrating atypical lymphoid proliferation concerning for B-cell non-Hodgkin lymphoma on flow cytometry. Tattoo ink localization of the biopsied lymph node was successful, and surgical pathology and flow cytometry at excision were consistent with a reactive lymph node.

Discussion

Pre-operative localization of axillary lymph nodes is often desired, but current options for image-guided localization are limited. Ultrasound-guided tattoo ink has emerged as a potential technique to safely and accurately localize specific axillary lymph nodes. This study aimed to prospectively evaluate the success rate of preoperative localization of axillary lymph nodes using tattoo ink, as well as to assess the frequency with which tattooed nodes corresponded to sentinel lymph nodes.

In this study, 17/19 (89.5%) tattooed lymph nodes were successfully identified intra-operatively, with successful identification occurring in 16/17 (94.1%) of patients. Although this is minimally lower than what was observed in previous studies, which report success rates ranging from 96.4-100%⁸⁻¹⁵, this is likely due to the small sample size in this study, as the procedure was successful in all but one patient. This study provides further evidence that ultrasound-guided injection of tattoo ink is a safe, reliable, and highly successful method for pre-operative localization in the axilla. Furthermore, tattoo ink is widely available, inexpensive and does not require specialized equipment, such that it may be implemented easily on a large-scale in the community, including in areas with limited resources.

Among patients also undergoing SLNB in this study, the tattooed node was also a sentinel node in 9/14 (64.2%) of patients, which is within the range of previous studies.⁸⁻¹⁵ For our study patients, if only the



sentinel lymph nodes had been excised without additional targeted localization and excision of the tattooed node, the localized lymph node would have remained in situ for 5/14 (35.7%) of patients undergoing SNLB. Of the five tattooed nodes that were not sentinel nodes, 4/5 (80%) were malignant. Furthermore, 3/5 (60%) of these lymph nodes had undergone ultrasound guided biopsy with malignant result prior to neoadjuvant chemotherapy, such that the pathologic response to neoadjuvant chemotherapy in these nodes would not have been known if only SLNB was performed without excision of the localized node.

This study has several limitations. The sample size of 17 lymph nodes in 19 patients is relatively small. Additionally, the tattoo injection procedure was performed by one of nine breast radiologists and surgical excision was performed by one of the five surgeons specializing in breast surgery and/or with expertise in surgical management of the axilla, adding potential variability to procedural technique. However, this study provides direct multidisciplinary correlations with the intra-operative and pathologic appearance in addition to supporting the technique as a successful and easily accessible method for localization. Additionally, to our knowledge, all previous studies have included only breast cancer patients, and this study included all patients in whom axillary lymph node localization was desired, including melanoma and possible lymphoma.

Existing methods for pre-operative localization in the axilla such as radioactive ^{125}I seeds, MagSeed and Tag localizations have limitations including high cost and the requirement of specialized equipment.¹⁻⁷ This study supports previous reports that ultrasound guided injection of tattoo ink is emerging as a safe, inexpensive, widely available technique for pre-operative localization in the axilla with a high success rate of intraoperative visualization of tattooed nodes. Future larger studies may further define specific protocols for the successful application of this technique.

Conflicts of Interest

None.

References

1. Plecha D, Bai S, Patterson H, Thompson C, Shenk R. Improving the accuracy of axillary lymph node surgery in breast cancer with ultrasound-guided wire localization of biopsy proven metastatic lymph nodes. *Annals of surgical oncology*. 2015;22(13):4241-6.
2. Wang Y, Dong H, Wu H, Zhang L, Yuan K, Chen H, et al. Improved false negative rate of axillary status using sentinel lymph node biopsy and ultrasound-suspicious lymph node sampling in patients with early breast cancer. *BMC cancer*. 2015;15(1):1-7.
3. Caudle AS, Yang WT, Mittendorf EA, Black DM, Hwang R, Hobbs B, et al. Selective surgical localization of axillary lymph nodes containing metastases in patients with breast cancer: a prospective feasibility trial. *JAMA surgery*. 2015;150(2):137-43.
4. Diego EJ, McAuliffe PF, Soran A, McGuire KP, Johnson RR, Bonaventura M, et al. Axillary staging after neoadjuvant chemotherapy for breast cancer: a pilot study combining sentinel lymph node biopsy with radioactive seed localization of pre-treatment positive axillary lymph nodes. *Annals of surgical oncology*. 2016;23(5):1549-53.
5. Greenwood HI, Wong JM, Mukhtar RA, Alvarado MD, Price ER. Feasibility of magnetic seeds for preoperative localization of axillary lymph nodes in breast cancer treatment. *American Journal of Roentgenology*. 2019;213(4):953-7.
6. Janssen N, Nijkamp J, Alderliesten T, Loo C, Rutgers E, Sonke J, et al. Radioactive seed localization in breast cancer treatment. *Journal of British Surgery*. 2016;103(1):70-80.
7. Lowes S, Bell A, Milligan R, Amonkar S, Leaver A. Use of Hologic LOCALizer radiofrequency identification (RFID) tags to localise impalpable breast lesions and axillary nodes: experience of the first 150 cases in a UK breast unit. *Clinical Radiology*. 2020;75(12):942-9.
8. Allweis TM, Menes T, Rotbart N, Rapson Y, Cernik H, Bokov I, et al. Ultrasound guided tattooing of axillary lymph nodes in breast cancer patients prior to neoadjuvant therapy, and identification of tattooed nodes at the time of surgery. *European Journal of Surgical Oncology*. 2020;46(6):1041-5.
9. Choy N, Lipson J, Porter C, Ozawa M, Kierny A, Pal S, et al. Initial results with preoperative tattooing of biopsied axillary lymph nodes and correlation to sentinel lymph nodes in breast cancer patients. *Annals of surgical oncology*. 2015;22(2):377-82.
10. Natsiopoulos I, Intzes S, Liappis T, Zarampoukas K, Zarampoukas T, Zacharopoulou V, et al. Axillary lymph node tattooing and targeted axillary dissection in breast cancer patients who presented as cN+ before neoadjuvant chemotherapy and became cN0 after treatment. *Clinical breast cancer*. 2019;19(3):208-15.
11. Patel R, MacKerricher W, Tsai J, Choy N, Lipson J, Ikeda D, et al. Pretreatment tattoo marking of suspicious axillary lymph nodes: reliability and correlation with sentinel lymph node. *Annals of surgical oncology*. 2019;26(8):2452-8.
12. Kim WH, Kim HJ, Jung JH, Park HY, Lee J, Kim WW, et al. Ultrasound-guided restaging and localization of axillary lymph nodes after neoadjuvant chemotherapy for guidance of axillary surgery in breast cancer patients:



- experience with activated charcoal. *Annals of surgical oncology*. 2018;25(2):494-500.
13. Kim WH, Kim HJ, Jung JH, Park HY, Lee J, Kim WW, et al. Ultrasound-guided fine-needle aspiration of non-palpable and suspicious axillary lymph nodes with subsequent removal after tattooing: false-negative results and concordance with sentinel lymph nodes. *Ultrasound in medicine & biology*. 2017;43(11):2576-81.
 14. Kim WH, Kim HJ, Kim SH, Jung JH, Park HY, Lee J, et al. Ultrasound-guided dual-localization for axillary nodes before and after neoadjuvant chemotherapy with clip and activated charcoal in breast cancer patients: a feasibility study. *BMC cancer*. 2019;19(1):1-8.
 15. Park S, Koo JS, Kim GM, Sohn J, Kim SI, Cho YU, et al. Feasibility of charcoal tattooing of cytology-proven metastatic axillary lymph node at diagnosis and sentinel lymph node biopsy after neoadjuvant chemotherapy in breast cancer patients. *Cancer research and treatment: official journal of Korean Cancer Association*. 2018;50(3):801.