



DOI: 10.19187/abc.202073202-206

Primary Leiomyosarcoma of the Breast Papilla: A Case Report

Matthäeus Cunha Bürger^{*a}, Edson Marchiori^a, Maria Celia R. Djahjah^a,
Nathalie Cruz da Silva Bürger^a, Ana Helena Correia^b

^a Department of Radiology, Clementino Fraga Filho University Hospital, Federal University of Rio de Janeiro, Rio de Janeiro, RJ, Brazil

^b Department of Pathological Anatomy, Clementino Fraga Filho University Hospital, Federal University of Rio de Janeiro, Rio de Janeiro, RJ, Brazil

ARTICLE INFO

Received:
21 September 2020
Revised:
04 October 2020
Accepted:
14 October 2020

Key words:

Leiomyosarcoma,
breast papilla,
magnetic resonance imaging

ABSTRACT

Background: Breast leiomyosarcoma is a rare subtype of breast sarcoma, constituting 5–10% of the cases. Less than one-third of reported cases are located in the nipple papillary region, making it an extraordinarily rare malignancy, responsible for less than 0.1% of all malignant breast tumors. As no radiological criteria allow definitive diagnosis of papillary leiomyosarcoma, histopathological and immunohistochemical examination of suspicious lesions is required. The prognosis is generally optimistic compared with those for other breast sarcomas.

Case presentation: A 54-year-old previously healthy woman reported the appearance of a nodule in her right nipple in the preceding 9 months, associated with pruritus. Physical examination revealed that the lesion had a cystic consistency and measured approximately 3.0 cm. Imaging examinations showed no involvement of the adjacent breast parenchyma or axillary region and the lesion was classified as Breast Imaging-Reporting and Data System (BI-RADS) category IV. The lesion was excised, and the histopathological diagnosis was well-differentiated leiomyosarcoma of the mammary papilla, with immunohistochemical examination showing positivity for smooth-muscle tissue antigens. A staging CT examination was performed, showing no evidence of distant metastasis. After 2 years of follow-up, the patient shows no sign of tumor recurrence.

Conclusion: Although rare, leiomyosarcoma must be included in differential diagnosis of breast masses, especially those involving the periareolar region. Due to its good prognosis, reporting on this type of tumor is important to guide therapeutic planning, and to identify and track possible complications of its underdiagnosis.

Introduction

Breast sarcoma is an uncommon neoplasm, with an incidence rate of 0.5–1%. Breast leiomyosarcoma is a rare subtype of breast sarcoma, constituting 5–10% of breast sarcoma cases. Fewer than 70 cases of this extraordinarily rare malignancy are

documented in the literature,¹⁻³ and less than one-third of these cases are located in the nipple papillary region. Most patients with primary leiomyosarcoma of the breast are female, although at least four cases in males have been reported.⁴ The disease usually appears in postmenopausal women aged 50–80 years; in rare cases, it appears in young girls.⁵ Most primary breast sarcomas expand rapidly, with advancing borders that confer a well-circumscribed gross appearance, with or without histological invasion. This appearance differs from that of most invasive breast carcinomas, which typically exhibit stellate or ill-defined borders macroscopically and widely infiltrative borders at the microscopic level.⁶

Address for correspondence:

Matthäeus Cunha Bürger, MD
Address: Rua Firmino Gameleira, 360, Apto 301. Olaria. CEP
21021.450. Rio de Janeiro, Brazil
Tel: +55 22 981465921.
Email: matthaeus3@gmail.com



Morphologically, the typical histological features of circumscription, pronounced cellularity, and a composition of fusiform spindle cells with blunt-end nuclei lead to the suspicion of primary breast sarcoma. Confirmation by an immunohistochemical profile of smooth-muscle actin, vimentin, and desmin positivity is helpful. We report a case of primary leiomyosarcoma of the mammary papilla in a 54-year-old woman. After excision and central resection of the breast, the patient is well, with no sign of tumor recurrence.

Case presentation

A 54-year-old woman presented at the mastology ambulatory service due to the emergence of a nodule in her right nipple in the preceding 9 months, associated with pruritus. No bleeding, papillary discharge or family history of breast cancer was noted. Physical examination revealed that the right

nipple was enlarged and piriform, and had a cystic consistency and a diameter of about 3 cm. The axilla was free on palpation. Mammography showed a single high-density oval mass with well-defined margins, a diameter of 3.4 cm, and no associated calcification in the papillary region of the right breast. Magnetic resonance imaging showed an oval mass in the right nipple with a circumscribed margin, heterogeneous signal intensity (predominantly high on T2 and short tau inversion recovery sequences, intermediate on T1 sequences), and intense heterogeneous contrast enhancement (Figure 1). No involvement of the adjacent breast parenchyma or axillary region was observed. The lesion was classified as BI-RADS category IV. Its clinical and radiological characteristics, in particular its superficial and non-infiltrative nature, associated with the absence of lymph node dissemination, favored surgical excision.

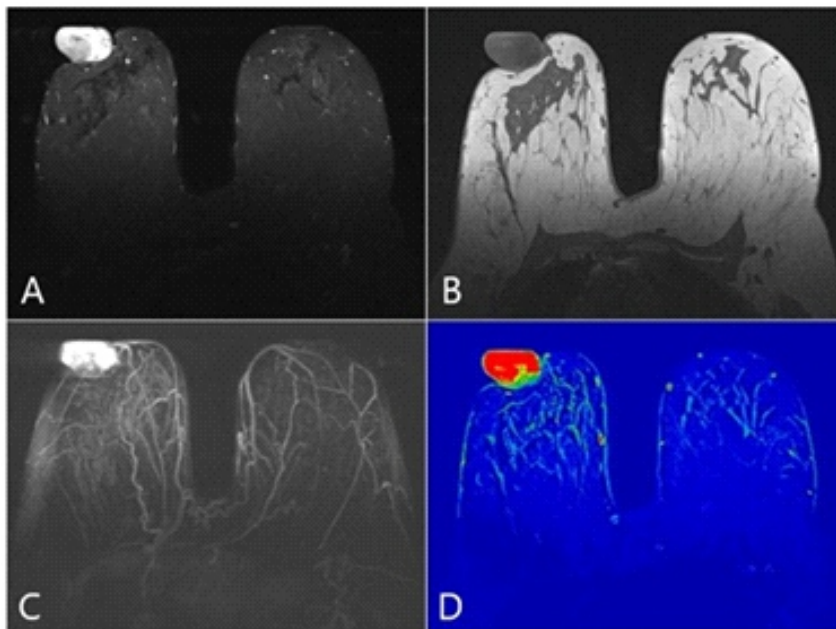


Figure 1. Magnetic resonance imaging of the breast demonstrated an oval mass in the right nipple with a circumscribed margin, with (A) high signal intensity on a STIR sequence; (B) intermediate intensity on a T1 sequence; and (C) intense and heterogeneous enhancement by contrast with no effect on the adjacent breast parenchyma, as demonstrated by maximum intensity projection reconstruction. (D) Colored parametric map showing the increased permeability of the lesion.

The mammary papilla was excised, and macroscopic examination revealed a whitish, firm-elastic, lobulated, well-defined tumor measuring $4.0 \times 3.0 \times 3.0$ cm, juxtaposed to the overlying skin. Histopathological analysis revealed a well-differentiated leiomyosarcoma of the papilla, with spindle cells containing possible atypical nuclei and up to three mitotic figures/10 high-magnification fields, without tumor necrosis (Figure 2 and 3). Immunohistochemical examination showed positivity for smooth-muscle tissue antigens (e.g., actin and desmin) and negativity for carcinoma markers (p63 and cytokeratin pool), melanoma markers (S-100 and Melan A), and the vascular/myofibroblastic marker CD34, confirming the diagnosis (Figure 3).

A metastatic work-up, which included computed tomographic (CT) examination of the chest and abdomen, revealed no metastatic disease. A periareolar incision was made to expand the resection margins in the right breast, and the anterior scar and papillary region of the nipple were removed, with the creation of a 5-cm margin associated with central breast resection. Left breast reduction surgery was performed for aesthetic purposes (Figure 4). As lymphatic spread and nodal metastasis are not typical features of leiomyosarcomas, no sentinel lymph-node biopsy or axillary lymph-node dissection was performed. After 2 years of follow-up with annual mammography, the patient shows no sign or symptom of tumor recurrence.

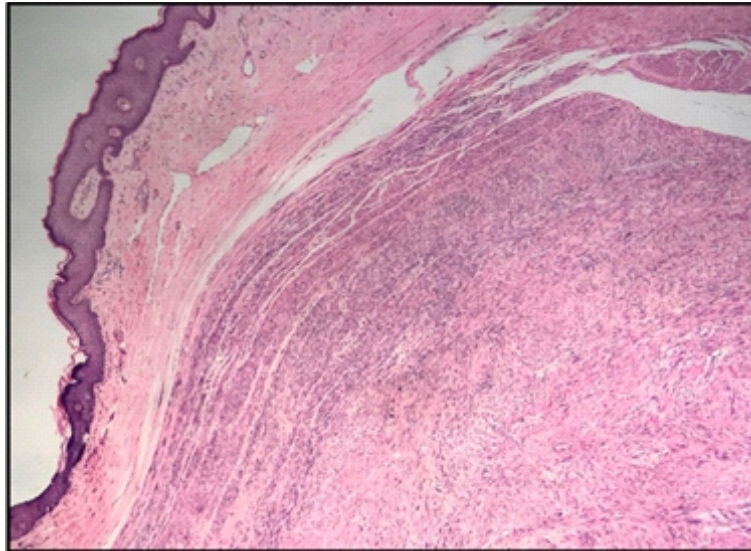


Figure 2. Section showing a well-defined fusocellular neoplasia in the nipple region (hematoxylin and eosin stain, $\times 40$).

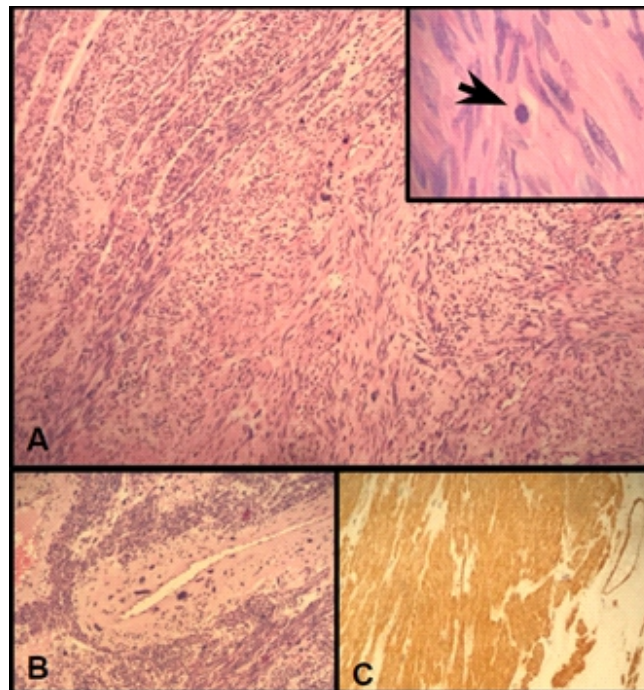


Figure 3. (A) Section showing that the neoplasia is composed of fusocellular bundles, and detailed view showing a mitotic figure (arrow). Marked cytological atypia (B) and immunohistochemical positivity for actin (A and B) are evident (hematoxylin and eosin stain, $\times 100$). (C) Section showing immunohistochemical positivity for smooth muscle markers, including anti-smooth muscle anti-actin ($\times 400$).

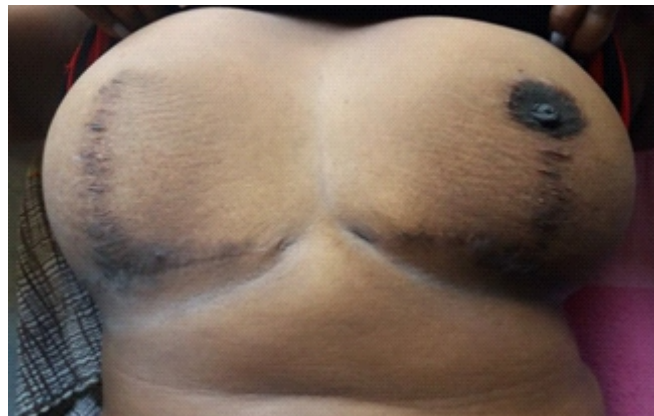


Figure 4. Photograph of the postoperative result, following removal of the right periareolar region . Left breast reduction surgery was performed for aesthetic purposes.



Discussion

The exact origin of breast leiomyosarcomas is debated. These entities belong to the subgroup of spindle-cell breast tumors, which generally arise from the smooth-muscle cells lining blood vessels or from stromal mesenchymal cells, reflecting the controversy surrounding their etiology. Most cases, including ours, are located near the areola and likely originate from the blood vessels and musculature in this anatomical region.⁶

Differentiation between breast sarcoma and breast carcinoma is important, especially when the lesion presents as a mass. Breast sarcomas are unilateral (rarely bilateral), well-defined, large (5–6 cm) painless firm masses, typically diagnosed in patients aged about 50 years.⁷ They grow rapidly, with preferential hematogenous dissemination. Chest CT examination should be performed for all newly diagnosed patients, as the lungs are the predominant metastatic sites. Like sarcomas that appear elsewhere, breast sarcomas are usually treated with surgery and sometimes chemotherapy. With proper treatment, the prognosis is usually good.⁷ Breast carcinomas are diagnosed in patients aged about 60 years⁸; most of these lesions are minor and show preferential dissemination through the lymphatic and hematogenous pathways. Thus, the presence of lymphadenopathy in association with a mass in the breast should increase the likelihood of carcinoma over sarcoma. A wide range of treatments, including surgery, radiation therapy, chemotherapy and hormone therapy, are available for breast carcinoma. The prognosis is variable according to the staging and is good for lesions that are detected early.⁸

As no radiological criteria allow the definitive diagnosis of papillary leiomyosarcoma, histopathological and immunohistochemical examination of lesions in suspected cases is required.⁴ The presence of a rapidly growing mass with indistinct or circumscribed margins and a heterogeneous or complex echotexture, and the absence of axillary lymphadenopathy, favor the diagnosis of sarcoma.⁹ The histopathological differential diagnosis is made with fusocellular metaplastic carcinoma, phyllodes tumor, myofibroblastoma and leiomyoma of the breast.

Leiomyosarcoma presents prominent cell atypia, atypical mitosis, vascular invasion, and necrosis.¹⁰ Patients are usually asymptomatic, but they may experience itching, increased breast volume, pain, and hardening of the nipple or nodule.¹¹

Tumor size is an important prognostic factor, given that the overall survival rate is better for patients with tumors less than 5 cm in diameter. Dissemination is mainly hematogenous: cells spread to the lungs, bones, liver and central nervous system, with only discreet lymphatic spread.¹² Albeit rare, the association of metastasis with a large, rapidly growing breast leiomyosarcoma signifies aggressive

behavior.¹³

The initial treatment in the early stage of this disease is operative, consisting of local resection or mastectomy. As leiomyosarcoma tends to recur locally, local resection is inadequate unless wide negative margins are achieved. For maximum effectiveness, a negative margin of at least 3 cm is recommended; however, a 2-cm margin can be utilized for breast conservation therapy.¹ In our case, we achieved a 5-cm resection margin. Furthermore, given the mainly hematogenous dissemination route of metastasis, no case of axillary lymph-node invasion has been documented; thus, lymph node dissection may be unnecessary.¹ We performed conservative breast surgery, as supported by reports on a few cases showing no difference in outcome between patients who underwent such surgery with the achievement of microscopically negative margins and those who underwent mastectomy.¹⁴ Chemotherapy does not effectively treat breast sarcomas, although combined regimens may result in some improvement.¹⁵ The use of adjuvant radiotherapy for leiomyosarcoma is based on the therapeutic principles established for soft-tissue sarcomas of the extremities. Several authors have suggested the use of radiotherapy for patients with positive surgical margins.¹⁴ Other prognostic factors that should be evaluated for radiotherapy are tumor size, infiltrative features, and histopathological grading. Given the rarity of leiomyosarcoma, available data are too limited to guide the use of radiotherapy and chemotherapy.^{15, 16} In our case, considering the limited extent of the disease, no radiotherapy or chemotherapy was administered.

The prognosis of breast leiomyosarcoma is generally optimistic relative to that of other breast sarcomas. However, because of the prolonged risk of recurrence, long-term follow-up may be indicated.¹ Most available data on breast leiomyosarcoma derive from case reports and small case series, and the natural history of this disease and its response to different therapeutic modalities have not been well established.

Reporting on this type of tumor is important to determine the most appropriate management plan for the patient, to identify and track possible complications of its underdiagnosis and avoid overtreatment, aiming for the best disease-free result.

Ethical considerations

The patient has provided written informed consent to the publication of this case (including the publication of images).

Conflict of interest

The authors declare that they have no conflict of interest.



References

1. Amberger M, Park T, Petersen B, Baltazar GA. Primary breast leiomyosarcoma with metastases to the lung in a young adult: Case report and literature review. *Int J Surg Case Rep.* 2018;47:34-7.
2. Felix C, Bispo M, Chagas C. Pancreatic Metastasis from Primary Leiomyosarcoma of the Breast. *GE Port J Gastroenterol.* 2019;26(3):223-5.
3. Wong LC, Huang PC, Luh SP, Huang CS. Primary leiomyosarcoma of the nipple-areola complex: report of a case and review of literature. *J Zhejiang Univ Sci B.* 2008;9(2):109-13.
4. Assis JOD, Pimentel ACdA, Chambo Filho A, Cintra LC, Scardini R. Leiomiiossarcoma de mama: relato de caso. *Revista Brasileira de Ginecologia e Obstetrícia.* 2001;23(4):255-8.
5. Rane SU, Batra C, Saikia UN. Primary leiomyosarcoma of breast in an adolescent girl: a case report and review of the literature. *Case Rep Pathol.* 2012;2012:491984.
6. Testori A, Meroni S, Voulaz E, Alloisio M, De Sanctis R, et al. Primary breast leiomyosarcoma and synchronous homolateral lung cancer: a case report. *J Thorac Dis.* 2017;9(12):E1054-E9.
7. Oktay Y, Fikret A. Leiomyosarcoma of the breast. *J Surg Case Rep.* 2011;2011(7):1.
8. Alkabban FM, Ferguson T. Cancer, breast. *StatPearls [Internet]: StatPearls Publishing;* 2019.
9. Smith TB, Gilcrease MZ, Santiago L, Hunt KK, Yang WT. Imaging features of primary breast sarcoma. *AJR Am J Roentgenol.* 2012;198(4):W386-93.
10. Munitiz V, Rios A, Canovas J, Ferri B, Sola J, et al. Primitive leiomyosarcoma of the breast: case report and review of the literature. *Breast.* 2004;13(1):72-6.
11. Minami S, Matsuo S, Azuma T, Uga T, Hayashi T, et al. Parenchymal leiomyoma of the breast: a case report with special reference to magnetic resonance imaging findings and an update review of literature. *Breast Cancer.* 2011;18(3):231-6.
12. Al-Benna S, Poggemann K, Steinau HU, Steinstraesser L. Diagnosis and management of primary breast sarcoma. *Breast Cancer Res Treat.* 2010;122(3):619-26.
13. Singh G, Sharma D, Goyal S. Primary Leiomyosarcoma of Breast Presenting with Metastasis: An Atypical Presentation with Dismal Prognosis. *Indian J Med Paediatr Oncol.* 2017;38(4):535-7.
14. Lim SZ, Ong KW, Tan BK, Selvarajan S, Tan PH. Sarcoma of the breast: an update on a rare entity. *J Clin Pathol.* 2016;69(5):373-81.
15. Pollard SG, Marks PV, Temple LN, Thompson HH. Breast sarcoma. A clinicopathologic review of 25 cases. *Cancer.* 1990;66(5):941-4.
16. Parisi G, Signor MA, Finato N, Ceschia T, Magli A. Breast leiomyosarcoma with myxoid aspects. *Breast J.* 2018;24(6):1086-7.