



DOI: 10.19187/abc.20207293-96

Malignant phyllodes Tumor of the Breast; Presentation of an Uncommon Case and Review of the Literature

Sumaiya Iqbal^{*a}, Juwairiya Iqbal^b, Nowfala Nowshad^a, Khadeeja Mohammad^a^a Department of Obstetrics and Gynecology, Latifa Women and Children's Hospital, Dubai, UAE^b Medical Education, Dubai Medical University, Dubai, UAE

ARTICLE INFO

Received:
02 April 2020
Revised:
21 April 2020
Accepted:
27 April 2020

Key words:
Breast cancer,
phyllodes tumor,
malignancies

ABSTRACT

Background: Phyllodes tumours are rare fibroepithelial neoplasm of connective tissue of the breast accounting for 0.3-1% of all breast tumours with 10% of them being malignant. They resemble fibroadenomas clinically and can be mistakenly ignored.

Case presentation: A 38-year-old unmarried Philipino lady presented to the primary health center with a mass in the right breast for the past year. Over the preceding 6 months, it had progressively increased in size and pain. On examination, a 5 x 3 cm firm and lobulated mass was palpated in the right upper outer quadrant. Ultrasound scan showed a solid 4.25 x 3.3 x 2.4 cm mass with heterogeneous mixed echopattern. She was referred to Surgery department where an ultrasound-guided core biopsy showed a lesion suspicious for benign phyllodes tumor. An excision biopsy revealed three foci of malignant Phyllodes on the background of fibroadenoma. A staging CT was performed which showed no evidence of lymph node involvement or distant metastasis. A simple mastectomy was performed and histopathology confirmed the diagnosis of malignant phyllodes tumor. Postoperatively, the patient is on regular follow up in the breast clinic and physiotherapy department.

Conclusion: Phyllodes tumor bears specific clinical characteristics and should be considered as a differential diagnosis in any mass lesion of the breast.. Diagnosis and management are crucial in phyllodes tumor because of their malignant potential recurrence. Clinicians should be competent in distinguishing between fibroadenoma and a phyllodes tumor. Lastly, given the rarity of phyllodes tumors, there is a need to establish guidelines to incorporate regular follow up for early detection of distant metastasis.

Introduction

Phyllodes tumors are very rare and closely resemble fibroadenomas, making their detection even more difficult. Diagnosis and proper management are crucial because of the malignant potential and tendency to recur. Phyllodes tumor bears specific clinical characteristics and should be considered by the clinician as a differential diagnosis for the breast lumps if clinical suspicion arises by the

rapid increase in the size of the tumor or if the radiographic finding shows heterogeneous hypoechoic internal echoes without calcification. Moreover, once a phyllodes has been diagnosed, it is recommended to have a high degree of suspicion for malignancy despite a benign core biopsy.

Case Presentation

A previously healthy 38-year-old Philipino lady, unmarried and nulliparous with a family history of fibroadenoma, presented with a mass in the right breast for the last year. Over the preceding 6 months, the mass had been progressively increasing in size and was painful. The pain markedly increased during menstruation. There was no nipple discharge, bone

Address for correspondence:

Sumaiya Iqbal, Internship
Address: Latifa Women and Children's Hospital, Dubai Health Authority Jaddaf Dubai, United Arab Emirates.
Tel: +971569400124
E-mail: sumaiyaiqbal96@gmail.com



pain, weight loss or night sweats. The medical, surgical and social history was insignificant. Her quality of life and occupation as a nurse was severely affected as she was unable to lift her right hand due to pain.

On physical examination, the right breast had a mass of dimensions 5x3 cm at 10 o'clock position. It was firm, lobulated, fixed to the underlying tissue and tender to touch. The overlying skin was erythematous. There was no peau'd orange, nipple discharge or nipple retraction in either breast. No lymph nodes were palpable. The left breast was unremarkable. Liver and spleen were not palpable. General examination was unremarkable.

Ultrasound of the right breast is shown in Figure 1 revealed a solid, well circumscribed, lobulated mass with mixed echo pattern suggestive of fibroadenoma with atypical radiologic features. Bilateral axillary lymph nodes were nonspecific. Therefore, the patient was classified as BIRADS Iva.

Core biopsy in Figure 2 demonstrates the cores of the breast tissue with papillary protrusions of stromal connective tissue with a leaf-like appearance. There was no evidence of mitosis or cytological atypia.

Due to rapid progression of clinical symptoms

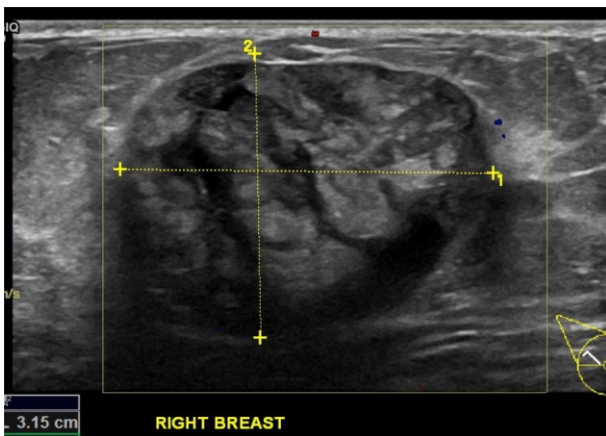


Figure 1. Ultrasound demonstrates a solid 4.25 x 3.3 x 2.4 cm well-circumscribed lobulated mass with a heterogeneous mixed echopattern and, casting a posterior shadow.

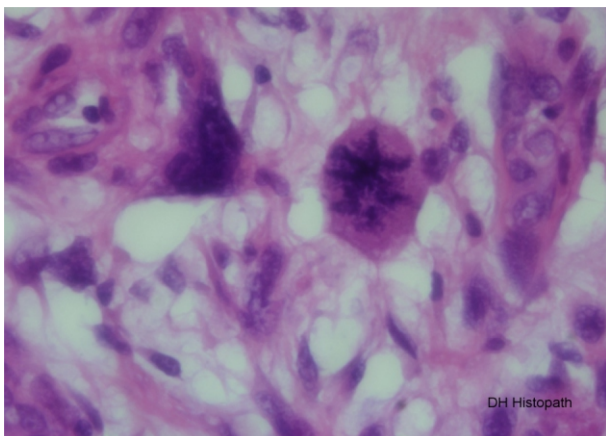


Figure 2. Core biopsy showing the cores of the breast tissue with papillary protrusions of stromal connective tissue producing a leaf-like appearance.

and atypical findings obtained from Ultrasound, there was a high suspicion for malignancy. Therefore, excision biopsy was recommended by the Multidisciplinary team (MDT). Excision biopsy showed a foci of malignant phyllodes tumor accounting for 15-17% of the neoplasm. The epithelium, as seen in Figure 3, was arranged in broad leaf like clefts with scattered multinucleated bizarre stromal cells showing moderate pleomorphism and hyperchromasia.

Increased mitotic activity with mitoses up to 14-16 per 10 HPF were identified with some abnormal mitosis as seen in Figure 4.

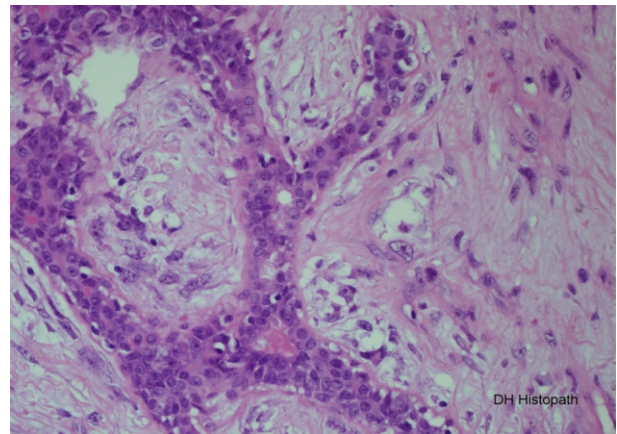


Figure 3. Excision biopsy revealing scattered multinucleated bizarre stromal cells that show moderate pleomorphism and hyperchromasia.

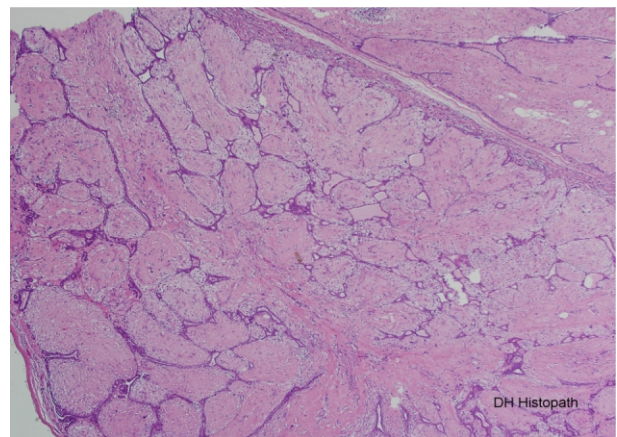


Figure 4. Excision biopsy showing increased mitotic activity with some abnormal mitosis.

Immunohistochemical analysis done by a panel of cytokeratins (CKs) showed that CKAE1/AE3 was negative in stroma and CD34 was positive in stromal cells.

A staging CT scan of chest, abdomen and pelvis was performed which showed no evidence of lymph node involvement and no distant metastasis.

Following some discussion with Multidisciplinary team including a breast surgeon, an oncologist and a pathologist regarding the small size of the patient's breast, a total mastectomy of right breast was performed and the specimen weighing 19.7gm and measuring 4.5x3.5x3cm was sent to histopathology.



No evidence of residual malignant phyllodes tumor was found. There was benign fibroepithelial changes with stromal fibrosis, with few ectatic ducts and microcalcification seen.

The patient had a good postoperative recovery and was able to return to work as a nurse. Two weeks post discharge, she was followed up in breast clinic where she complained of pain and hypersensitivity of the right chest wall. Clinically, the scar had healed with no signs of infection. The patient was reassured and scheduled for an appointment with physiotherapy department. She was put on a follow up plan with breast surgery clinic after 3 months.

Discussion

Phyllodes tumours are rare fibroepithelial neoplasm of the connective tissue of breast accounting for <1% of all breast malignancies and has an incidence of about 2.1 per million.¹ In 1838, Johannes Muller coined the term cystosarcoma-phyllodes based on leaf-like projections extending into cystic spaces and sarcoma-like stroma of the tumor. However, since up to 70% of phyllodes tumor are benign, the term “cystosarcoma” was removed and the tumor is now referred to simply as phyllodes tumors.²

Phyllodes tumors are benign breast tumors found predominantly in females aged between 35 and 55 (median 45).³ The size of the tumor is variable, from 1 cm to 41 cm (on average from 4 cm to 7 cm) and the skin is bright, stretched, and diminished.⁴ It has an initial phase of slow growth followed by the second phase of rapidly accelerating growth over a period of weeks to months.² It may be associated with changes of overlying skin including atrophy, skin thinning, bloody nipple discharge, or nipple retraction, if the areolar region is involved.

On mammography and ultrasound, phyllodes tumors lack distinguishing characteristics and, thus, findings are not specific. Breast ultrasound usually shows a mass with size ≥ 3 , irregular shape, microlobulated borders, complex internal echo pattern, and hypervascularity, while internal cystic areas on MRI are suggestive of phyllodes tumor.⁵ Mammography demonstrates a very dense mass compared to the surrounding parenchyma.

According to the World Health Organization (WHO) classification of 2012, phyllodes tumor is classified as benign, borderline, or malignant as shown in Table 1.⁶

Malignant phyllodes tumor (PT) is characterized

Table 1. Three-Tiered Grading System for Phyllodes Tumors Based On 2012 World Health Organization Classification.

Histologic features	Benign	Borderline	Malignant
Stromal cellularity	Mild	Moderate	Marked
Stromal atypia	Mild	Moderate	Marked
Mitosis (per 10 HPF)	<5	5-9	>10
Stromal overgrowth	Absent	Absent or focal	Present
Tumor margin	Well-defined	Well-defined or focal infiltrative	Infiltrative

by marked stromal cellularity and nuclear pleomorphism, stromal overgrowth, and more than 10 mitoses per 10 HPF. The presence of heterologous sarcomatous elements (liposarcoma, chondrosarcoma, and osteosarcoma) alone qualifies a PT as malignant.⁷

In our case, the histopathologic features of the tumor include the arrangement of epithelium in broad leaf like clefts with scattered multinucleated bizarre stromal cells showing moderate pleomorphism. Increased mitotic activity with mitoses up to 14-16 per 10 HPF are identified with some abnormal mitoses. These findings are compatible with those from malignant phyllodes tumors.

The mainstay of phyllodes tumour management has traditionally consisted of surgical excision with wide tumour-free margins, generally defined by some authors as at least 10 mm.⁸ Axillary lymph node dissection is not necessary. Adjuvant radiation therapy may benefit borderline or malignant tumors, but not benign ones. Belkacemi et al. in an analysis of the cases collected from the Rare Cancer Network

found that adjuvant radiotherapy for borderline and malignant tumors yielded superior 10-year local control rates; but no survival benefits.⁹ Chemotherapy is reserved for highly selected patients with large, high-risk, or recurrent malignant phyllodes tumors. However, hormonal therapy is not used to treat phyllodes tumors.

The survival rate for malignant phyllodes tumors is reported as approximately 60–80% at 5 years.¹⁰ After the tumor has metastasized, the average net survival is 30 months.¹¹

In conclusion, PTs are a rare cause of rapidly enlarging painless breast masses in middle age women. Further workup should be considered when a patient suspects that the lesion is growing in size within 6 months to a year. Ultrasound usually shows heterogeneous hypoechoic internal echoes without calcifications. Our case highlighted the fact that it is difficult to diagnose phyllodes based on a core biopsy due to the subjective nature of interpretation of the degree of stromal cellularity as well as the degree of atypia. Even if a phyllodes is diagnosed on



core biopsy, an excision biopsy is always required to determine if it is a benign or malignant phyllodes tumour.¹² Surgical management is the mainstay of treatment¹³ while adjuvant treatment with chemotherapy; radiotherapy or hormonal therapy currently have no clear evidence of benefit and remain controversial.¹⁴ Therefore, we recommend physicians to be vigilant of phyllodes tumors and consider them in the differential diagnosis should the clinical suspicion be raised.

Acknowledgements

We acknowledge Dr. Hajer for proofreading the manuscript.

Ethical Consideration

The patient has given written informed consent to publish this case (including publication of images).

Conflict of Interest

The authors have no conflicts of interest to declare.

References

1. Altedlawi Albalawi I. A huge phyllodes tumor in the breast: a case report. *Electronic Physician*. 2018;10(6):6951-6955
2. Amir RA, Rabah RS, Sheikh SS. Malignant Phyllodes Tumor of the Breast with Metastasis to the Pancreas: A Case Report and Review of Literature. *Case Rep Oncol Med*. 2018: 6491675.
3. Barrio AV, Clark BD, Goldberg JI, Hoque LW, Bernik SF, *et al*. Clinicopathologic features and long-term outcomes of 293 phyllodes tumors of the breast. *Ann Surg Oncol*. 2007;14(10):2961-70
4. Vargas-Hernandez VM, Aguilar VMV. Phyllodes Tumors (Cystosarcoma Phyllodes): A Diagnostic and Therapeutic Challenge. *World J Breast Cancer Res*. 2019; 2(2): 1016
5. Duman L, Gezer N, Balci P, Altay C, Başara I, Durak M *et al*. Differentiation between Phyllodes Tumors and Fibroadenomas Based on Mammographic Sonographic and MRI Features. *Breast Care*. 2016;11(2):123-127
6. Lakhani SR. WHO Classification of Tumours of the Breast: International Agency for Research on Cancer; 2012.
7. Zhang Y, Klier C. Phyllodes Tumor of the Breast: Histopathologic Features, Differential Diagnosis, and Molecular/Genetic Updates. *Archives of Pathology & Laboratory Medicine*. 2016;140(7):665-671.
8. Tan BY, Acs G, Apple SK, Badve S, Bleiweiss IJ, *et al*. Phyllodes tumours of the breast: a consensus review. *Histopathology*. 2016;68(1):5-21.
9. Belkacemi Y, Bousquet G, Marsiglia H, Ray-Coquard I, Magne N, *et al*. Phyllodes tumor of the breast. *Int J Radiat Oncol Biol Phys*. 2008;70(2):492-500.
10. Demian G, Fayaz S, El-Sayed Eissa H, Nazmy N, Samir S, George T *et al*. Phyllodes tumors of the breast: Analysis of 35 cases from a single institution. *Journal of the Egyptian National Cancer Institute*. 2016;28(4):243-248
11. Yoshidaya F, Hayashi N, Takahashi K, Suzuki K, Akiyama F, *et al*. Malignant phyllodes tumor metastasized to the right ventricle: a case report. *Surg Case Rep*. 2015;1(1):121.
12. Yan Z, Gudi M, Lim S. A large benign phyllodes tumour of the breast: A case report and literature review. *International Journal of Surgery Case Reports*. 2017;39:192-19
13. Altedlawi Albalawi I. A huge phyllodes tumor in the breast: a case report. *Electronic Physician*. 2018;10(6):6951-6955
14. Câmara S, González-Farré X, Vargas-Moniz J. Giant phyllodes tumour – Case report, oncologic treatment and literature controversies. *Revista de Senología y Patología Mamaria*. 2017;30(2):79-84