



DOI: 10.19187/abc.20185258-62

Ductal Carcinoma *In Situ* Close to the Inked Margin: A Case Presented in Multidisciplinary Session With Clinical Discussion and Decision Making

Ahmad Elahi^{a*}, Gholamreza Toogeh^b, Habibollah Mahmoodzadeh^c, Behnaz Jahanbin^d, Farhad Shahi^e, Bita Kalaghchi^f, Nahid Sadighi^g

^a Division of Breast Surgical Oncology, Department of Surgery, Alborz University of Medical Sciences, Karaj, Iran

^b Hematology and Medical Oncology Department, Thrombosis Hemostasis Research Center, Tehran University of Medical Sciences, Tehran, Iran

^c Division of Surgical Oncology, Department of Surgery, Cancer Institute, Tehran University of Medical Sciences, Tehran, Iran

^d Cancer Research Center, Department of Pathology, Tehran University of Medical Sciences, Tehran, Iran

^e Hematology and Medical Oncology Department, Cancer Institute, Tehran University of Medical Sciences, Tehran, Iran

^f Radiation Oncology Research center, Department of Radiation Oncology, Tehran University of Medical Sciences, Tehran, Iran

^g Medical Imaging Center, ADIR, Cancer Institute, Department of Radiology, Tehran University of Medical Sciences, Tehran, Iran

ARTICLE INFO

Received:

25 March 2018

Revised:

05 April 2018

Accepted:

15 April 2018

Key words:

Breast cancer,
 ductal carcinoma *In situ*
 (DCIS),
 inked margin,
 multidisciplinary team
 decision

ABSTRACT

Background: For many years, the acceptable margins of the resections for ductal carcinoma *in situ* (DCIS) has been 2 mm, although, in some reports and the recent updates of some guidelines, the closer margins are also declared as acceptable in some circumstances. Despite these new recommendations, the safe margin in DCIS remains a matter of controversy in many institutional and national guidelines.

Case Presentation: A woman with invasive breast cancer with associated DCIS presented to our clinic. She underwent breast-conserving surgery, and pathology report showed one focus of DCIS at a distance of < 1 mm from inked margin. This case was presented in the weekly breast multidisciplinary team session of the Department of Breast Surgery, Tehran University of Medical Sciences.

Question: The question was whether the patient should be operated again to obtain more extensive margins for DCIS or the radiation therapy would be enough as the next step in her treatment.

Conclusion: According to the latest published guidelines, the members of panel decided to accept the margin and informed the patient about the risk of recurrence and the need for adjuvant radiotherapy and follow-up modalities.

Introduction

Ductal carcinoma *in situ* (DCIS) is the growth of noninvasive malignant cells in the lumen of the mammary ducts. Screening mammography helps to detect breast lesions in an early stage. Therefore, the diagnosis rate of DCIS has increased in the past two decades because of early detection.¹

Breast-conserving surgery (BCS) with adequate margins and radiotherapy reduces the risk of invasive recurrence in low-risk DCIS group, although radiotherapy is more likely to be planned for patients with DCIS who have large (> 15 mm), intermediate- or high-grade tumors, or present with comedo-type central necrosis.²

The adequate margin in BCS for DCIS is a challenging subject. In one study, the recommended minimum adequate clear margins in low- or intermediate-grade DCIS, measuring less than 2.5 cm, was ≥ 3 mm.³ A consensus statement by the Society of Surgical Oncology (SSO) and the American Society for Radiation Oncology

Address for correspondence:

Ahmad Elahi, MD
 Address: Imam Ali Hospital Complex, Chamran Blvd,
 Azimieh, Karaj, Iran
 Tel: +98 26 32527575
 Fax: +98 26 32547128
 Email: elahi84@gmail.com



(ASTRO) considered 2 mm as standard margin that should be complemented by whole-breast irradiation. These therapeutic options are associated with lower rates of ipsilateral breast tumor recurrence (IBTR) and reexcision.^{4,5} Moreover, the consensus marked “no ink on tumor” as the adequate margin for invasive tumors.⁵ The acceptable free margin is 1 mm for both *in situ* and invasive cancers according to the Association of Breast Surgery (ABS).⁶ However, a new meta-analysis found no significant difference between 2-mm and more than 2-mm surgical margins in resection of DCIS. The study recommended 2 mm as the minimum acceptable safe margin in patients undergoing BCS and radiotherapy.⁷

The present article aims to explore this challenge and make the best decision for a patient whose DCIS was removed with the resection margins of <1 mm.

Case Presentation

A 60-year-old woman with no family history of breast cancer referred to our breast clinic with the chief complaint of the right breast mass. The mass (30 × 20 mm) was palpated in the upper outer quadrant of her right breast (near zone) without palpable axillary lymph node.

In mammography, there was an ill-defined mass containing suspicious microcalcifications in the upper outer quadrant of the right breast with a BI-RADS score of 5 (Figure 1). Ultrasonography reported a 16 × 14 mm irregular, hypoechoic mass in upper outer part of the right breast, and the axillary lymph nodes were reported as reactive. The results of core needle biopsy of the breast mass was indicative of invasive ductal carcinoma with concomitant *in situ* component with comedo necrosis.

After preparation of patient for surgery, she underwent breast conserving surgery along with oncoplastic repair (Round Block technique). Specimen mammography during surgery was performed to be certain of complete excision of the microcalcifications. Frozen study for sentinel lymph node was performed reported negative for malignancy and was confirmed in permanent evaluation. Lumpectomy specimen revealed a 35 mm firm ill-defined mass with histologic diagnosis of invasive and *in situ* ductal carcinoma. Ductal carcinoma *in situ* constituted about 20% of the tumor and lymph vascular invasion was also noted. All surgical margins were defined free except for the inferior margin which involved by DCIS with distance of 2mm. Immunohistochemistry assessment was positive for estrogen receptor, but negative for progesterone receptor and HER2neu with proliferative activity (KI67) of about 20%.

The patient was scheduled for further imaging studies to assess systemic distribution of the tumor as well as reoperation to excise the involved margin (figure 2, 3, 4). In the second operation, the inferior margin re-excision was performed with acceptable distance from the tumor grossly. Complete excision of residual microcalcifications (two groups that were localized with wires before second surgery) was confirmed by specimen mammography (figure 5).

In pathologic assessment of re-excised inferior margin, multiple foci of low grade DCIS with minimum distance of 1mm to inked surgical margin was reported. The cosmetic outcome after the second operation was good again, and there were no complications associated with either surgery. All the systemic radiologic assessments were negative for metastasis.

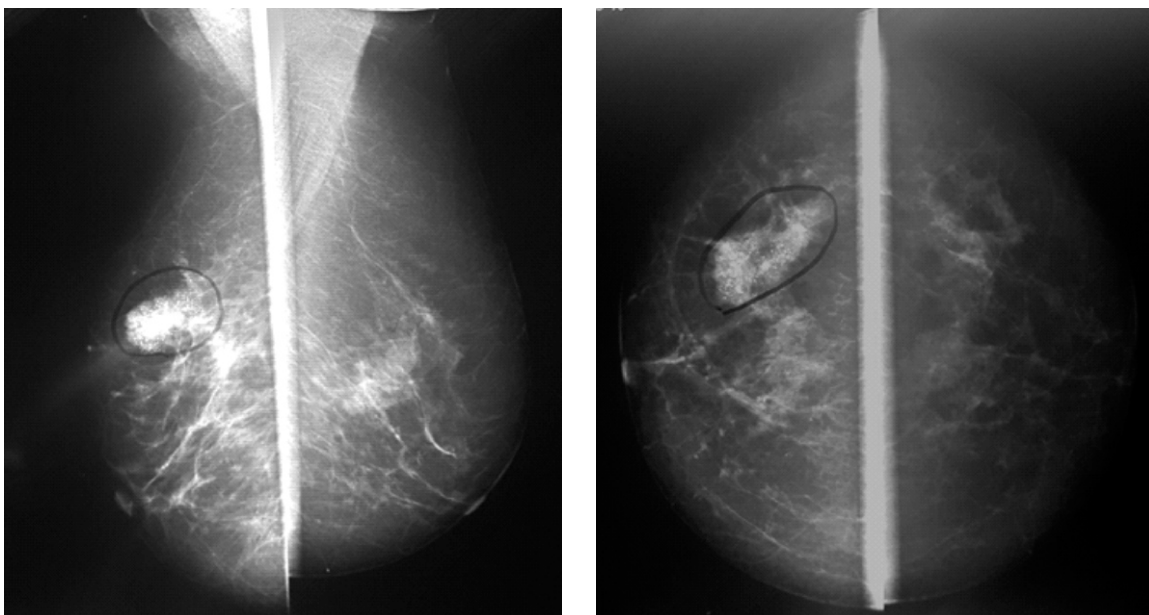


Figure 1. Bilateral mammography showed microcalcifications in upper outer quadrant of right breast.

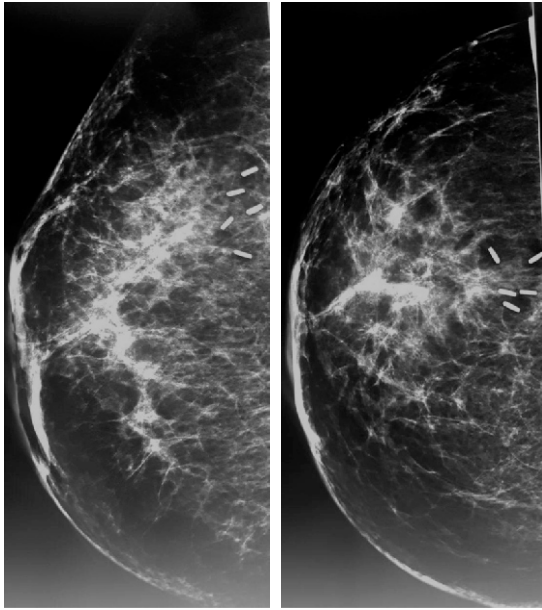


Figure 2. Mammography of right breast. In CC and MLO views microcalcifications and surgical clips can be seen.

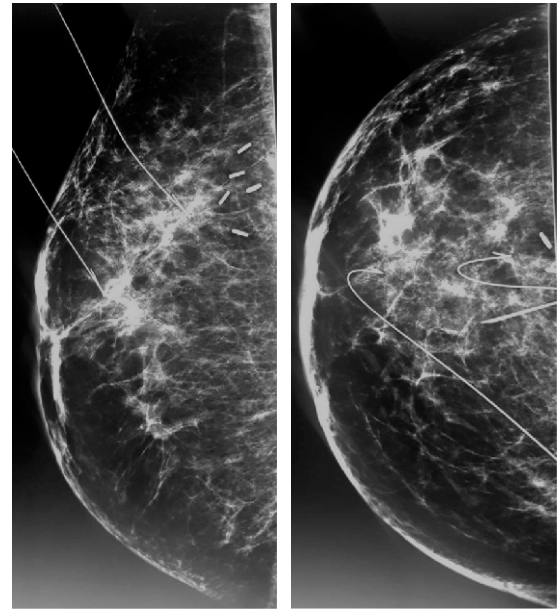


Figure 3. Mammography of right breast. Wire localization of microcalcifications are shown in CC and MLO views.

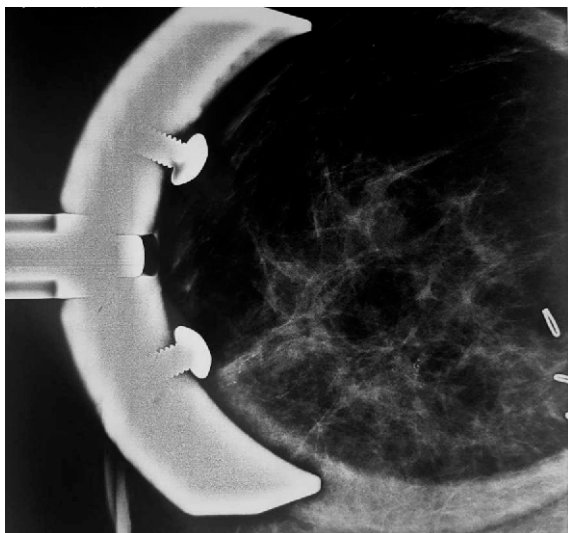


Figure 4. Focal compression magnification view (CC)

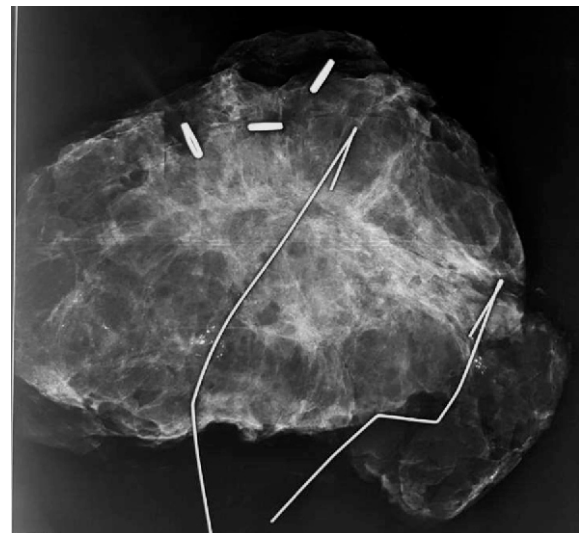


Figure 5. Specimen mammography which shows microcalcifications have been excised.

Question

The case was presented in the weekly breast multidisciplinary team session of the Department of Breast Surgery, Tehran University of Medical Sciences. The question was whether the patient should be operated again to obtain more extensive margins for DCIS or radiation therapy would be enough as the next step in the treatment of the patient.

Discussion

Breast-conserving therapy is the mainstay of treatment in most breast cancer patients for both invasive and *in situ* carcinomas. The therapy includes BCS, i.e., excision of the tumor with a margin of normal breast tissue, followed by whole-breast radiation therapy (WBRT). For many years,

the acceptable resection margin for DCIS has been 2 mm, although, in some reports and the new updates of some guidelines, the closer margins are also marked as acceptable in some circumstances. Despite these new recommendations, the safe margin in DCIS remains a matter of controversy in many institutional and national guidelines.

Changes in guidelines in the past years

According to the Society of Surgical Oncology (SSO) and the American Society for Radiation Oncology (ASTRO) guidelines in 2014, the rule of “no ink on tumor” is now accepted and efficient for invasive breast tumors. Nevertheless, in the case of DCIS, the recommendations in different guidelines have changed during the past few years. While the rule of “2-mm margins” was recommended by SSO-



ASTRO-ASCO (American Society of Clinical Oncology)^{8,9} and the National Institute for Health and Clinical Excellence (NICE),⁹ the Association of Breast Surgery (ABS) of the United Kingdom emphasized in 2015 that just 1-mm margin would be sufficient in resection of DCIS.¹⁰ Recently, the National Comprehensive Cancer Network (NCCN) reiterated that “no ink on tumor” rule would be enough in management of DCIS as well as invasive ductal carcinoma. This recommendation was based on the National Surgical Adjuvant Breast and Bowel Project (NSABP) trials in 2017^{9,11} and the American Society of Breast Surgeons (ASBS) recommendations.⁹ This discrepancy has led to variations in management practice in breast surgery centers. For example, a study of the variation in margin policy for BCT in 79 sites in the UK and Ireland in 2016, found that 53.2% of units accepted 1-mm and 38% accepted 2-mm margins for DCIS.⁶

Which margin width is supported by evidence?

A meta-analysis of 20 studies including a total number of 7883 DCIS patients with known margin status treated with BCT assessed the impact of margin width on ipsilateral breast tumor recurrence (IBTR). The status of ink on tumor (i.e. positive margin) was associated with higher rates of IBTR, whereas negative margins—especially those of at least 2 mm wide—had lower rates of IBTR. The effectiveness of margins when they were more than 2 mm is not supported by evidence.^{4,7,12,13} It should be taken into consideration that “negative margins” does not mean that there are not any residual DCIS in the breast.^{4,14} Even in unicentric DCIS, tumor can be multifocal with the skip involvement of a segment of the breast.⁴ This may happen in about two-third of well-differentiated DCIS cases. It is worth mentioning that the skipped lesions are mostly in 0 to 5 mm distance from the main lesion.¹⁴

Evidence shows significant decrease in IBTR for 2-mm margin in comparison with no ink on tumor (> 0 or 1 mm).⁴ The other important factors in IBTR risk are biology of the tumor, younger age, symptomatic presentation, presence of necrosis,¹⁴ side of anterior (skin) or posterior (pectoral fascia) margins, remnant microcalcification on mammography after excision, volume of DCIS tumor near the margin, cosmetic status after reexcision, life expectancy of the patient,⁴ and the adjuvant chemotherapy for invasive component or endocrine therapy.¹⁴

A study by Edinburgh Breast Unit on 466 patients with pure DCIS treated with BCS between 2000 and 2010, showed no increase in the rate of IBTR with margins of 1–2 mm in comparison with margins > 2 mm. The researchers concluded that margin width of 1 mm is sufficient in BCS of DCIS.¹²

In a study by Memorial Sloan Kettering Cancer Center on 2996 cases of DCIS who underwent BCS

from 1978–2010, in cases not receiving WBRT, wider margins were significantly associated with a lower rate of IBTR and may not be necessary in cases treated with WBRT.¹⁵

In a study by MD Anderson Cancer team on 1216 patients with DCIS undergoing BCS, at 10 years of follow-up, the researchers concluded that there was no significant difference in IBTR for patients with < 2-mm margins (no DCIS at the inked margin) who received adjuvant WBRT compared with patients with ≥ 2-mm margins, although local recurrence was significant in cases with < 2-mm margins not receiving WBRT.⁹

What is appropriate in the guidelines?

Pure DCIS: Most guidelines emphasized on 2-mm margin for pure DCIS but a margin of < 2 mm by itself is not an indication for mastectomy.¹⁴

DCIS with microinvasion: (size of invasive focus: ≤ 1 mm) rates of IBTR in microinvasive carcinomas are more similar to DCIS¹⁴ and they should be managed as DCIS for optimal margin.¹¹

Invasive cancer with associated DCIS: When the *in situ* component is more than 25% of the tumor bulk [called extensive intraductal component (EIC)], or the patient has lesser scattered foci of *in situ* carcinoma, management is more similar to invasive cancer than pure DCIS, even when the closer margins contain DCIS.⁴ It is worth emphasizing that IBTR rates in patients with EIC-positive tumors with negative margins at BCS are equal to cases without EIC.¹⁴ Based on NSABP trials, which defined negative margin as “no ink on tumor,” clinical experience of the physician is required for the decision of reexcision in patients with margin width of < 2 mm.¹³

Multidisciplinary team (MDT) recommendation

For this patient with foci of DCIS at a distance of < 1 mm from inked margin, members of breast MDT in Breast Division, Imam Khomeini Hospital, Tehran University of Medical Sciences recommended that neither reexcision of the margins for the inferior side of resection nor mastectomy was needed. Factors that promoted MDT to accept width margin were the presence of an invasive component in 80% of the specimen, the age of the patient, patient’s request for breast conservation, negative EIC, plan of adjuvant breast radiotherapy, plan of adjuvant chemotherapy and endocrine therapy. Thus, MDT members decided to accept the margin and informed the patient about the risk of recurrence and the need for adjuvant radiotherapy and follow-up imaging. The patient was referred to adjuvant chemotherapy and then adjuvant radiotherapy followed by endocrine therapy and follow-up imaging was planned for her.

References

1. Burstein HJ, Polyak K, Wong JS, Lester SC,



- Kaelin CM. Ductal carcinoma *in situ* of the breast. *N Engl J Med*. 2004;350(14):1430-41.
2. Dodwell D, Clements K, Lawrence G, Kearins O, Thomson CS, Dewar J, *et al*. Radiotherapy following breast-conserving surgery for screen-detected ductal carcinoma in situ: indications and utilisation in the UK. Interim findings from the Sloane Project. *Br J Cancer*. 2007;97(6):725-9.
 3. McCormick B, Winter K, Hudis C, Kuerer HM, Rakovitch E, Smith BL, *et al*. RTOG 9804: a prospective randomized trial for good-risk ductal carcinoma *in situ* comparing radiotherapy with observation. *J Clin Oncol*. 2015;33(7):709-15.
 4. Morrow M, Van Zee KJ, Solin LJ, Houssami N, Chavez-MacGregor M, Harris JR, *et al*. Society of Surgical Oncology-American Society for Radiation Oncology-American Society of Clinical Oncology Consensus Guideline on Margins for Breast-Conserving Surgery With Whole-Breast Irradiation in Ductal Carcinoma in Situ. *Pract Radiat Oncol*. 2016;6(5):287-95.
 5. Schulman AM, Mirrielees JA, Levenson G, Landercasper J, Greenberg C, Wilke LG. Reexcision Surgery for Breast Cancer: An Analysis of the American Society of Breast Surgeons (ASBrS) Mastery(SM) Database Following the SSO-ASTRO "No Ink on Tumor" Guidelines. *Ann Surg Oncol*. 2017;24(1):52-8.
 6. Tang SS, Kaptanis S, Haddow JB, Mondani G, Elsberger B, Tasoulis MK, *et al*. Current margin practice and effect on re-excision rates following the publication of the SSO-ASTRO consensus and ABS consensus guidelines: a national prospective study of 2858 women undergoing breast-conserving therapy in the UK and Ireland. *Eur J Cancer*. 2017;84:315-24.
 7. Marinovich ML, Azizi L, Macaskill P, Irwig L, Morrow M, Solin LJ, *et al*. The Association of Surgical Margins and Local Recurrence in Women with Ductal Carcinoma *In Situ* Treated with Breast-Conserving Therapy: A Meta-Analysis. *Ann Surg Oncol*. 2016;23(12):3811-21.
 8. Heelan Gladden AA, Sams S, Gleisner A, Finlayson C, Kounalakis N, Hosokawa P, *et al*. Re-excision rates after breast conserving surgery following the 2014 SSO-ASTRO guidelines. *Am J Surg*. 2017;214(6):1104-9.
 9. Kuerer HM, Smith BD, Chavez-MacGregor M, Albarracin C, Barcenas CH, Santiago L, *et al*. DCIS Margins and Breast Conservation: MD Anderson Cancer Center Multidisciplinary Practice Guidelines and Outcomes. *J Cancer*. 2017;8(14):2653-62.
 10. Association of Breast Surgery (ABS) Consensus Margin Width in Breast Conservation Surgery 2015. 2017 [Available from: www.associationofbreastsurgery.org.uk]
 11. NCCN clinical practice guidelines in oncology (NCCN guidelines): breast cancer. 2017 [Available from: http://www.nccn.org/professionals/physician_gls/pdf/breast.pdf.]
 12. Ekatah GE, Turnbull AK, Arthur LM, Thomas J, Dodds C, Dixon JM. Margin width and local recurrence after breast conserving surgery for ductal carcinoma in situ. *Eur J Surg Oncol*. 2017;43(11):2029-35.
 13. Morrow M. De-escalating and escalating surgery in the management of early breast cancer. *Breast*. 2017;34 Suppl 1:S1-S4.
 14. Pilewskie M, Morrow M. Margins in breast cancer: How much is enough? *Cancer*. 2018.
 15. Van Zee KJ, Subhedar P, Olcese C, Patil S, Morrow M. Relationship between margin width and recurrence of ductal carcinoma in situ: analysis of 2996 women treated with breast-conserving surgery for 30 years. *Annals of surgery*. 2015;262(4):623.