



DOI: 10.19187/abc.20185138-43

## Seroma Formation After Mastectomy and Axillary Dissection; A Comparison Among Blunt Dissection With Hemostat, Sharp Dissection With Metzenbaum Scissors, and Dissection With Harmonic Scissors

Famarz Karimian<sup>a</sup>, Hesam Kondori<sup>a</sup>, Seyed Mostafa Mosavi-Zadeh<sup>a</sup>, Mohamadreza Neishaboury<sup>a</sup>, Ali Abbaszadeh-Kasbi<sup>b</sup>, Mohammad Reza Keramati<sup>\*a</sup>

<sup>a</sup> Department of Surgery, Tehran University of Medical Sciences, Tehran, Iran

<sup>b</sup> Medical student, Tehran University of Medical Sciences, Tehran, Iran

## ARTICLE INFO

**Received:**  
13 October 2017  
**Revised:**  
19 January 2018  
**Accepted:**  
26 January 2018

**Key words:**

Harmonic scissors, seroma, breast cancer, axillary lymph node dissection, sentinel lymph node biopsy, modified radical mastectomy, breast conservation surgery

## ABSTRACT

**Background:** Seroma formation is a common complication after surgery for breast cancer. It may originate from dissected lymphatic ducts in axillary area. Two important predictive factors are the surgical technique, and instruments used during surgery. This study was conducted to determine the impact of three axillary dissection techniques, namely, blunt dissection with hemostat, sharp dissection with Metzenbaum scissors, and dissection with harmonic scissors, on seroma formation.

**Methods:** Patients with a tissue diagnosis of breast cancer who did not have metastasis, and were candidates for either breast conservation surgery (BCS) and sentinel lymph node biopsy (SLNB) with or without axillary lymph node dissection (ALND), or modified radical mastectomy (MRM) were included in a prospective study. Patients were randomly allocated to one of the above mentioned three groups. The incidence of seroma formation was compared among the groups.

**Results:** Sixty patients (age:  $50.25 \pm 10.33$  years) were enrolled for the study. At the end of the study, after four weeks of postoperative follow up, 19 patients developed seroma (31.6%), of whom 5 (26.3%) had dissection with harmonic scissors, 6 (31.5%) with Metzenbaum scissors, and 8 (42.1%) were dissected bluntly. There was no significant difference among groups regarding seroma formation ( $P = 0.583$ ).

**Conclusion:** Application of harmonic scissors for axillary dissection has no significant impact on seroma formation. However, MRM leads to significantly more seroma formation compared with BCS.

**Introduction**

Breast cancer has remained the second cancer-related cause of death in women worldwide and accounts for a significant volume of cancer surgeries. Surgical procedures for breast cancer

include breast conservation surgery (BCS), with or without sentinel lymph node biopsy (SLNB) or axillary lymph node dissection (ALND), and modified radical mastectomy (MRM), with the choice depending on the stage of the disease. Each technique has its own advantages and complications.<sup>1</sup>

Seroma formation is among the most common complications of surgery for breast cancer, with an incidence of 3% to 85%. It may significantly delay adjuvant therapy and increase the risk of infection.<sup>2</sup> On the other hand, surgery may be indicated for prolonged unresponsive cases.<sup>3</sup> The mechanism of seroma formation is not well understood; however,

**Address for correspondence:**

Mohammad Reza Keramati, M. D.  
Address: Department of Surgery, Imam Khomeini Hospital,  
Keshavarz Blvd, Tehran, Iran.  
Tel & Fax: +98-21-66581657  
Email: [dr\\_morezak@yahoo.com](mailto:dr_morezak@yahoo.com)



some risk factors or predictive factors are as follows: age, size of the breast, comorbidity, the number of involved axillary lymph nodes (LNs), history of previous breast or axillary surgery, and treatment with tamoxifen or heparin.<sup>4,5</sup> Lower fibrinogen levels in seroma compared with those in postoperative plasma<sup>6</sup> supports the theory that seroma most probably originates from lymph nodes.<sup>7</sup> MRM carries a greater risk of seroma formation than BCS does,<sup>8</sup> and an RCT found that seroma formation is much less after SLNB than after ALND.<sup>9</sup>

In conventional techniques, such as blunt dissection with hemostat and sharp dissection with Metzenbaum scissors, hemostasis is generally attained with electrocautery or ligation. Argon diathermy, laser scalpel, and ultrasonic scalpel decrease intraoperative blood loss. However, they are time-consuming and increase postoperative seroma formation and the risk of tissue thermal damage.<sup>10,11</sup>

This prospective study was carried out to compare the prevalence of seroma formation following surgery for breast cancer, when axillary surgery was performed using harmonic scissors, hemostat scissors, or Metzenbaum scissors.

### Methods

This was a prospective study conducted in a tertiary referral university hospital during 2013 and 2014. The primary goal of the study was to measure seroma formation in breast cancer patients who underwent BCS and SLNB (with or without ALND), or MRM when axillary dissection was performed with harmonic scissors, hemostat, or Metzenbaum scissors.

Inclusion criteria were (1) having histopathologically diagnosed breast cancer, (2) having no distant metastasis, and (3) being candidate for BCS and SLNB (with or without ALND), or BCS and ALND, or MRM. Exclusion criteria were having (1) previous breast or axillary surgery, (2) history of radiation to breast, axilla, or upper limb, (3) history of systemic chemotherapy for any reason, (4) any pathologic process involving the skin of the breast, axilla, or upper limb, (5) a motor disorder of upper limb, and (6) no consent.

Sampling was done by excel quadratic block method. Patients were randomly allocated to one of the following groups:

1. Axillary dissection using blunt dissection with hemostat. Bleedings were either cauterized or ligated.

2. Axillary dissection using sharp dissection with Metzenbaum scissors. Bleedings were either cauterized or ligated.

3. Axillary dissection using harmonic scissors. Axillary dissection was performed entirely by harmonic scissors.

Allocation was done by simple randomization

technique. Patients entering the operating room were allocated to group 1, then 2, and then 3, and this round was repeated.

The surgeon, preoperative preparation, and postoperative care (including wound care, ambulation, limb activity, and physical therapy) were the same for each patient. Diagnosis of seroma formation and its evaluation was performed by the same research team member, who was a 4th-year resident of surgery. Only the operating surgeon knew which patient belonged to which group, and the patients and the researcher (the 4th-year resident) were blinded.

The study variables were age, the type of breast surgery, the type of axillary dissection, the technique of axillary dissection, the number of involved lymph nodes (pN), tumor size (pT), tumor grade, microscopic diagnosis, estrogen receptor (ER) status, progesterone receptor (PR) status, human epidermal growth factor receptor 2 (HER2) status, Ki-67 status, and seroma formation.

Seroma formation was defined as any clinically detectable collection of serum requiring aspiration. Drainage in the first three postoperative days was recorded. Patients were then visited 1, 2, and 4 weeks after the operation and before the start of adjuvant therapy, and were examined for seroma formation. Data were recorded, finalized, and analyzed using IBM SPSS software, version 20.

Informed consent form was signed by every patient before entering the study. Data confidentiality was observed and the patients were free to leave the study at any time. No extra charge was imposed on the patients. The researchers were committed to the World Medical Association's Declaration of Helsinki throughout the study.

### Results

Sixty patients (age:  $50.25 \pm 10.33$ ) were assigned to three groups of 20 each: blunt dissection with hemostat, sharp dissection with Metzenbaum scissors, and dissection with harmonic scissors (Table 1).

Of 20 patients who had blunt axillary dissection with hemostat, 16 (80%) underwent MRM and 4 (20%) BCS; of 20 patients who received axillary dissection with Metzenbaum scissors, 10 (50%) underwent MRM and 10 (50%) BCS; and of 20 patients in the group who had axillary dissection with harmonic scissors, 12 (60%) underwent MRM and 8 (40%) BCS.

In total, 38 (63.3%) patients underwent MRM. Axillary dissection was performed using harmonic scissors in 12 (31.5%), using Metzenbaum scissors in 10 (26.5%), and using hemostat in 16 (42%) patients. Twenty-two (27.7%) patients underwent BCS. Axillary dissection was performed with harmonic scissors in 8 (36.5%), with Metzenbaum scissors in 10 (45.5%), and with hemostat in 4 (18%) patients.

The most common tissue diagnosis was invasive



After preoperative chemotherapy, a breast-conservation surgery waductal carcinoma, (n = 47, 78.3%), followed by invasive lobular carcinoma (n = 10, 16.7%) and infiltrating ductal carcinoma (n = 3, 5%). The mean tumor size was  $3.4 \pm 1.53$  cm, and the mean number of involved axillary lymph nodes was  $2.86 \pm 3.27$  (Table 1).

Ten (16.7%) patients were at stage Ia, 17 (28.3%) at stage Ib, 21 (35%) at stage II, and 12 (20%) at stage III of breast cancer, according to TNM classification (Table 1).

Also, 34 (56.7%) patients were ER+ and PR+, 12 (20%) were HER2-positive, and 4 (6.7%) were Ki-67-positive (Table 1).

No significant difference was found among the three groups regarding age ( $P = 0.4$ ), tumor size ( $P = 0.944$ ), the number of involved lymph nodes ( $P = 0.789$ ), (pathologic type of tumor ( $P = 0.668$ ), and the stage of disease ( $P = 0.978$ ). Neither was there any significant difference in receptor status (ER:  $P$

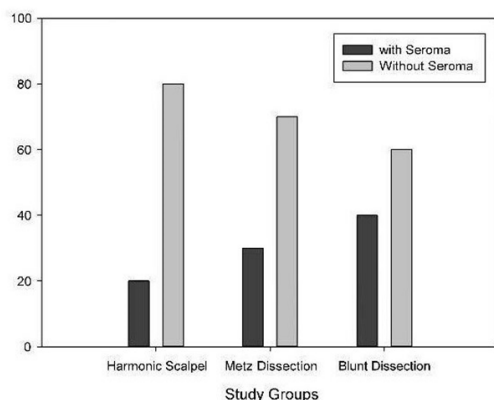
$= 0.934$ , PR:  $P = 0.934$ , HER2:  $P = 0.892$ , and Ki-67:  $P = 0.329$ ) (Table 1).

s possible in 22 patients (55%), and the rest of them underwent mastectomy. Pathological complete response (ypT0/is ypN0) was achieved in 13 patients (33%). Only 3 patients (15.8%) with AR-positive tumors achieved a pCR. The rate of pCR according to the expression or absence of AR, ER, PR, and HER2 is reported in Table 2. AR-positive tumors had 82% less chance of achieving a pCR compared with patients with AR-negative tumors (OR = 0.18; 95% CI, 0.04–0.75).

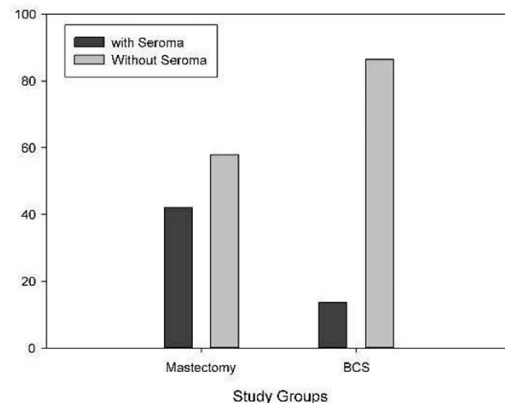
After four weeks of follow up, and at the end of the study, 19 (31.6%) patients developed seroma. The frequencies of seroma formation in patients in different groups were 5 (20%) (dissection using harmonic scissors), 6 (30%) (Metzenbaum scissors), and 8 (40%) (hemostat). Analysis using chi-square test showed no significant difference in seroma formation among the groups ( $P = 0.583$ ) (Figure 1).

**Table 2.** Pathological complete response according to the Immunohistochemical expression of breast cancer receptors

Variable	Blunt dissection with hemostat	Dissection with Metz	Harmonic scalpel	<i>P</i>
Age	50.25 ± 9.27	48.65 ± 10.74	51.85 ± 11.16	0.400
Tumor size	34.15 ± 13.96	35 ± 15.55	33.85 ± 17.17	0.944
Number of involved lymph nodes	2.55 ± 2.45	2.95 ± 3.05	3.10 ± 4.20	0.789
Stage of the disease			4 (20%)	0.978
Ia	4 (20%)	2 (10%)	5 (25%)	
Ib	5 (25%)	7 (35%)	7 (35%)	
II	5 (25%)	9 (45%)	4 (20%)	
III	6 (30%)	2 (10%)		
Histologic type of tumor				0.668
Invasive lobular	4 (20%)	2 (10%)	4 (20%)	
Infiltrating ductal	0	2 (10%)	1 (5%)	
Invasive ductal	16 (80%)	16 (80%)	15 (75%)	
ER expression	12 (60%)	9 (45%)	11 (55%)	0.934
PR expression	12 (60%)	9 (45%)	11 (55%)	0.934
HER2 expression	4 (20%)	7 (35%)	3 (15%)	0.892
Ki-67 expression	2 (10%)	5 (25%)	2 (10%)	0.329
Technique of surgery				0.134
MRM	16 (80%)	10 (50%)	12 (60%)	
BCS	4 (20%)	10 (50%)	8 (40%)	



**Figure 1.** Frequency of seroma in study groups



**Figure 2.** Frequency of seroma after MRM and BCS



Correlation of demographic and pathologic characteristics with seroma formation was also evaluated. No correlation was found between seroma formation and age ( $P = 0.858$ ), tumor size ( $P = 0.920$ ), disease stage ( $P = 0.415$ ), the type of cancer ( $P = 0.271$ ), ER and PR status ( $P = 0.781$ ), HER2 expression ( $P = 0.775$ ), or Ki-67 expression ( $P = 0.778$ ).

Of 38 patients who underwent MRM, 16 (42.1%) developed seroma: 5 were dissected using harmonic scissors, 5 using Metzenbaum scissors, and 6 using hemostat.

Only 3 (9%) out of 22 patients who had BCS developed seroma: 1 was dissected using Metzenbaum scissors and 2 using hemostat. None of the patients who underwent BCS and were dissected with harmonic scissors developed seroma.

The difference in the incidence of seroma formation between MRM and BCS patients was significant ( $P = 0.022$ ) (Figure 2).

### Discussion

Although the mechanism of seroma formation is not fully understood, some of the risk factors or predictive factors are as follows: age, size of the breast, comorbidity, the number of involved axillary lymph nodes (Lns), history of previous breast or axillary surgery, and treatment with tamoxifen or heparin.<sup>4,5</sup> One theory holds that seroma forms because of chronic inflammatory reaction inflicted by surgery.<sup>5</sup> This reaction leads to increased serosal fluid accumulation in response to elevated fibrinolytic activity in seroma and lymphatic fluid.<sup>12</sup> On the other hand, low fibrinogen level in seroma compared with that in postoperative plasma<sup>6</sup> supports the hypothesis that seroma is most probably originated from lymph nodes.<sup>7</sup> A combination of different techniques and instruments affects seroma formation<sup>10</sup> and may be the reason for various amounts of seroma reported in different studies. Radical mastectomy leads to higher rates of seroma formation than simple mastectomy do.<sup>13,14</sup> This difference is not significant between radical mastectomy and MRM.<sup>14</sup> Immediate breast reconstruction after MRM decreases the risk of seroma formation compared with delayed reconstruction.<sup>15</sup>

To obviate the dead space, Halstead recommended a short upper skin flap sutured to pectoral fascia at the level of lower margin of the 1st rib; the remaining wound would be covered with skin graft.<sup>16</sup> Orr, in 1951, used tension sutures to tighten the skin flaps to the chest wall.<sup>17</sup> Keyes and colleagues used multiple sutures to attach the skin flaps to the chest wall.<sup>18</sup> Other techniques such as suturing the flaps to subcutaneous tissue and avoiding drainage in BCS were also implicated to reduce seroma formation.<sup>19,20</sup>

No study, as yet, has shown the efficacy using laser scalpel or ultrasonic scissors in prevention of seroma formation.<sup>21</sup> Other techniques such as avoiding drainage in BCS<sup>20</sup> were also implicated to reduce seroma formation. Whitfield and Rainbury

did not find any significant difference in seroma formation between suction drainage and closed siphon drainage.<sup>22</sup> Pathologic specifications of tumors and patient-related factors do not seem to affect seroma formation, except for weight, which shows a direct relation with seroma formation.<sup>2,23</sup> No particular relationship has been reported between seroma formation and hormone receptors, axillary lymph node involvement, the grade of the tumor, or the stage of disease.<sup>15, 23-25</sup> This lack of relationship also been observed for anemia, smoking, diabetes, and breast size as well as tumor size, tumor location, the size of the resected specimen, and the pathologic type of cancer.<sup>14,24,26</sup>

Instruments based on piezoelectric mechanism induce coagulation by denaturing collagen and elastin in soft tissue, blood, and lymphatic vessels through high-frequency vibration (50–60 MHz).<sup>27</sup> This produces less heat and results in less thermal energy transfer to adjacent tissues compared with electrocautery.<sup>28</sup> Harmonic Focus<sup>®</sup>, introduced more than a decade ago, cuts and coagulates lymphatic ducts safely and is utilized for hepatic, thyroid, and breast surgery among others.<sup>29</sup>

The primary outcome of this study was postoperative seroma formation, which occurred in 19 patients. There was no significant difference in age, tumor size, number of involved lymph nodes, type of the tumor, the stage of disease, and the expression of ER, PR, HER2, and Ki-67 among the groups, so the groups were matched by these variables. The studied variables including demographic specifications, the pathologic variety of the tumor, or the methods of surgery were not associated with postoperative seroma formation.

The frequency of seroma formation was lower in the harmonic scissors group than the other groups, although the difference was not significant. No patients who underwent BCS with harmonic scissors developed seroma. Although it cannot be substantiated statistically, it can be taken as a suggesting clue for future study.

There was no correlation between seroma formation and age, tumor size, the stage of disease, the type of cancer, or the expression of ER/PR/HER2/Ki-67. Therefore, it can be concluded that these factors do not relate to seroma formation.

The only variable that showed a significant correlation with seroma formation was the principal technique of mastectomy, i.e., MRM vs. BCS. Regardless of the method used for axillary dissection, seroma formation rate was higher after MRM than after BCS.

Orr *et al* published the data of 72 patients who underwent MRM, partial mastectomy with axillary dissection, or simple mastectomy. The total incidence rate of seroma formation was 11%, the highest incidence (45.67%) being observed in patients who had simple mastectomy and were



discharged at postoperative day 1.<sup>30</sup> Deo and Shukla<sup>31</sup> reported the application of harmonic scissors in MRM for the first time. They showed a decrease in intraoperative bleeding and duration of drainage compared with conventional clamp and tie. Galatius and colleagues<sup>21</sup> studied 59 patients who underwent surgery using harmonic scissors (n = 30) or conventional scissors (n = 29). On follow-up, 20 patients in each arm had developed seroma: a total of 40 (67%). There was no significant difference in the frequency of seroma formation between harmonic scissors and conventional ones. Lumachi *et al* conducted an RCT and showed that using harmonic scissors, compared with surgical scalpel and tying, led to significantly less seroma formation.<sup>32</sup>

Although no study with a similar design has been published yet, studies have produced inconsistent results. Khan and colleagues studied 150 patients who were operated using either harmonic scissors or electrocautery.<sup>33</sup> In the harmonic scissors group, the incidence of seroma formation was 21.3% vs. 33.3% in the electrocautery group, which was significantly less. While we had just about the same percentages in harmonic vs. Metzenbaum, the difference was not significant.

The relationship between MRM and seroma formation has been studied formerly. Gonzalez and colleagues reported seroma formation rate of 19.5% for MRM and 9.2% for BCS ( $P = 0.001$ ).<sup>12</sup> In a meta-analysis by Kuroi *et al*, 51 clinical trials, 7 cohort studies, and 7 retrospective studies were included. They concluded that MRM had a significant association with seroma formation. The present study reached the same finding: MRM led to significantly higher seroma formation compared with BCS ( $P = 0.022$ ).<sup>23</sup>

The limitations of this study were the small number of patients in each group, the heterogeneity of groups considering techniques of axillary dissection, heterogeneity of groups considering the extent of mastectomy, and the use of simple randomization. Also, we should have ideally divided the BCS patients into those who had BCS + SLNB, BCS + SLNB + ALND, and BCS + ALND. Again, the small number of patients in each of these subgroups would impede meaningful statistical analysis.

These limitations may have hypothetically affected our results. Therefore, we believe that a large-scale study with a better randomization method comparing the use of harmonic vs conventional scissors in patients with the same extent of mastectomy may better clarify the issue.

The use of harmonic scissors for axillary dissection in MRM, BCS with SLNB (with or without ALND), and BCS with ALND does not decrease the incidence of postoperative seroma formation significantly. Also, there is no association between age, tumor specifications, or molecular

markers status and seroma formation. The only effective factor is the extent of mastectomy, with MRM leading to significantly higher rates of seroma formation than BCS.

### Conflict of Interest

The authors have none to declare.

### References

1. Jemal A, Siegel R, Ward E, Hao Y, Xu J, Murray T, *et al*. Cancer statistics, 2008. CA: a cancer journal for clinicians. 2008;58(2):71-96.
2. Kumar S, Lal B, Misra MC. Post-mastectomy seroma: a new look into the aetiology of an old problem. Journal of the Royal College of Surgeons of Edinburgh. 1995;40(5):292-4.
3. Stanczyk M, Grala B, Zwierowicz T, Maruszynski M. Surgical resection for persistent seroma, following modified radical mastectomy. World journal of surgical oncology. 2007;5:104.
4. Bryant M, Baum M. Postoperative seroma following mastectomy and axillary dissection. The British journal of surgery. 1987;74(12):1187.
5. Watt-Boolsen S, Nielsen VB, Jensen J, Bak S. Postmastectomy seroma. A study of the nature and origin of seroma after mastectomy. Danish medical bulletin. 1989;36(5):487-9.
6. Bonnema J, Ligtenstein DA, Wiggers T, van Geel AN. The composition of serous fluid after axillary dissection. The European journal of surgery : Acta chirurgica. 1999;165(1):9-13.
7. Bonnema J, van Geel AN, Wiggers T, Ligtenstein DA. Perioperative and postoperative tranexamic acid reduces the local wound complication rate after surgery for breast cancer. The British journal of surgery. 1994;81(11):1693.
8. Gonzalez EA, Saltzstein EC, Riedner CS, Nelson BK. Seroma formation following breast cancer surgery. The breast journal. 2003;9(5):385-8.
9. Purushotham AD, Upponi S, Klevesath MB, Bobrow L, Millar K, Myles JP, *et al*. Morbidity after sentinel lymph node biopsy in primary breast cancer: results from a randomized controlled trial. Journal of clinical oncology : official journal of the American Society of Clinical Oncology. 2005;23(19):4312-21.
10. Porter KA, O'Connor S, Rimm E, Lopez M. Electrocautery as a factor in seroma formation following mastectomy. American journal of surgery. 1998;176(1):8-11.
11. Sutton PA, Awad S, Perkins AC, Lobo DN. Comparison of lateral thermal spread using monopolar and bipolar diathermy, the Harmonic Scalpel and the Ligasure. The British journal of surgery. 2010;97(3):428-33.
12. Oertli D, Laffer U, Haberthuer F, Kreuter U, Harder F. Perioperative and postoperative tranexamic acid reduces the local wound complication rate after surgery for breast cancer.



- Br J Surg. 1994;81(6):856-9.
13. Aitken DR, Hunsaker R, James AG. Prevention of seromas following mastectomy and axillary dissection. *Surgery, gynecology & obstetrics*. 1984;158(4):327-30.
  14. Say CC, Donegan W. A biostatistical evaluation of complications from mastectomy. *Surgery, gynecology & obstetrics*. 1974;138(3):370-6.
  15. Woodworth PA, McBoyle MF, Helmer SD, Beamer RL. Seroma formation after breast cancer surgery: incidence and predicting factors. *The American surgeon*. 2000;66(5):444-50; discussion 50-1.
  16. Almond LM, Khodaverdi L, Kumar B, Coveney EC. Flap Anchoring Following Primary Breast Cancer Surgery Facilitates Early Hospital Discharge and Reduces Costs. *Breast care*. 2010;5(2):97-101.
  17. Orr TG J. An incision and method of wound closure for radical mastectomy. . *Annals of surgery*. 1951;133:565-6.
  18. Keyes EL, Hawk BO, Sherwin CS. Basting the axillary flap for wounds of radical mastectomy. *AMA archives of surgery*. 1953;66(4):446-51.
  19. Larsen BB, Hagan C, Jr. Fixation of skin flaps in radical mastectomy by subcutaneous sutures; observations. *AMA archives of surgery*. 1955;71(3):419-23.
  20. Schultz I, Barholm M, Grondal S. Delayed shoulder exercises in reducing seroma frequency after modified radical mastectomy: a prospective randomized study. *Annals of surgical oncology*. 1997;4(4):293-7.
  21. Galatius H, Okholm M, Hoffmann J. Mastectomy using ultrasonic dissection: effect on seroma formation. *Breast*. 2003;12(5):338-41.
  22. Whitfield PC, Rainsbury RM. Suction versus siphon drainage after axillary surgery for breast cancer: a prospective randomized trial. *The British journal of surgery*. 1994;81(4):547.
  23. Kuroi K, Shimosuma K, Taguchi T, Imai H, Yamashiro H, Ohsumi S, *et al*. Evidence-based risk factors for seroma formation in breast surgery. *Japanese journal of clinical oncology*. 2006;36(4):197-206.
  24. Antonio M, Pietra T, Domenico L, Massimo D, Ignazio R, Antonio N, *et al*. Does LigaSure reduce fluid drainage in axillary dissection? A randomized prospective clinical trial. *Ecancermedalscience*. 2007;1:61.
  25. Browse DJ, Goble D, Jones PA. Axillary node clearance: who wants to immobilize the shoulder? *European journal of surgical oncology : the journal of the European Society of Surgical Oncology and the British Association of Surgical Oncology*. 1996;22(6):569-70.
  26. Chilson TR, Chan FD, Lonser RR, Wu TM, Aitken DR. Seroma prevention after modified radical mastectomy. *The American surgeon*. 1992;58(12):750-4.
  27. Brill AI. Bipolar electrosurgery: convention and innovation. *Clinical obstetrics and gynecology*. 2008;51(1):153-8.
  28. Koch C, Friedrich T, Metternich F, Tannapfel A, Reimann HP, Eichfeld U. Determination of temperature elevation in tissue during the application of the harmonic scalpel. *Ultrasound in medicine & biology*. 2003;29(2):301-9.
  29. Cheang T, Hanna SS, Wright FC, Law CH. Use of a collagen-sealing device in hepatic resection: a comparative analysis to standard resection technique. *HPB : the official journal of the International Hepato Pancreato Biliary Association*. 2006;8(3):194-9.
  30. Orr RK, Ketcham AS, Robinson DS, Moffat FL, Tennant ND. Early discharge after mastectomy. A safe way of diminishing hospital costs. *The American surgeon*. 1987;53(3):161-3.
  31. Deo SV, Shukla NK, Asthana S, Niranjana B, Srinivas G. A comparative study of modified radical mastectomy using harmonic scalpel and electrocautery. *Singapore medical journal*. 2002;43(5):226-8.
  32. Lumachi F, Brandes AA, Burelli P, Basso SM, Iacobone M, Ermani M. Seroma prevention following axillary dissection in patients with breast cancer by using ultrasound scissors: a prospective clinical study. *European journal of surgical oncology : the journal of the European Society of Surgical Oncology and the British Association of Surgical Oncology*. 2004;30(5):526-30.
  33. Khan S, Khan S, Chawla T, Murtaza G. Harmonic scalpel versus electrocautery dissection in modified radical mastectomy: a randomized controlled trial. *Annals of surgical oncology*. 2014;21(3):808-14.