



DOI: 10.32768/abc.2025121105-113



The Role of Apparent Diffusion Coefficient (ADC) in Differentiating Between Benign and Malignant Breast Lesions in a Sample of Iranian Women

Zubin Souria, Pejman Kiani^a

Radiology Department, School of Medicine, Poursina Hospital, Guilan University of Medical Sciences, Rasht, Iran

ARTICLE INFO

Received:

5 November 2024

Revised:

22 December 2024

Accepted:

28 December 2024

Keywords:

MRI, Diffusion, Apparent diffusion coefficient (ADC), Benign breast lesions, Breast Cancer

ABSTRACT

Background: Breast cancer is the most prevalent cancer among women, emphasizing the need for early detection and accurate diagnosis. This study investigates the role of the Apparent Diffusion Coefficient (ADC) in distinguishing between benign and malignant breast lesions using Magnetic Resonance Imaging (MRI) and Diffusion-Weighted Imaging (DWI). A retrospective cross-sectional study was conducted involving 96 patients with breast lesions who underwent MRI and DWI scans.

Methods: Patients were selected from among those who had MRI and DWI scans with b-values of 0, 800, and 1000 s/mm². ADC values were calculated by plotting the Region of Interest (ROI) and extracting corresponding values. Histological evaluations confirmed the diagnosis of the lesions. Statistical analyses included calculating accuracy, sensitivity, and specificity, along with Receiver Operating Characteristic (ROC) curve analysis to determine the optimal cut-off value.

Results: The ADC values demonstrated an accuracy of 92.5%, sensitivity of 93.2%, and specificity of 91.2% in differentiating between benign and malignant lesions. The ROC curve analysis established a cut-off value of 1.44×10^{-3} mm²/s for effective differentiation.

Conclusion: ADC values can serve as a reliable biomarker for distinguishing breast lesions, potentially reducing unnecessary biopsies for benign cases and aiding clinicians in treatment decisions. The integration of ADC measurements into clinical practice could enhance patient management in breast cancer. Further research is warranted to validate these findings and explore additional markers to improve diagnostic accuracy in breast cancer management.

Copyright © 2025. This is an open-access article distributed under the terms of the [Creative Commons Attribution-Non-Commercial 4.0 International License](https://creativecommons.org/licenses/by-nc/4.0/), which permits copy and redistribution of the material in any medium or format or adapt, remix, transform, and build upon the material for any purpose, except for commercial purposes.

INTRODUCTION

Breast cancer is the most common cancer globally, surpassing lung cancer, and is the fifth leading cause of cancer death. Incidence rates vary significantly worldwide, with higher rates in developed countries and lower rates in Africa and Asia. Late-stage diagnoses in transitioning countries

contribute to low survival rates. In Iran, breast cancer accounts for 12.9% of all cancers, with rising incidence expected to exceed 70 per 100,000 by 2030. Factors like lifestyle changes and lack of awareness contribute to late diagnoses. Effective early detection and screening programs are crucial to reducing the burden of breast cancer in Iran.¹⁻³

Early diagnosis and treatment are regarded as the most effective strategies for reducing mortality rates. Nevertheless, despite the advancement of various imaging modalities, including mammography and ultrasound, as well as the widespread use of physical

***Address for correspondence:**

Pejman Kiani, PhD,
 Associated Professor, Radiology Department, School of
 Medicine, Guilan University of Medical Sciences, Rasht,
 Iran
 Email: pkia59@yahoo.com



examination and palpation in breast cancer diagnosis, differentiation between malignant and benign breast lesions continues to pose difficulties.⁴

Mammography is established as the primary imaging modality for the diagnosis and screening of breast cancer. Nevertheless, its specificity is relatively low, and its diagnostic efficacy is diminished when assessing dense breast tissue.^{5,6} Ultrasound imaging was previously utilized to differentiate solid masses from cystic ones. However, with advancements in ultrasound technology, the capability to distinguish between malignant and non-malignant breast lesions has improved. Furthermore, the combination of ultrasound with breast magnetic resonance imaging (MRI) and digital mammography enhances the specificity and sensitivity of imaging.⁷

In breast MRI, both morphological features and mass perfusion are crucial for evaluating breast parenchyma. While routine MRI sequences demonstrate high sensitivity (over 90%) for detecting breast cancer, they often suffer from low specificity. This means that benign and malignant lesions may present similar imaging characteristics, complicating the diagnosis. To enhance specificity, it is essential to consider both morphological and kinetic features during interpretation. As breast MRI technology evolves, its role in diagnosis and management continues to expand, making it an indispensable tool in breast imaging.⁸⁻¹¹

Diffusion-weighted imaging (DWI) enhances MRI specificity by mapping water diffusion in tissues. This advanced, non-invasive technique captures the random motion of water molecules, providing critical insights into tissue microstructure and pathology. DWI is particularly valuable in diagnosing conditions like stroke and tumors, as it reveals changes in cellular environments which standard MRI may overlook. By integrating DWI into MRI protocols, clinicians can improve diagnostic accuracy and better assess disease progression.¹²

Brownian motion, the thermal movement of water molecules, causes diffusion. This movement in tissue is measured by the apparent diffusion coefficient (ADC).^{13,14}

In malignant tumors, the increased proliferation of cells results in a higher cell density, which subsequently limits the diffusion of water molecules, a phenomenon referred to as restricted diffusion. As a result, malignant tumors exhibit a lower apparent diffusion coefficient (ADC) in comparison to benign tumors.¹⁵⁻¹⁸ Combining diffusion with dynamic sequences can significantly enhance the sensitivity and specificity of breast MRI, making it a vital tool in breast cancer detection. This study aims to investigate the role of ADC values in differentiating between benign and malignant breast lesions in a sample of

Iranian women. The purpose of this study is to evaluate the diagnostic accuracy of ADC values in breast MRI and to determine the optimal ADC cut-off value for differentiating between benign and malignant lesions. This study contributes to the existing literature on the use of ADC values in breast MRI and provides insights into the potential role of this technique in improving the diagnosis and treatment of breast cancer in Iranian women. Despite the publication of numerous studies evaluating the role of DWI MRI in differentiating breast lesions, including several meta-analyses conducted in China, there remains a gap in research focused on specific populations. The existing literature often aggregates data from diverse ethnic groups, which may not accurately reflect the ADC characteristics pertinent to Iranian women. This population-specific approach is crucial for developing tailored diagnostic protocols that consider regional variations in breast cancer pathology. Additionally, the optimal ADC thresholds for differentiating between malignant and benign breast lesions may vary across different populations and studies.

This article aims to investigate the role of ADC values in differentiating between benign and malignant breast lesions in specific populations, particularly in Middle Eastern countries such as Iran. By analyzing a well-defined cohort and correlating ADC measurements with histopathological findings, this study seeks to establish clinically relevant ADC thresholds that can enhance diagnostic accuracy and improve patient management strategies. Ultimately, our findings may contribute to more effective early detection of breast cancer and reduce the burden of unnecessary invasive procedures in this population.

METHODS

Study design and participants

The study included patients who underwent breast MRI examinations at Pars Hospital Imaging Center in Rasht, Iran, over a two-year period from 2021 to 2023. The eligibility criteria for inclusion in this study were: patients between the ages of 20 and 81 years who underwent breast MRI examinations for one of the following reasons: a suspicious mass found on screening mammography, a clinical referral for breast MRI due to a palpable breast lump or abnormal clinical examination, a personal or family history of breast cancer or other high-risk features that warranted breast MRI screening, or a breast ultrasound Imaging Reporting and Data System (BI-RADS) score of 4 or higher on previous imaging examinations. The study only included patients with B4 and B5 lesions who underwent a biopsy. This is because the primary aim of the study was to distinguish between benign and malignant lesions,



and the diagnosis of malignancy can only be confirmed through a biopsy. From an ethical perspective, it would not be justified to subject patients with lesions that are likely to be benign (BI-RADS 1-3) to an invasive procedure like a biopsy. However, they had two 6-month follow-up ultrasound scans and there had been no change in the size or type of lesion. Similarly, patients with lesions that are highly suggestive of malignancy (BI-RADS 5) may require immediate treatment, and a biopsy may be part of their diagnostic workup. However, patients with B4 lesions, which have a higher likelihood of malignancy, may require additional diagnostic testing to confirm or rule out cancer. Similarly, patients with B5 lesions, which are highly suggestive of malignancy, may require a biopsy to confirm the diagnosis and guide treatment. By only including patients with B4 and B5 lesions who underwent a biopsy, the study aimed to validate the role of ADC values in distinguishing between benign and malignant lesions in a cohort where the diagnosis of malignancy can be confirmed. This approach also ensured that the study results are applicable to the most challenging situations where the diagnosis is uncertain. The sample size was calculated based on the formula for estimating the required sample size for a cross-sectional study. Assuming a 90% confidence level and a 5% margin of error, the calculated sample size was 130 patients. To account for any potential losses or exclusions, a total of 142 patients were included in the study. The patients were selected from the hospital's database of breast MRI examinations, and their medical records and imaging data were reviewed to ensure they met the eligibility criteria.

Patients underwent routine 1.5-T breast MRI examinations and diffusion-weighted imaging (DWI) using a 1.5 Tesla Siemens scanner. To ensure patient comfort during the procedure, the participants were placed in a prone position on a four-channel, phased-array surface coil, with their arms positioned above their heads.

MRI parameter and outcome measurements

The image acquisition process commenced with a three-plane localizer, which was followed by the application of additional imaging sequences.

1) Unenhanced imaging with a T1-weighted non-fat saturated pulse sequence for identification of cysts and fats, as well as cysts containing met hemoglobin with echo time (TE) of 15 ms, repetition time (TR) of 705 ms, and field of view (FOV) of 270 - 340 mm (acquisition matrix, 416×320; slice thickness, 5 mm; spacing in the axial plane, 6 mm)

2) Unenhanced imaging with a T2-weighted STIR pulse sequence (TR, 2900; TE, 45; TI, 150; FOV, 270

- 340; acquisition matrix, 320×192; thickness, 5 mm; spacing in the axial plane, 6 mm)

3) Diffusion imaging with an echo-planar pulse sequence (TR, 6600; TE, 160; b-value, 1000; FOV, 270 - 340; acquisition matrix, 256×192; thickness, 4 mm; spacing in the axial plane, 4 mm)

4) Multiphase contrast-enhanced dynamic imaging with a 3D T1-weighted vibrant pulse sequence (TR, 5 sec). Imaging was carried out once before and five times after intravenous gadolinium-DTPA injection (0.1 mmol/kg) with the following parameters: flip angle, 10°; TE, 2 ms; FOV, 270 - 340 mm; TR, 5 ms; minimum matrix, 360×360; and slice thickness ≤1 mm with an overlap of nearly 10% without any gaps.

Automatically generated images, besides MIP images in the sagittal, coronal, and axial views, were acquired. The lesions were distinguished according to the radiologist's report, simultaneous comparison of dynamic and subtraction images (Figure 1), and DWI findings with an ADC map. The mean ADC was measured using a circular ROI. ROI was plotted on the section with the largest surrounding tumor area and the lowest mean ADC; all the steps were controlled by the radiologist.

To ensure accuracy and consistency, a two-stage verification process was implemented. The regions of interest (ROIs) were initially marked by an expert radiographer, followed by a collaborative verification process with an experienced radiologist from Poursina Hospital Imaging Center (Rasht, Iran). The radiographer and the radiologist worked together to verify the ROIs and make any necessary adjustments, ensuring consistency and accuracy in the data analysis. After making the required modifications, ADC was documented and sent for the final assessment and comparison with pathological findings. For 59 malignant lesions, one of the following interventional procedures was applied: core biopsy test, MRI-guided core biopsy excision biopsy, ultrasound-guided fine needle aspiration, and mastectomy specimen acquisition. On the other hand, for benign lesions without biopsy, regular ultrasound monitoring and scheduled screening were applied every six months for any possible changes in the size and shape of lesion.

To minimize the impact of motion artifacts on the diffusion-weighted imaging (DWI) sequence, several strategies were employed. Firstly, the patients were placed in a prone position with their arms above their heads to reduce movement during the imaging process. Additionally, the diffusion-weighted imaging sequence was acquired with a relatively short echo time (160 ms) to reduce the impact of motion on image quality.



Post-processing

Post-processing algorithms were also applied to correct for motion artifacts in the diffusion-weighted images. To manage ROI variability, several measures were taken. Firstly, ADC measurements were performed on multi-planar images (axial, sagittal, and coronal) to ensure that the ROI was accurately placed

on the lesion. Secondly, the ROIs were validated by an experienced radiologist to ensure that they were accurately placed on the lesion. Finally, the mean ADC was measured using a circular ROI to minimize the impact of ROI variability on the ADC measurements.

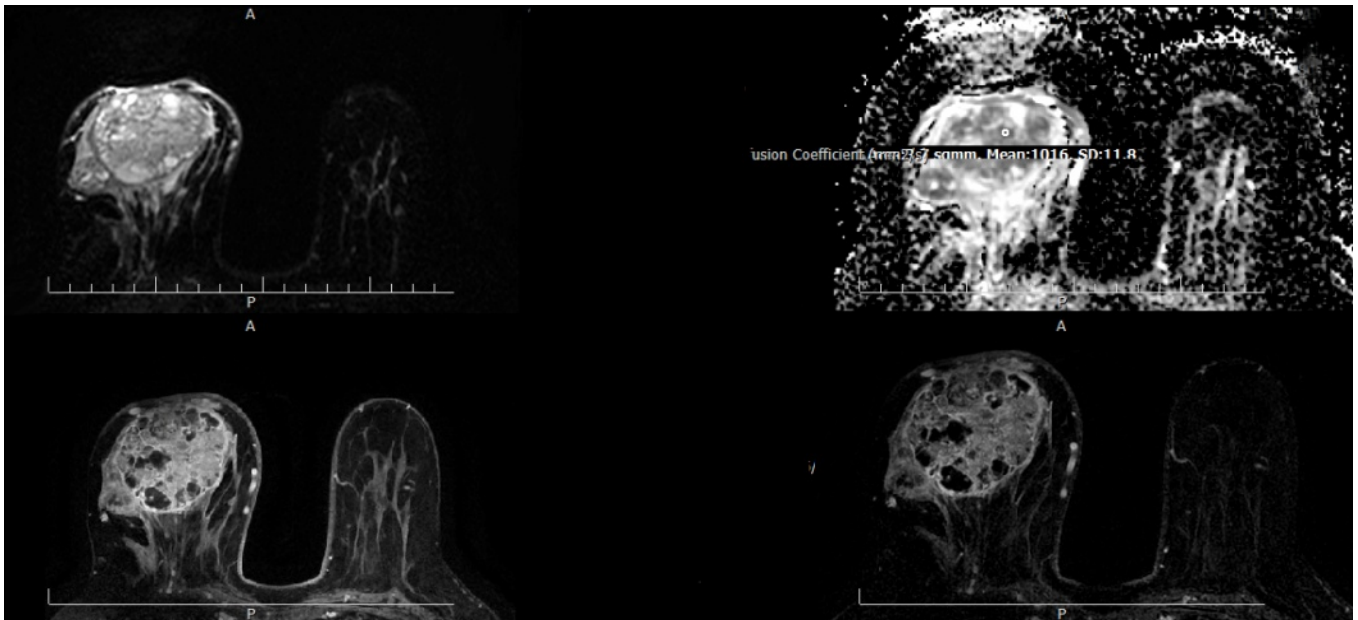


Figure 1. MRI Scans of Breast Lesions: The image displays a series of breast MRI scans organized in four panels. Top Left Panel: DWI-Top Right Panel: Apparent Diffusion Coefficient (ADC) map-Bottom Left Panel: dynamic image-Bottom Right Panel: subtract image. These images collectively assist in the evaluation and diagnosis of breast lesions.

In terms of b-value selection, a b-value of 1000 was chosen as it is a commonly used value in breast DWI studies and provides a good balance between sensitivity to diffusion restriction and image quality. This choice of b-value allows for the detection of restricted diffusion in malignant lesions while maintaining acceptable image quality.

By employing these strategies, the study aimed to minimize the impact of motion artifacts and ROI variability on the ADC measurements, thereby providing reliable and accurate results for differentiating between malignant and benign breast lesions.

The primary outcome of this study was the differentiation between malignant and benign breast lesions based on Apparent Diffusion Coefficient (ADC) values. The exposure of interest was the ADC value, which was measured using diffusion-weighted imaging (DWI). The predictors included patient age, lesion size, and BI-RADS score. Potential confounders included patient history of breast cancer, family history of breast cancer, and lesion location. Effect modifiers considered in this study were menopausal status and hormone receptor status. The diagnostic criteria for malignancy were based on a

histopathological examination of biopsy specimens. Lesions were considered malignant if they showed invasive cancer or ductal carcinoma in situ (DCIS) on histopathology. Benign lesions were defined as those with no evidence of malignancy on histopathology or imaging follow-up. The ADC values were categorized as follows: values below a certain threshold (to be determined) were considered indicative of malignancy, while values above the threshold were considered indicative of benignity.

It is important to note that this study did not obtain formal ethical approval from an institutional ethics committee due to its retrospective nature, which involved the analysis of existing medical records and imaging data. However, all patient data were anonymized to protect individual privacy, and informed consent was not required as per institutional guidelines for retrospective studies involving de-identified data. This approach ensured compliance with ethical considerations while facilitating valuable research into breast lesion characterization

Data analysis

Descriptive statistics were utilized to summarize the demographic and clinical characteristics of the



study participants. Continuous variables, such as age and ADC values, were expressed as means with standard deviations (SD). Categorical variables, including lesion type (benign or malignant), were reported as frequencies and percentages. This approach provided a clear overview of the population under study and facilitated comparisons between the groups. SPSS version 19.0 was employed to ensure a thorough examination of the results. Each subject was assigned a mean ADC value derived from independent data analyses, which allowed for categorization of subjects into benign and malignant cases. To compare the sizes of lesions, either the Mann-Whitney U test or Student's t-test was applied to determine the correlation between the minimum ADC value and lesion type.

The normality of the ADC data was assessed using the Shapiro-Wilk test. Since the data were not normally distributed, the Mann-Whitney U test was used to compare the minimum ADC values between benign and malignant lesions. The results showed a significant difference in minimum ADC values between the two groups ($P=0.000$).

To determine the optimal Apparent Diffusion Coefficient (ADC) cut-off value for differentiating between malignant and benign breast lesions, a Receiver Operating Characteristic (ROC) curve analysis was employed. The optimal ADC cut-off value was determined using the Youden Index, which

maximizes the sum of sensitivity and specificity, thereby identifying the best threshold for distinguishing between malignant and benign lesions. The ROC curve is a plot of the true positive rate (sensitivity) against the false positive rate (1-specificity) at different threshold settings, and it provides a comprehensive evaluation of the diagnostic accuracy of the ADC values. The area under the ROC curve (AUC) was calculated to quantify the overall diagnostic performance, with higher AUC values indicating better diagnostic accuracy. The optimal ADC cut-off value was identified by selecting the point on the ROC curve that maximized the sum of sensitivity and specificity, as determined by the Youden index. Statistical significance was set at $P < 0.05$.

RESULTS

A total of 93 patients with a mean weight of 70 ± 12 kg and a mean age of 43 ± 11 years who underwent breast MRI were included in this study, providing a comprehensive dataset for analysis. The dataset comprised 34 benign lesions (36.6%) and 59 malignant lesions (63.4%) (Figure 2), allowing for a detailed comparison between the two groups. Specifically, benign cases consisted of fibroadenoma, fibrosis, adenosis, inflammation, ductal papilloma, scar tissue, hyperplasia, and hematoma, representing a range of non-cancerous conditions.

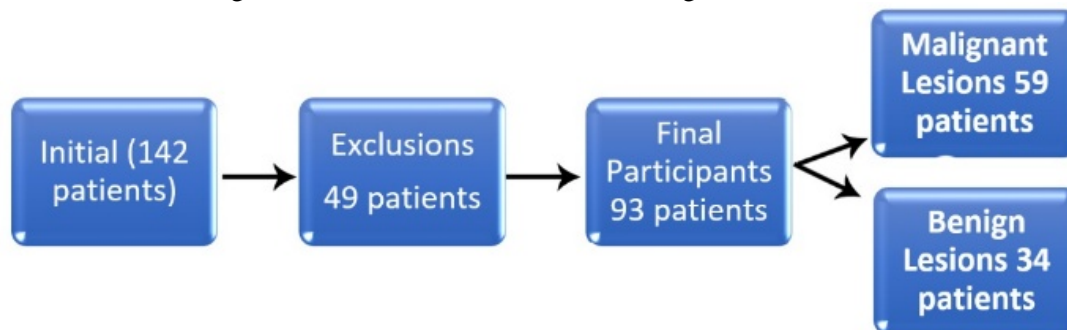


Figure 2. Flowchart illustrating the participant selection process for the study. The initial cohort consisted of 142 patients. Following the application of exclusion criteria, 49 patients were removed from the study, resulting in a final participant count of 93. Of these, 59 patients were diagnosed with malignant lesions, while 34 patients were diagnosed with benign lesions.

Malignant cases, on the other hand, included ductal carcinoma in situ, invasive lobular carcinoma, invasive ductal carcinoma, and lobular carcinoma in situ, encompassing various forms of cancer. The patients' ages ranged from 20 to 75 years, with weights between 50 and 105 kg, indicating a diverse population sample.

The findings revealed a significant correlation between the minimum ADC value and the lesion type, with a P -value < 0.001 (Table 1), indicating a strong association between these two variables. Notably, a lower minimum ADC value was associated with malignant lesions, suggesting that this metric could be useful for distinguishing between cancerous and

non-cancerous growths. The strength of this association highlights the potential value of ADC values in breast lesion diagnosis.

The area under the receiver operating characteristic (ROC) curve, which provides a measure of a diagnostic test's accuracy, showed a trend towards statistical significance, with a P -value of 0.000, indicating a reliable and robust result. The Receiver Operating Characteristic (ROC) curve for minimum ADC had an area of 0.949, indicating a high level of diagnostic accuracy. Furthermore, the cutoff value for differentiating malignant and benign lesions was set at 1.44×10^{-3} mm²/s, providing a clear threshold for diagnosis (Figure 3).



Table 1. Results of the Mann-Whitney U test, which compared the Minimum ADC Values between benign and malignant lesions, showing a significant difference ($P < 0.05$)

Lesion	N	Percent (%)	Mean ADC Value (or Median)
Benign	34	36.6	73.47
Malignant	59	63.4	63.4
Total	93		

Grouping variable: lesion. Mann-Whitney U test: 103.000; Wilcoxon W statistic: 1873.000; Z statistic: -7.180; Asymp. Sig. (two-tailed): 0.000.

Using this cutoff value, 58 malignant and 34 benign tumors were identified. The proposed scheme demonstrated a true positive rate of 55/58 (94.8%) and a true negative rate of 31/35 (88.6%). The accuracy of the proposed scheme was 92.5%, with 86 out of 93 cases correctly diagnosed. The false positive rate was 4/35 (11.4%), and the false negative rate was 3/58 (5.2%) (Table 2). The sensitivity, specificity, and accuracy were estimated as 93.2%, 91.2%, and 92.5%, respectively.

Table 2. Test Results

Test Results	With Disease	No Disease	Total
Test Positive	True Positive: 55	False Positive: 3	58
Test Negative	False Negative: 4	True Negative: 31	35
Totals	59	34	93

The results are based on ADC cut-off values for distinguishing between benign and malignant lesions

The results of the proposed scheme are presented in Table 3 and Table 4, providing a clear and concise summary of its performance. The scheme demonstrated high accuracy, sensitivity, and specificity in differentiating between malignant and benign breast lesions, suggesting its potential as a useful diagnostic tool. The scheme's ability to correctly classify a high proportion of cases, while minimizing false positives and false negatives, highlights its overall effectiveness and utility in a clinical setting.

This table summarizes the distribution of benign and malignant masses based on pathological findings and ADC results.

DISCUSSION

This study investigated the use of apparent diffusion coefficient (ADC) values in breast MRI for differentiating between malignant and benign lesions. The results showed that the minimum ADC value was significantly lower in malignant lesions compared to

that in benign lesions ($P < 0.001$), showing that a lower minimum ADC value is indicative of a malignant lesion.

The study also found that the area under the curve (AUC) of the receiver operating characteristic (ROC) analysis for the minimum ADC value was 0.949, indicating a high level of diagnostic accuracy. The selected cutoff value of 1.44×10^{-3} mm²/s showed a sensitivity of 93.2% and specificity of 91.2%, which is comparable to other studies that have reported similar diagnostic accuracy for ADC values in breast MRI.

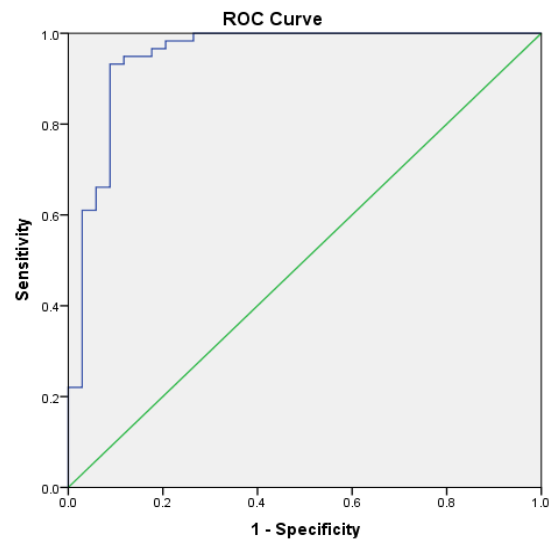


Figure 3. ROC Curve for ADC Cut-Off in Breast Lesion Classification: The ROC curve illustrates the optimal Apparent Diffusion Coefficient (ADC) cut-off value for differentiating malignant from benign breast lesions. The optimal point was determined using the Youden index, maximizing the sum of sensitivity and specificity. Statistical significance was set at $P < 0.05$, with the area under the curve (AUC) utilized to assess diagnostic accuracy.

Table 3. Area Under Curve and Diagnostic Performance.

Test Result Variable	Area (AUC)	95% Confidence Interval	Sensitivity	Specificity
ADC	0.949	(0.895, 1.000)	93.2%	91.2%

AUC under the nonparametric assumption. Null hypothesis (true area = 0.5).

Table 4. Summary of ADC Results Based on Cut-off Value and Pathological Findings

Variable	Benign (N)	Malignant (N)	Total (N)
Type of Mass			
Malignant	4	55	59
Benign	31	3	34
Totals	35	58	93

N: Number of cases, based on ADC results and pathological findings.



The results of this study are consistent with a large body of literature emphasizing the diagnostic utility of ADC in breast MRI. A meta-analysis by Cakir *et al.*, which included 13,847 breast lesions, reported that malignant lesions had a mean ADC of 1.03×10^{-3} mm²/s, while benign lesions had a mean of 1.5×10^{-3} mm²/s. This supports our findings and suggests that an ADC threshold of 1.00×10^{-3} mm²/s may be effective in distinguishing between malignant and benign lesions in different populations and imaging protocols.¹⁹

In another systematic review, Dkhar *et al.* highlighted the correlation between ADC values and various molecular prognostic markers in breast cancer, including estrogen receptor (ER) and progesterone receptor (PgR) status. They found that ER-positive and PgR-positive tumors had significantly lower ADC values than their negative counterparts, suggesting that ADC may reflect tumor biology beyond the simple differentiation between benign and malignant lesions.²⁰ This relationship suggests that ADC values may also serve as a non-invasive biomarker for assessing tumor aggressiveness.

The effect of imaging parameters on ADC is also well documented in the literature. A meta-analysis by Zhang *et al.* found significant variations in ADC thresholds based on different b-values used during imaging, highlighting the need for standardization in clinical practice.²¹ Their findings suggest that optimal b-values may improve the differentiation capabilities of DWI, thus influencing the diagnostic performance metrics reported in various studies.

Similar to many studies in this field, we used minimum ADC to evaluate its role in distinguishing malignant from benign breast lesions. This study highlighted the importance of DWI and ADC maps as advanced imaging modalities that can be applied to intensify MRI specificity in detecting breast lesions (accuracy and specificity >90%). This finding is similar to that reported by Abdulghaffar and Tag-Aldee.²² In contrast, Cabuk *et al.* reported a specificity of 85%, an accuracy of 87%, and a sensitivity of 91%, which seems to be related to the number of patients.²³ Min *et al.*, also reported a sensitivity of 82.8% and specificity of 90.0%¹⁴. In addition, Rinaldi *et al.* reported a sensitivity of 82.8% and 90.0% specificity²⁴. The study's higher sensitivity (93.2%) and specificity (91.2%) compared to previous studies may be due to optimal imaging parameters, careful ROI analysis, or differences in study population and methodology. Additionally, the small sample size may have contributed to the results, but this also raises concerns about generalizability.

We found that malignant tumors on breast MRI were characterized by a low ADC. In contrast, benign

lesions are characterized by higher ADC values. In this regard, Wahab *et al.* showed that ADC is higher in benign lesions than in malignant lesions.⁸ Similarly, Cabuk *et al.* reported lower mean ADCs for malignant lesions and higher values for benign lesions.²³ Park *et al.*, also showed significantly lower ADCs for invasive ductal carcinoma and DCIS, compared to benign lesions and normal fibro glandular tissues.²⁵

In this study, lesions with ADCs $\leq 1.44 \times 10^{-3}$ mm²/s were identified as malignant, while those with ADCs above the cut-off value were considered benign. In this regard, Wahab *et al.* reported a cut-off point of 1.02×10^{-3} mm²/s for differentiation.⁸ Min *et al.*, reported an ADC threshold of 1.23×10^{-3} mm²/s at b-value of 800 s/mm².¹⁴ In addition, in a study by Mori *et al.*, a minimum ADC below 1.1×10^{-3} mm²/s was indicative of invasive carcinoma in DCIS cases, diagnosed through biopsy.²⁶ Abdulghaffar and Tag-Aldeen reported a cut-off point of 1.25×10^{-3} mm²/s.²²

In this study, for practical and clinical applications, the minimum ADC values were obtained directly from ADC images produced by the MRI device. ROI was then plotted on the lesion site by using the minimum ADC value. In total, three out of 58 cases were identified as false positives, while four out of 35 cases were identified as false negatives. The high true positive rate and true negative rate suggest that the proposed scheme is effective in differentiating between malignant and benign breast lesions. However, the small size of some lesions may have affected the ADC measurements, potentially leading to misclassification. Additionally, the presence of cysts containing hemoglobin or fibrosis may also have affected the ADC measurements, which could have contributed to the false positives and false negatives.

The implications of these findings are significant for clinical practice, particularly in regions with high breast cancer prevalence such as Iran. The ability to accurately differentiate between benign and malignant lesions using ADC values can facilitate earlier diagnosis and treatment interventions, potentially reducing unnecessary biopsies and associated patient anxiety. Incorporating DWI into routine clinical practice could improve diagnostic accuracy and help guide management strategies for patients presenting with suspicious breast lesions. The high diagnostic performance metrics observed in this study suggest that radiologists should consider integrating DWI into their assessment protocols to enhance specificity in detecting breast cancer.

Limitations and Recommendations

The study has limitations such as a relatively



small sample size of 93 cases and the exclusion of small lesions. These limitations may impact the generalizability and robustness of the findings. The study also relies on radiologists' expertise in manually drawing regions of interest (ROIs) on ADC images, which may introduce variability in the results.

Future studies should aim for a larger and more diverse sample size, consider the inclusion of small lesions, and explore automated techniques for ADC calculations and ROI analysis to reduce variability.

One of the major problems of researchers with ADC maps is the optimal detection of lesions, especially when they are small in size. We recommend searching for a reliable technique, such as measurement of the average amount of ADC reduction in the involved breast, instead of concentrating on the lesion alone.

CONCLUSION

In cases where the dynamic breast test shows false positive results, ADC can be used to screen masses and develop useful quantifiable indices. These indices can predict the outcomes and determine the treatment course without the need for invasive biopsy or dynamic MRI (with injection of a contrast medium),

REFERENCES

1. Dolatkah R, Hosseinalifam M, Sanaat Z, Dolatkah N, Dastgiri S. Molecular Epidemiology of Breast Cancer in Iran: A Review Article. *Journal of Obstetrics, Gynecology and Cancer Research*. 2023;8(5):422-30.
2. Roshandel G, Ghanbari-Motlagh A, Partovipour E, Salavati F, Hasanpour-Heidari S, Mohammadi G, et al. Cancer incidence in Iran in 2014: results of the Iranian National Population-based Cancer Registry. *Cancer epidemiology*. 2019;61:50-8.
3. Vostakolaei FA, Broeders MJ, Mousavi SM, Kiemeny LA, Verbeek AL. The effect of demographic and lifestyle changes on the burden of breast cancer in Iranian women: a projection to 2030. *The Breast*. 2013;22(3):277-81.
4. Chen X, Li W-l, Zhang Y-l, Wu Q, Guo Y-m, Bai Z-l. Meta-analysis of quantitative diffusion-weighted MR imaging in the differential diagnosis of breast lesions. *BMC cancer*. 2010;10:1-11.
5. Aberle DR, Chiles C, Gatsonis C, Hillman BJ, Johnson CD, McClennan BL, et al. Imaging and cancer: research strategy of the American College of Radiology Imaging Network. *Radiology*. 2005;235(3):741-51.
6. Leung JW. Screening mammography reduces morbidity of breast cancer treatment. *AJR American journal of roentgenology*. 2005;184(5):1508-9.
7. Gundry KR. Breast Ultrasound: Indications and Findings. *Clinical obstetrics and gynecology*. 2016;59(2):380-93.
8. Wahab MAK, Kareem HA, Hassan EE. The utility of diffusion weighted MRI and apparent diffusion

coefficient in characterization of breast masses. The Egyptian Journal of Radiology and Nuclear Medicine. 2015;46(4):1257-65.

9. Blackledge MD, Leach MO, Collins DJ, Koh DM. Computed diffusion-weighted MR imaging may improve tumor detection. *Radiology*. 2011;261(2):573-81.
10. Jagannathan NR. Breast MR. *NMR in biomedicine*. 2009;22(1):1-2.
11. Kul S, Cansu A, Alhan E, Dinc H, Reis A, Can G. Contrast-enhanced MR angiography of the breast: Evaluation of ipsilateral increased vascularity and adjacent vessel sign in the characterization of breast lesions. *AJR American journal of roentgenology*. 2010;195(5):1250-4.
12. Cai H, Liu L, Peng Y, Wu Y, Li L. Diagnostic assessment by dynamic contrast-enhanced and diffusion-weighted magnetic resonance in differentiation of breast lesions under different imaging protocols. *BMC cancer*. 2014;14:366.
13. Iima M, Le Bihan D, Okumura R, Okada T, Fujimoto K, Kanao S, et al. Apparent diffusion coefficient as an MR imaging biomarker of low-risk ductal carcinoma in situ: a pilot study. *Radiology*. 2011;260(2):364-72.
14. Min Q, Shao K, Zhai L, Liu W, Zhu C, Yuan L, Yang J. Differential diagnosis of benign and malignant breast masses using diffusion-weighted magnetic resonance imaging. *World journal of surgical oncology*. 2015;13:32.
15. Chen X, Li WL, Zhang YL, Wu Q, Guo YM, Bai ZL. Meta-analysis of quantitative diffusion-

FUNDING

The authors received no specific funding for this research.

CONFLICT OF INTEREST

The authors declare no conflict of interest.

ACKNOWLEDGEMENTS

None.

DATA AVAILABILITY

All data relevant to the study are included in the article.



- weighted MR imaging in the differential diagnosis of breast lesions. *BMC cancer*. 2010;10:693.
16. Guatelli CS, Bitencourt AGV, Osorio C, Graziano L, de Castro AA, de Souza JA, et al. Can diffusion-weighted imaging add information in the evaluation of breast lesions considered suspicious on magnetic resonance imaging? *Radiologia brasileira*. 2017;50(5):291-8.
 17. Partridge SC, DeMartini WB, Kurland BF, Eby PR, White SW, Lehman CD. Quantitative diffusion-weighted imaging as an adjunct to conventional breast MRI for improved positive predictive value. *AJR American journal of roentgenology*. 2009;193(6):1716-22.
 18. Yabuuchi H, Matsuo Y, Sunami S, Kamitani T, Kawanami S, Setoguchi T, et al. Detection of non-palpable breast cancer in asymptomatic women by using unenhanced diffusion-weighted and T2-weighted MR imaging: comparison with mammography and dynamic contrast-enhanced MR imaging. *European radiology*. 2011;21(1):11-7.
 19. Surov A, Meyer HJ, Wienke A. Can apparent diffusion coefficient (ADC) distinguish breast cancer from benign breast findings? A meta-analysis based on 13 847 lesions. *BMC cancer*. 2019;19:1-14.
 20. Iima M, Kataoka M, Honda M, Le Bihan D. Diffusion-Weighted MRI for the Assessment of Molecular Prognostic Biomarkers in Breast Cancer. *Korean Journal of Radiology*. 2024;25(7):623.
 21. Dkhar W, Kadavigere R, Sukumar S, Pradhan A, Sharath S. Diagnostic Performances of ADC Value in Diffusion-Weighted MR Imaging for Differential Diagnosis of Breast Lesions in 1.5 T: A Systematic Review and Meta-analysis. *Journal of Medical and Biological Engineering*. 2023;43(5):497-507.
 22. Abdulghaffar W, Tag-Aldeen MM. Role of diffusion-weighted imaging (DWI) and apparent diffusion coefficient (ADC) in differentiating between benign and malignant breast lesions. *Egypt J Radiol Nucl Med*. 2013;44(4):945-51.
 23. Cabuk G, Nass Duce M, Ozgur A, Apaydin FD, Polat A, Orekici G. The diagnostic value of diffusion-weighted imaging and the apparent diffusion coefficient values in the differentiation of benign and malignant breast lesions. *Journal of medical imaging and radiation oncology*. 2015;59(2):141-8.
 24. Rinaldi P, Giuliani M, Belli P, Costantini M, Romani M, Distefano D, et al. DWI in breast MRI: role of ADC value to determine diagnosis between recurrent tumor and surgical scar in operated patients. *European journal of radiology*. 2010;75(2):e114-23.
 25. Park MJ, Cha ES, Kang BJ, Ihn YK, Baik JH. The role of diffusion-weighted imaging and the apparent diffusion coefficient (ADC) values for breast tumors. *Korean journal of radiology*. 2007;8(5):390-6.
 26. Mori N, Ota H, Mugikura S, Takasawa C, Tominaga J, Ishida T, et al. Detection of invasive components in cases of breast ductal carcinoma in situ on biopsy by using apparent diffusion coefficient MR parameters. *European radiology*. 2013;23(10):2705-12.

How to Cite This Article

Souri Z, Kiani P. The Role of Apparent Diffusion Coefficient (ADC) in Differentiating Between Benign and Malignant Breast Lesions in a Sample of Iranian Women. *Arch Breast Cancer*. 2025; 12(1):105-13. Available from: <https://www.archbreastcancer.com/index.php/abc/article/view/1050>